

Retrograde Tracheal Intubation

Youn Woo Lee, Young Seok Lee and Jong Rae Kim

Endotracheal intubation is especially necessary for ventilatory care in Positive End Expiratory Pressure (PEEP) therapy. In many circumstances it is difficult to obtain an adequate view of the vocal cords, and thus various technics have been used for airway management. Retrograde tracheal intubation was performed on a 73-year old male patient suffering from postoperative noncardiogenic pulmonary edema who needed ventilatory PEEP therapy. This procedure was successful, and a tracheostomy was not needed. Following improvement he was discharged without complication.

Key Words: Retrograde tracheal intubation, PEEP, tracheostomy

CASE REPORT

A 73-year old male patient who was scheduled for a cholecystectomy was transferred to Yong Dong Severance Hospital from a local clinic due to a difficult intubation. His chief complaint was right upper abdominal pain and jaundice for four days. He had had hypertensive symptoms for ten years and had been treated with medication intermittently.

His statistics and vital signs included body weight 68 Kg, height 160 cm, blood pressure 180/120 mmHg, pulse rate 103/min., respiration rate 20/min., and body temperature 38.3°C. On physical examination direct and rebound tenderness was noted in the right upper quadrant of the abdomen and Murphy's sign was positive. Coarse breathing sounds and S2 heart sounds were auscultated.

The laboratory findings were Hgb 13.5g%, Hct 40.6%, WBC 21300, urine specific gravity 1.025, urinary glucose >500 mg%, urinary protein -, blood glucose 283 mg%, and serum electrolytes normal. Blood glucose decreased to 116 mg% after a regular

insulin 5IU subcutaneous injection. Q-wave and ST elevation were found in ECG lead V₁₋₃. The chest P-A and cervical vertebrae A-P and lateral X-ray findings were normal.

He was premedicated with 3 mg of lorazepam and then taken to surgery where the left radial artery was cannulated for BP monitoring and arterial blood gas analysis and ECG lead II monitoring was initiated. Following IV administration of 200 mg pentothal, 10 mg diazepam and 75 mg succinylcholine, orotracheal intubation was attempted, but failed. The laryngopharyngeal anatomy could not be differentiated due to severe edema and firmly attached blood clots. In spite of external pressure to the cricoid ring, neither the vocal cords nor the epiglottis were exposed. After 10 minutes later, his respiration returned to normal and while lying in the right lateral decubitus position, epidural anesthesia was performed. The cholecystectomy was completed in one hour and twenty five minutes.

In the recovery room chest X-ray and arterial blood gas analysis findings were normal. However, one day later, the patient seemed mildly cyanotic and irritable, and on chest auscultation moist rales were heard in the entire lung field. X-ray and arterial blood gas findings indicated that ventilatory PEEP therapy was necessary. He was referred to the anesthesiology department for respiratory care. When transferred to ICU he and his family refused a tracheostomy, so a retrograde tracheal intubation was attempted.

Received March 26, 1987

Accepted June 8, 1987

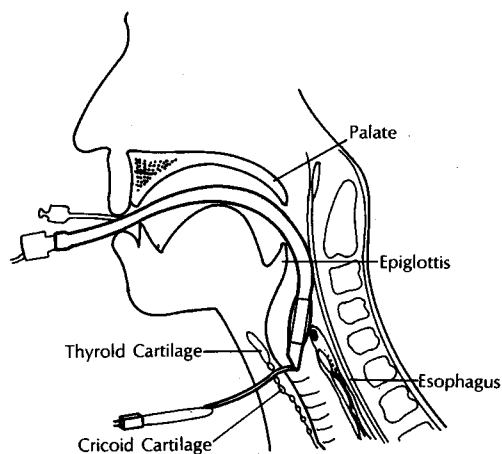
Department of Anesthesiology, Yongdong Severance Hospital, Yonsei University College of Medicine, Seoul, Korea

Address reprint requests to Dr. Y-W Lee, Department of Anesthesiology, Yonsei University College of Medicine, Yongdong Severance Hospital Yongdong P.O. Box 1217, Seoul, Korea

Table 1. Arterial blood gas data and chest X-ray findings

	pH	PaO ₂ (mmHg)	PaCO ₂ (mmHg)	HCO ₃ (mEq/L)	BE (mEq/L)	FiO ₂ (PEEP: cmH ₂ O)	Chest X-ray
at R.R.	7.354	164.3	37.6	20.3	-5.7	5L/min.	no specific findings
POD #1	7.401	60.9	29.6	17.8	-5.1	5L/min.	bilateral consolidation
POD #2	7.362	89.5	24.2	13.3	-9.5	0.4	non cardiogenic pulmonary edema
	7.438	118.1	25.6	16.8	-4.7	0.4 (7.5)	
POD #3	7.398	134.5	37.3	21.9	-2.1	0.3	Slight improved pulmonary edema
POD #4	7.401	116.5	40.8	24.5	-0.2	0.3 (5)	
POD #5	7.396	174.7	39.8	23.7	-0.5	0.3	cleared lung
POD #6	7.425	119.8	35.3	22.5	-0.8	0.2	
	7.401	113.0	38.4	23.2	-0.7	3L/min	extubated, normalized X-ray

R.R.: recovery room POD: post operative days

**Fig. 1.** Position of catheter and endotracheal tube.

While palpating the cricothyroid membrane, 1% lidocaine was infiltrated into the skin overlying the membrane, and a 16G Tuohy needle was inserted unto the larynx through the membrane. With the bevel of the needle facing upward, a 22G polyethylene IV angiocatheter was passed through the needle and into the oral cavity. Following placement of the catheter the needle was withdrawn, and the catheter was used as a guide for oral intubation. During the patient's deep inspiration both ends of the catheter were stretched and a Portex endotracheal tube (ID 8 mm) was intubated. When the tip of the tracheal tube passed into the larynx, the catheter was loosened to allow advancement of the tracheal tube into the trachea.

The catheter was then withdrawn through the mouth to prevent contamination of the superficial neck tissue (Fig. 1).

The results of the respiratory PEEP therapy are summarized in Table 1. This patient was discharged after improvement on POD #13 without complication.

DISCUSSION

Intubation of the trachea is considered a simple procedure for anesthesiologists, and is usually performed in general anesthetic management and respiratory care, but some intubations are difficult. The initial step in successful management is through assessment of the airway, to include micrognathia, prognathism or protrusion of the teeth. It is not always possible to anticipate when endotracheal intubation will be difficult (Stehling 1986). In this case there were no indications on physical examination and cervical A-P and lateral X-ray films.

Common causes of failure in tracheal intubation include inadequate muscle relaxation; insufficient depth of general anesthesia; poor position of the head; obscuration of the visual field by the tongue; and inadequate anatomic knowledge (Dripps *et al.* 1982).

When exposure of the vocal cords is difficult due to anatomical-congenital or acquired-causes, many procedures have been used (Salem *et al.* 1976). Simple procedures include the use of anatomic landmarks such as the epiglottis or the arytenoid cartilages; facilitation of the visualization by external pressure on the cricoid ring; the use of a stylet; and blind nasal intubation, where as special procedures involve the use of a fiberoptic endoscope and retrograde tracheal

intubation.

Fiberoptic endoscopy is a protracted technique which requires considerable skill and practice. It should not be employed in children with a suspected epiglottitis which can precipitate total airway obstruction or in patients where the presence of blood and secretions obscures the lens of the instrument. The advantage of retrograde intubation is simplicity, it permits fast and safe intubation even by the inexperienced. However, it is limited by the fact that it requires a conscious patient and is not suitable for patients with respiratory obstructions. If none of the above procedures are available, a tracheostomy should be performed for airway management, but the operative procedure of a tracheostomy is difficult and dangerous even under optimal conditions (Shapiro *et al.* 1985).

In 1960 Butler and Cirillo described a method in which the proximal end of a catheter is introduced in a retrograde fashion through a tracheostomy into the pharynx, the distal end passed into the trachea, and the catheter then used as a guide for the orotracheal tube. In subsequent reports, Waters (1963) and Powell and Ozdil (1967) modified the technique by using a large bore needle through the cricothyroid membrane as an avenue for passing a catheter into the oropharynx.

Bourke and Levesque (1974) further modified the technique by passing the guide through the side hole of the endotracheal tube in order to farther advance the tube into the trachea. Roberts (1981) reported the use of a Swan-Ganz introducer wire as a guide. Tobias (1983) suggested the use of a fiberoptic laryngoscope in conjunction with the placement of a retrograde wire. In this way, the fiberoptic tip can be advanced into the trachea before the guide wire is withdrawn thereby avoiding possible displacement of the tip of the endotracheal tube. King (1985) suggested the use of a well lubricated ordinary suction catheter or a nasogastric tube for the same purpose and called this technique "translaryngeal guided intubation".

In this study a retrograde intubation using a 16G

Tuohy needle and a 22G polyethylene IV angiocatheter was performed. When stretched, this catheter had enough strength to guide and enough flexibility to advance the endotracheal tube farther into the trachea. Thus a suction catheter or a nasogastric tube were not needed as guides, and intubation succeeded efficaciously without displacement. The patient was comfortable during all of these procedures which successfully alleviated his postoperative lung problem with ventilatory PEEP therapy.

REFERENCES

- Bourke D, Devesque PR: Modification of retrograde guide for endotracheal intubation. *Anesth Analg* 53:1013-1014, 1974
- Butler FS, Cirillo AA: Retrograde tracheal intubation. *Anesth Analg* 39:333-338, 1960
- Dripps RD, Eckenhoff JE, Vandam LD: *Introduction to anesthesia: Intubation of the trachea*. 6th ed. W.B. Saunders Company, 1982, 181-195
- King HK: Translaryngeal guided intubation. *Anesth Analg* 64:650-651, 1985
- Powell WF, Ozdil T: A translaryngeal guide for tracheal intubation. *Anesth Analg* 46:231-234, 1967
- Oberts KW: New use for Swan-Ganz introducer wire. *Anesth Analg* 60:67, 1981
- Salem MR, Mathrubhutham M, Bennett EJ: Current concepts ; difficult intubation. *N Engl J Med* 295:879-881, 1976
- Shapiro BA, Harrison RA, Kacmarek RM, Cane RD: *Clinical application of respiratory care: The artificial airway*. 3rd ed. Year Book Medical Publishers, Inc. 1985, 227-230
- Stehling LC: *Fiberoptic endoscopic techniques for the difficult endo-tracheal intubation*. ASA annual refresher course lectures 1986, 234
- Tobias R: Increased success with retrograde guide for endotracheal intubation. *Anesth Analg* 62:366-367, 1983
- Waters DJ: Guided blind endotracheal intubation. *Anaesthesia* 18:158-162, 1963