

On the Effect of Morphine Hydrochloride on the Mesenteric Mast cells of Albino Rats

Man Soo Park, Ho Suck Kang, Soo Yun Pak and Kum Duck Choi

*Department of Anatomy
Yonsei University College of Medicine, Seoul, Korea*

(Received for Publication; 20 May 1970)

ABSTRACT

Histological studies were carried out on the degranulation of mesenteric mast cells of white rats caused by injections of morphine and nalorphine hydrochloride intravenously and the following conclusions were obtained.

1. By the injection of morphine hydrochloride fairly significant degranulation of the mesenteric mast cell was observed.

2. In various experimental doses of morphine hydrochloride the cytological change of the degranulation was not proportional to the doses of it in cases given more than 12 mg./kg. of body weight.

3. The degranulating effect of the mesenteric mast cell by the injection of morphine hydrochloride was significantly inhibited by an adrenalectomy.

INTRODUCTION

It is well known that histamine is liberated by histamine liberators, such as compound 48/80, stilbamidine, d-tubocurarine and protamine sulfate etc. Its liberation is associated with a degranulation of the mast cells. It has been shown that opium alkaloids and the morphine derivative, apomorphine, also have to be added

to the list of histamine liberators.

Lee and Pak (1969) reported a significant degranulation of the mesenteric mast cells of the albino rats following the intravenous injection of morphine hydrochloride and meperidine hydrochloride.

This study was made to observe cytological changes of the mesenteric mast cells of the albino rats or degranulating patterns of metachromatic granules of the same cells by an injection of morphine hydrochloride which was given in various doses and cytological changes of the same cells at several intervals after a single injection of morphine hydrochloride. In this study the cytological effect of the mesenteric mast cells by an injection of morphine hydrochloride was examined when nalorphine hydrochloride, known as an antagonist of morphine hydrochloride, was given previously. Additionally the inhibiting effect of the cytological change of the mesenteric mast cells by an injection of morphine hydrochloride in adrenalectomized rats was studied.

MATERIALS AND METHODS

Experimental animals used in this study were 78 healthy mature male rats of Sprague-Dawley strain weighing about 200 gm. For intravenous injection of morphine hydrochloride and other

drugs, tail veins were used. The experimental groups were divided as follows.

A. The groups injected with various doses of morphine hydrochloride:

a. The group given 6 mg./kg. of morphine hydrochloride in 1 cc. of physiological saline solution intravenously

b. The group given 12 mg./kg. of morphine hydrochloride in 1 cc. of physiological saline solution intravenously

c. The group given 18 mg./kg. of morphine hydrochloride in 1 cc. of physiological saline solution intravenously

d. The group given 24 mg./kg. of morphine hydrochloride in 1 cc. of physiological saline solution intravenously

e. The group given 1 cc. of normal saline solution intravenously for the control.

The experimental rats were sacrificed by an occipital blow 4 hours after each injection.

B. The groups observed at several intervals after single intravenous injection of 12 mg./kg. of morphine hydrochloride:

a. The group of 30 minutes after the injection

b. The group of 1 hour after the injection

c. The group of 2 hours after the injection

d. The group of 3 hours after the injection

e. The group of 4 hours after the injection

f. The group of 5 hours after the injection

g. The group of 6 hours after the injection

The experimental rats were sacrificed by an occipital blow at different intervals after each injection of morphine hydrochloride.

C. The groups injected with nalorphine hydrochloride and followed by morphine hydrochloride intravenously:

a. The group given 12 mg./kg. of nalorphine hydrochloride in 1 cc. of physiological saline solution.

b. The group given 12 mg./kg. of morphine hydrochloride in 1 cc. of physiological saline

solution 10 minutes after previous injection of nalorphine hydrochloride in 1 cc. of physiological saline solution.

c. The group given 1 cc. of physiological saline solution 10 minutes after a previous 12 mg./kg. of nalorphine hydrochloride and followed by 1 cc. of physiological saline solution.

d. The group given 12 mg./kg. of morphine hydrochloride in 1 cc. of physiological saline solution.

The experimental rats were sacrificed and prepared for histological slides as in the A group.

D. The adrenalectomized group:

a. The group given 12 mg./kg. of morphine hydrochloride in 1 cc. of physiological saline solution intravenously.

b. The group given 1 cc. of physiological saline solution intravenously as the control.

The adrenalectomy and postoperative care of the rat were performed following the procedures used by Lee and Pak (1969). For intravenous injection the tail veins were used. The rats were sacrificed by an occipital blow and absolute methanol was infused into the peritoneal cavity through a small incision of the anterior median abdominal wall and then fixed for 20 minutes in situ in order to reduce the direct mechanical injury to the mesenteric mast cells. A few pieces of the mesentery obtained gently for flat histological preparation were stained with Pugh solution, which was the method used by Leblanc and Rosenberg (1957), for 3 minutes. The tissue was then prepared for permanent slides through ordinary histological procedures.

For the degrees of degranulation of mast cells 4 grades of cytological changes were adopted by the criteria of An (1964) as follow: 1. the normal type of mast cell which displays mostly a round form without any evident dispersion of metachromatic granules from the cell. However,

Table 1. Results of degranulation of mesenteric mast cells in the groups given various doses of morphine HCl

Group	Nos. of rats	Nos. of mast cells	Normal type(%)	Grade I type(%)	Grade II type(%)	Grade III type(%)
a. (6 mg./kg.)	4	7,412	91.7±0.32	8.2±0.32	0	0
b. (12 mg./kg.)	5	6,912	84.3±0.43	15.6±0.43	0.03±0.02	0
c. (18 mg./kg.)	5	6,222	90.2±0.37	9.7±0.37	0	0
d. (24 mg./kg.)	4	10,647	88.3±0.31	11.6±0.31	0.03±0.01	0.01±0.01
e. (1ml. of normal saline sol.)	5	32,261	97.8±0.08	2.2±0.08	0	0

M±Standard error (%)

Table 2. Results of degranulation of mesenteric mast cells in the groups observed at several intervals after single injection of 12 mg./kg. morphine HCl

Group	Nos. of rats	Nos. of mast cells	Normal type(%)	Grade I type(%)	Grade II type(%)	Grade III type(%)
a. (0.5 hr)	5	13,592	90.3±0.25	9.7±0.25	0.01±0.01	0
b. (1 hr)	5	6,425	91.1±0.35	8.8±0.35	0	0
c. (2 hr)	5	10,112	85.7±0.34	14.2±0.34	0.08±0.03	0.06±0.02
d. (3 hr)	5	19,397	83.9±0.13	16.0±0.26	0.07±0.02	0
e. (4 hr)	5	6,912	84.3±0.43	15.6±0.43	0.03±0.02	0
f. (5 hr)	5	15,359	89.9±0.24	10.0±0.24	0	0
g. (6 hr)	5	9,792	94.9±0.22	5.0±0.22	0	0

M(%)±Standard error (%)

the mast cell showing one or two extracellular metachromatic granules in the vicinity of it, was counted as the normal type (Fig. 1), 2. the grade I type or slight degranulation of a mast cell showing a few to several metachromatic granules in the vicinity of it (Fig. 2), 3. the grade II type or moderate degranulation of a mast cell whose contour is clear (Fig. 3), and 4. the grade III type, severe degranulation or disruption of a mast cell in which the clear contour of the cell is hard to identify due to severe degranulation or a disruption of the mast cell (Fig. 4).

RESULTS

A. The groups injected with a different dose of morphine hydrochloride:

In these groups slightly degranulated mast cells of the group given 12 mg./kg. of a body weight were the greatest incidence of 15.6±0.43

% and it was compared with the incidence of 2.2±0.08% occurred in the control. It was evident that the degree of the degranulation in the mesenteric mast cell was parallel to the dosage of morphine hydrochloride as shown in Table 1.

B. The groups observed at several intervals after single intravenous injection of 12 mg./kg. of morphine hydrochloride:

Among the cytological changes of these groups slightly degranulated mast cells in the groups of 3 and 4 hours after the injection were, as shown in Table 2, the highest incidence of 16.0±0.26% and 15.6±0.43% respectively.

C. The groups injected with nalorphine hydrochloride and followed by morphine hydrochloride intravenously:

In the group given nalorphine hydrochloride alone, a cytological change or light degranulation of the mesenteric mast cells was observed in

Table 3. Results of mesenteric mast cells in the groups given nalorphine HCl and Morphine HCl intravenously

Group	Nors. of rats	Nos. of mast cells	Normal type(%)	Grade I type(%)	Grade II type(%)	Grade III type(%)
a.	5	9,874	93.3±0.25	6.7±0.25	0.03±0.01	0.19±0.04
b.	5	12,929	90.2±0.26	9.8±0.26	0	0
c.	5	14,125	89.3±0.26	10.5±0.26	0	0
d.	5	6,912	84.3±0.43	15.6±0.43	0.03±0.02	0

M(%)±Standard error(%)

Table 4. Results of degranulation of mesenteric mast cells in the adrenalectomized group

Group	Nos. of rats	Nos. of mast cells	Normal type(%)	Grade I type(%)	Grade II type(%)	Grade III type(%)
a.	6	14,722	91.9±0.32	7.8±0.21	0.21±0.03	0.06±0.01
b.	4	23,315	92.2±0.17	7.7±0.17	0.09±0.02	0
c.	5	6,912	84.3±0.43	15.6±0.43	0.03±0.02	0

M(%)±Standard error(%)

the incidence of $6.7 \pm 0.25\%$, which was classified as the grade I type or a slightly degranulated mast cell. Comparing the result of the group given nalorphine hydrochloride associated with morphine hydrochloride to that of the group of nalorphine hydrochloride associated with physiological saline solution, the slightly degranulated mast cells were in the incidence of $9.8 \pm 0.26\%$ and $10.5 \pm 0.26\%$ respectively as shown Table 3. By the comparison of the latter results, it is easily deduced that the degranulating effect of morphine hydrochloride upon the mesenteric mast cells was fairly well inhibited by a previous injection of nalorphine hydrochloride.

D. The adrenalectomized group:

In the adrenalectomized group given morphine hydrochloride and the adrenalectomized group given physiological saline solution alone as the control of the former, slightly degranulated mast cells occurred in the incidence of $7.8 \pm 0.21\%$ and $7.7 \pm 0.17\%$ respectively as shown in Table 4. The degranulating effect of morphine hydrochloride upon the mesenteric mast cell was clearly inhibited by an adrenalectomy.

DISCUSSION

The degranulation of metachromatic granules of tissue mast cells by the injection of morphine was studied by Bhattacharya and Lewi (1956) and postulated that the peritoneal mast cells of the rat show much more degranulation than do the subcutaneous mast cells after intraperitoneal injection of morphine. However, Parratt and West (1957) showed that intraperitoneal injection of morphine has but little damaging effect upon tissue mast cells and releases correspondingly little histamine in the rat. Lee and Pak (1969) studied that fairly significant degranulation of the rats mesenteric mast cell occurred by the injection of morphine hydrochloride, which was probably associated with the concomitant liberation of tissue histamine derived from its source.

In this study the authors confirmed the degranulating effect of the rat's mesenteric mast cell by morphine hydrochloride given intravenously. The cytological change of the degranulation of the mesenteric mast cell 3 or 4 hours

after a single intravenous injection of 12 mg./kg. of morphine hydrochloride was the greatest one which was shown in the incidence of the grade I type of cell and the authors realized that the proper interval to observe the cytological change of the degranulation after a single injection of morphine hydrochloride was 3 or 4 hours. However, it is not yet resolved whether such a interval of 3 or 4 hours is universal in case of another single dose of morphine hydrochloride.

In the groups given more than 12 mg./kg. of morphine hydrochloride the cytological change of the degranulation was not so proportional to the dosage of it but the degree of the degranulation was lessened.

In the group given nalorphine hydrochloride alone a light cytological change of the degranulation was observed in the mesenteric mast cell.

However, there is not synergetic effect to produce more degranulation of the mast cell when both nalorphine and morphine hydrochloride were injected together.

Räsänen (1961) reported that the administration of ACTH in intact rats caused almost complete degranulation of the mucosal mast cells and its degranulation effect was inhibited by an adrenalectomy. Oh et al. (1964) showed that whole body irradiation by X-ray induced the degranulation of mesenteric mast cells of the rat and its degranulating effect upon mesenteric mast cells was markedly inhibited after

the removal of both adrenal glands. Lee and Pak(1969) studying the inhibiting effect of the degranulation of the mesenteric mast cell after a total adrenalectomy, have found that the degranulating effect upon mesenteric mast cells by an administration of meperidine hydrochloride was generally inhibited by the removal of the glands. In this study the authors studied the inhibiting effect of the degranulation of mesenteric mast cells by the injection of morphine hydrochloride after a total adrenalectomy and realized that the effect of morphine hydrochloride on degranulation was evidently inhibited by a total adrenalectomy.

REFERENCES

- An, S. B.: *The Korean Central J. of Med.* **7**:297, 1964.
- Bhattacharya, B. K. and Lewis, G. P.: *Brit. J. Pharmacol.*, **11**:202 1956.
- Leblanc, J. and Rosenberg, F.: *Proc. Soc. Exp. Biol. and Med.*, **96**:234, 1957.
- Lee, K. S. and Pak, S. Y.: *Yonsei Med. J.*, **10**: 153, 1969.
- Oh, Y. K., Pak, S. Y., Kwon, T. S. and Choi, K. D.: *Yonsei Med. J.*, **5**:6, 1964.
- Parratt, J. R. and West, G. B.: *J. Physiol.*, **137**: 169, 1957.
- Parratt, J. R. and West, G. B.: *J. Physiol.* **137**: 179, 1957.
- Räsänen, T.: *Acta Physiol. Scand.*, **52**:162, 1961.

— Legend for Figures —

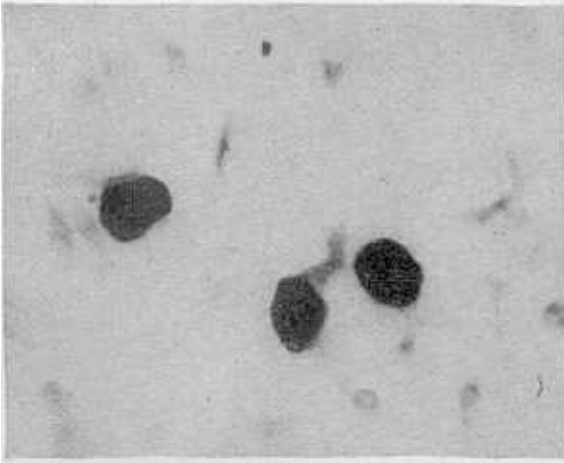


Fig. 1. Normal type of rat's mesenteric mast cell. Stained with Pugh solution, 400 \times .

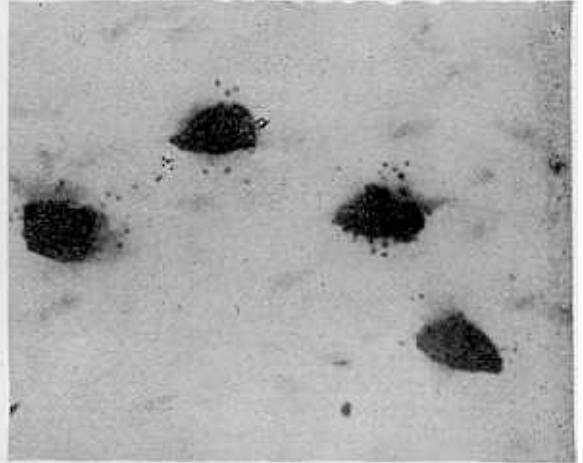


Fig. 2. Grade I type of slightly degranulation of rat's mesenteric mast cell. Stained with Pugh Solution, 400 \times .

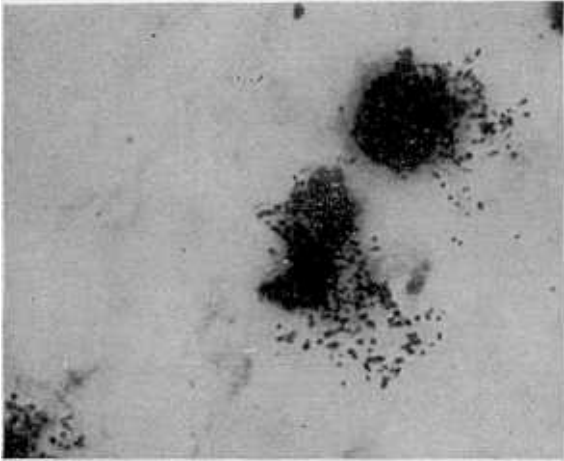


Fig. 3. Grade II type of moderate degranulation of rat's mesenteric mast cell. Stained with Pugh solution, 400 \times .

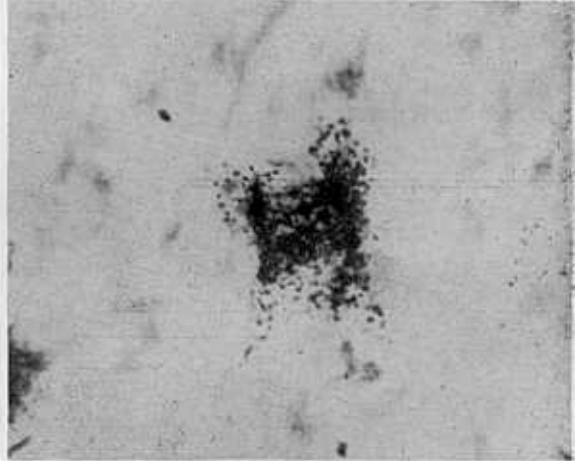


Fig. 4. Grade III type of marked degranulation or disruption of rat's mesenteric mast cell. Stained with Pugh solution, 400 \times .