

## Coexistence of Darier's Disease and Acrokeratosis Verruciformis of Hopf

Suleyman Piskin<sup>1</sup>, Aslihan Saygin<sup>1</sup>, Latife Doganay<sup>2</sup>, Deniz Kircuval<sup>1</sup>, and Eylem Gurkan<sup>1</sup>

<sup>1</sup>Department of Dermatology and <sup>2</sup>Department of Pathology, Trakya University School of Medicine, Edirne, Turkey.

Darier's disease and acrokeratosis verruciformis are inherited with the same pattern and they share similar clinical properties. We present a patient with both Darier's disease and acrokeratosis verruciformis. The patient had had brownish and skin-colored papules, initially on her face and neck, since the age of 25. Similar lesions had gradually spread to various parts of her body and lastly the dorsal aspect of her feet. On dermatological examination, brownish and skin-colored, 2 to 5 mm, keratotic papules were observed on her face, neck, both axillae, inframammary regions, and dorsa of the hands and feet. The nail examination revealed "V" shaped notches and longitudinal ridges on the fingers of both hands. The biopsy taken from the neck showed typical findings for Darier's disease. The biopsy from the dorsa of the left foot revealed the distinctive structures of acrokeratosis verruciformis. In this article the clinical and histopathological findings of these diseases are reviewed based on our patient.

**Key Words:** Darier's disease, Darier-White disease, acrokeratosis verruciformis

### INTRODUCTION

Darier's disease (Darier-White disease, keratosis follicularis) is a rare, genetic disorder of keratinization with an autosomal dominant form of inheritance. The disease commonly involves the seborrheic regions and also the palms, nails, and oral mucous membranes. The distinctive lesions of Darier's disease are firm, rather greasy, crusted papules which are skin-colored, yellow-brown or brown.<sup>1-8</sup> Darier's disease was described indepen-

dently by Darier and White in 1889.<sup>1,3,6</sup>

Acrokeratosis verruciformis of Hopf is a rare, genetic disorder of keratinization which is characterized by small, verrucous, flat, and skin-colored or reddish brown papules that are present predominantly on the dorsa of the hands and feet but may appear on the forearms, knees and elbows.<sup>1,4,5,9,10</sup> Acrokeratosis verruciformis was first described by Hopf in 1931 and the autosomal dominant nature was reported by Niedelman and Mckusick.<sup>1</sup>

Both diseases are inherited with the same pattern and most of their clinical properties are similar. In this case report, we aimed to discuss the clinical and histopathological findings of these two diseases in the light of current literature.

### CASE REPORT

A 31-year-old woman presented for evaluation with papules on her face, scalp, neck, dorsa of the hands, axillar and inframammary regions, and dorsal surfaces of the feet. The patient had had these brownish and skin-colored papules, initially on her face and neck, since the age of 25. Similar lesions had gradually spread to various parts of her body and lastly the dorsal aspect of her feet. On dermatological examination, brownish and skin-colored, 2 to 5 mm, keratotic papules were observed on her face, neck, both axillae, inframammary regions, and the dorsa of her hands and feet. The surface of the papules was slightly hyperkeratotic. No palmar or oral mucosal lesions were observed. She complained of pruritus which was more prominent during the summer time. She indicated that the papules had sometimes

Received April 8, 2003

Accepted July 21, 2003

Reprint address: requests to Dr. Suleyman Piskin, Department of Dermatology, Trakya University, School of Medicine, 22030-Edirne, Turkey. Tel: 90-284-235 76 41 / 1517, Fax: 90-284-235 76 52, E-mail: spiskin@trakya.edu.tr

coalesced to form huge, confluent, hot, painful and oozy plaques. The nail examination revealed "V" shaped notches and longitudinal ridges on the fingers of both hands. Systemic physical examination, and routine hematological and biochemical measurements were all within normal limits.

From the patient's history, it was learned that some family members had similar skin changes, including her brother and her father. Their diseases had started at nearly the same age as our patient's. The disease did not exhibit strong symptoms in her family members, compared with the patient herself, and they did not seek any medical help.

Skin biopsies were taken from the left lateral aspect of the neck and the dorsa of the left foot. The biopsy taken from the neck showed epidermal proliferation, hyperkeratosis, parakeratosis, and acantholysis in the suprabasal cells, and suprabasal separation with corps ronds and grains. All of these features are typical for Darier's disease (Fig. 1). The biopsy from the dorsa of the foot revealed hyperkeratosis, hypergranulosis, slight acanthosis, and papillomatosis that were in the form of localized elevations of the epidermis, known as "church spires" for their appearance. All these findings were very specific for acrokeratosis verruciformis (Fig. 2).

## DISCUSSION

The clinical similarities and the exact relation-

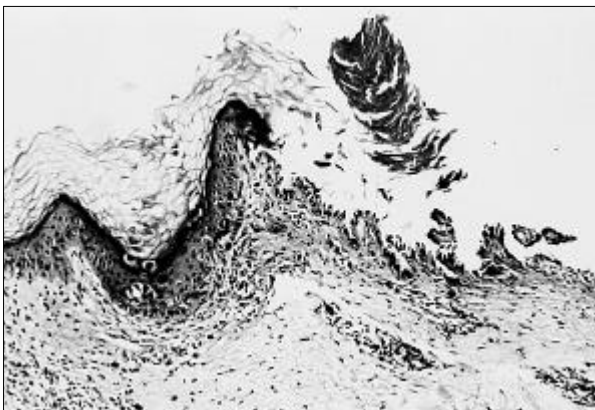


Fig. 1. Darier's disease. Parakeratotic tier corps ronds and vesicle formation in epidermis (H&E,  $\times 100$ ).

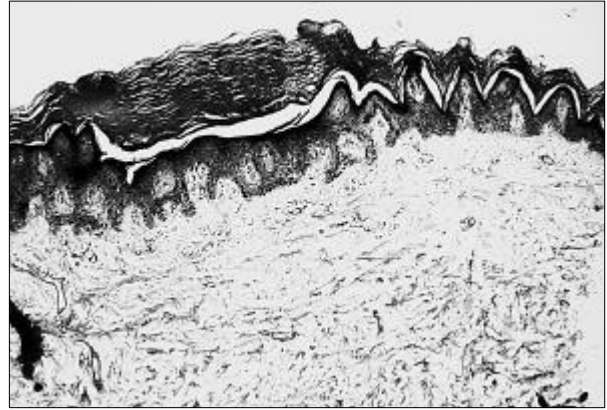


Fig. 2. Acrokeratosis verruciformis. There is moderate hyperkeratosis overlying typical "spiked" papillomatosis. The granular cell layer is prominent. (H&E,  $\times 100$ ).

ship between acrokeratosis verruciformis and Darier's disease have interested many clinicians throughout the years. Many authors maintain different points of view about these two diseases and the problem has not been satisfactorily resolved. Some authors believe that acrokeratosis verruciformis and Darier's disease are different clinical projections of the same disease,<sup>11-13</sup> while others accept that these two diseases are separate entities.<sup>4,10,14</sup> A number of observers reported that acrokeratosis verruciformis often evolves in cases of Darier's disease.<sup>15</sup> A genetic study has demonstrated that acrokeratosis verruciformis and Darier's disease are allelic disorders.<sup>16</sup> Acrokeratosis verruciformis is often associated with Darier's disease.<sup>1,2,5</sup> Our patient also had these two diseases.

Darier's disease has a dyskeratotic nature and it is mostly localized on seborrheic regions of the body. The lesions of acrokeratosis verruciformis are purely hyperkeratotic and are localized mostly on acral parts of the body and never occur on the forehead, scalp, flexures, or oral mucosa.<sup>10,14</sup> The papules located on the dorsa of the hands and feet are similar in acrokeratosis verruciformis and Darier's disease.<sup>4,6,14</sup> In our case, both acral and seborrheic areas of the body were involved by lesions of these two diseases. The oral mucosa was normal.

Darier's disease and acrokeratosis verruciformis are autosomal dominantly inherited diseases. In Darier's disease, heterogeneous clinical severity between and within generations have been re-

ported.<sup>6,17</sup> Our patient's family members (father and brother) also had the disease with a silent pattern.

Punctuated pits, most of which were covered by pinpoint- to pinhead-sized, horny pearls in the palms and soles, could be observed in both diseases but mostly in patients with acrokeratosis verruciformis.<sup>14</sup> Our patient's palms and soles were not involved by any lesion.

The nails in acrokeratosis verruciformis are whitish with occasional breakages at the ends and longitudinal ridges. The nail changes in Darier's disease are the same as those in acrokeratosis verruciformis, but are probably more common and marked, such as "V" deformity. Subungual hyperkeratosis is also commonly observed.<sup>3,6,8,9,14</sup> The nail findings of both diseases existed in our case.

Histopathological findings of acrokeratosis verruciformis and Darier's disease are very specific to each separate disease and differentiation between the two diseases is very helpful for correct diagnosis in difficult cases. The characterized changes in Darier's disease are a peculiar form of dyskeratosis resulting in the formation of corps ronds and grains, suprabasal acantholysis leading to the formation of suprabasal clefts or lacunae, and irregular upward proliferation into the lacunae of papillae lined with a single layer of basal cells.<sup>18</sup> The classic histological findings in acrokeratosis verruciformis are considerable hyperkeratosis, an increase in thickness of the granular layer, and acanthosis. In addition, there is slight papillomatosis, which is frequently but not always associated with circumscribed elevation of the epidermis resembling church spires.<sup>18</sup> The keratotic papules that may occur on the dorsa of the hands and feet and that clinically resemble those seen in acrokeratosis verruciformis, especially on serial sectioning, show mild dyskeratotic changes and often suprabasal clefts as well. They are a manifestation of Darier's disease and not of acrokeratosis verruciformis.<sup>18</sup> In our case, histological specimens taken from two different body sites were evaluated to identify two distinct diseases in the same patient.

In conclusion, the follow-up of patients with Darier's disease or acrokeratosis verruciformis may contribute to explaining the relationship

between these two diseases.

## REFERENCES

1. Goldsmith LA, Baden HP. Darier-White disease (keratosis follicularis) and acrokeratosis verruciformis. In: Freedberg IM, Eisen AZ, Wolff K, Austen KF, Goldsmith LA, Katz SI, et al. editors. *Fitzpatrick's dermatology in general medicine*. 5th ed. New York: McGraw-Hill Inc; 1999. p.614-9.
2. Goldsmith LA, Thomas NE. Disorder of cornification. In: Moschella SL, Hurley HJ, editors. *Dermatology*. 3rd ed. Philadelphia: WB Saunders; 1992. p.1383-417.
3. Gibstine C, Lazar P. Keratosis follicularis (Darier's disease) In: Demis DJ, editor. *Clinical dermatology*. 19th rev. Philadelphia: Harper and Row; 1992. Vol 1, Unit 1-35: p.1-9.
4. Griffiths WAD, Judge MR, Leigh IM. Disorders of keratinization. In: Champion RH, Burton JL, Burns DA, Brethnach SM, editors. *Rook/Wilkinson/Ebling textbook of dermatology*. 6th ed. Oxford: Blackwell Science Ltd; 1998. p.1483-588.
5. Braun-Falco O, Plewig G, Wolff HH, Burgdorf WHC. *Dermatology*. 2nd ed. Berlin: Springer-Verlag; 2000.
6. Burge SM, Wilkinson JD. Darier-White disease: A review of the clinical features in 163 patients. *J Am Acad Dermatol* 1992;27:40-50.
7. Berg D, Bassett AS. Darier's disease: Current understanding of pathogenesis and future role of genetic studies. *Int J Dermatol* 1993;32:397-400.
8. Piskin S, Ozyilmaz F, Akgun N, Durukan N. Darier's disease. *T Klin J Dermatol* 2000;10:206-8.
9. Waisman M. Acrokeratosis verruciformis (Hopf). In: Demis DJ, editor. *Clinical dermatology*. 19th rev. Philadelphia: Harper and Row; 1992. Vol 1, Unit 1-36: p.1-4.
10. Chapman-Rolle L, DePadova-Elder SM, Ryan E, Kantor GR. Persistent flat-topped papules on the extremities. *Arch Dermatol* 1994;130:508-12.
11. Niordson AM, Sylvest B. Bullous dyskeratosis follicularis and acrokeratosis verruciformis. Report of a case. *Arch Dermatol* 1965;92:166-8.
12. Waisman M. Verruciform manifestations of keratosis follicularis. *Arch Dermatol* 1960;81:1-14.
13. Herndon JH Jr, Wilson JD. Acrokeratosis verruciformis (Hopf) and Darier's disease. *Arch Dermatol* 1966;93: 305-10.
14. Panja RK. Acrokeratosis verruciformis (Hopf): A clinical entity? *Br J Dermatol* 1977;96:643-52.
15. Hafner O, Vakilzadeh F. Acrokeratosis verruciformis-like changes in Darier disease. *Hautarzt* 1997;48:572-6.
16. Dhitavat J, Macfarlane S, Dode L, Leslie N, Sakuntabhai A, MacSween R, et al. Acrokeratosis verruciformis of Hopf is caused by mutation in ATP2A2: Evidence that it is allelic to Darier's disease. *J Invest Dermatol* 2003; 120:229-32.

17. Inada M, Shimizu H, Yamada S, Sasaki Y, Nishikawa T. Three cases of Darier's disease in a family showing marked heterogeneous clinical severity. *Dermatology* 1999;198:167-70.
18. Johnson B, Honig P. Genodermatoses. In: Elder D, Elenitsas R, Jaworsky C, editors. *Lever's histopathology of the skin*. 8th ed. Philadelphia: Lippincott-Raven; 1997. p.117-50.