

An Experimental Intraarticular Implantation of Woven Carbon Fiber Pad into Osteochondral Defect of the Femoral Condyle in Rabbit.

Ho Jung Kang, Chang Dong Han, Eung Shick Kang,
Nam Hyun Kim and Woo Ick Yang¹

The defects of the articular cartilage structure are not replaced unless the subchondral plate has been breached. However, following the creation of a defect in the subchondral plate, the area is filled in with a fibrous tissue which gradually transforms to hyaline cartilage. The porous nontoxic materials of both biologic and synthetic origin have reportedly been used as matrices for repairing bone and cartilage. Following implantation, carbon fibre, chemically inert and well-tolerated by the body, induces a proliferation of ordered fibrous tissue. We implanted carbon fiber pads in osteochondral defects in rabbits. Those repairs were compared to control holes with no implants. The pads appeared to induce the gross appearance of a restored joint surface, mechanically strong to loading for periods from 2 to 6 weeks. Also, carbon fiber pads promoted the healing of the osteochondral defects in the rabbit femoral condyle, supplying well-organized cartilaginous tissue over repaired subchondral bone. The use of carbon fiber pads as implant material is suggested for the restoration of articular surface in osteoarthritis and osteochondritis dissecans.

Key Words : Osteochondral defects, carbon fiber pads

In 1743 Hunter stated, "From Hippocrates to the present time, it is universally allowed that ulcerated cartilage is a trouble something and that when once destroyed it is not repaired". However, subsequent work has shown that full thickness defects which violate subchondral bone will heal by a proliferation of granulation tissue from the marrow spaces. Understanding of the nature of repair in injured articular cartilage is important because persistent irregularity of the joint surface, mechanical dysfunction, and pain may ensue. The full thickness defects are variably replaced by an ingrowth of vascular

connective tissue arising from primitive mesenchymal cells of the underlying bone (Convery *et al.* 1972; Havdруп and Telhag 1978).

Articular surface drilling to achieve a fibrocartilage surface from subchondral bone has had only limited success. Drilling alone may encourage vascularization and a fibrous response in defects less than 1 cm in diameter; however, the larger defect repair by chondrectomy and drilling has been particularly disappointing (Mankin 1982; Mitchell and Shepard 1976).

A reconstituted collagen sponge implant was used to enhance tissue repair in osteochondral defects in the rabbit. The desirable properties of the collagen sponge as a prosthetic material included porosity and biocompatibility (Minns and Steven 1977; Speer *et al.* 1979). Carbon fiber has the properties of being well-tolerated by the body and appears to induce a proliferation of ordered collagenous fibrous tissue in the direction of the carbon fiber filaments. In its pure form, it is chemically inert and is biocompatible in the environment of the knee. In a

Received November 21, 1991

Accepted March 22, 1991

Departments of Orthopaedic Surgery and Pathology¹, Yonsei University College of Medicine, Severance Hospital, Seoul Korea.

This study was presented at the first APLAR meeting in Seoul, 1990.

Address reprint requests to Dr. H J Kang, Department of Orthopaedic Surgery, Yonsei University College of Medicine, CPO Box 8004, Seoul, Korea, 120-742

previous study, filamentous carbon fiber was investigated as a repair material for articular cartilage and bone. The same conclusions were drawn regarding its inertness and fibrous tissue repair properties, both perpendicular and parallel alignment to the articular surface (Minns *et al.* 1982).

In this study, we reported on the histological and scanning electron microscopic response to carbon fiber pads implanted into the non-weight bearing portion of femoral condyle of rabbits. They were allowed free movement after surgery to ascertain the compliance of the resulting repair tissue in the new concept of biological resurfacing.

MATERIALS AND METHODS

Twenty adult New Zealand white rabbits of a mass greater than 2.5 kg were used. Under anesthesia with Nembutal (pentobarbital), the right knee of each animal was opened through a medial parapatella incision and the patella was dislocated. The articular surface of the distal femur, including the cartilage of the trochlea, was exposed. A hand drill with drill bit was used to create a circular defect 3.5 mm in diameter and 3 mm deep on the trochlear articular surface of the femur. The carbon fibers are fabricated from organic fibers such as

"rayon". The fiber volume is about fifteen percent of the fabric (Fig. 1). A sterile carbon fiber pad 3.5 mm in diameter and 3 mm thick was carefully placed in the defect producing a fit flush with the articular surface (Fig. 2).

The patella was relocated so that the pad surface articulated with the patella articular surface to prevent the pad's emergence from the hole.

The capsule and skin were closed in separate layers. The left knee was opened and the drilling procedure repeated for the control. All animals received intramuscular injections of Kanamycin every three days as a prophylaxis against infection. The animals were free to move immediately post-operatively. The rabbits were sacrificed three months after the operation. Periodic gross, histological and scanning electron microscopical examinations were carried out. A post-mortem, gross examination of the joints was made to assess effusion, inflammation, contractures, adhesion, infection and hematomas.

The femoral patella groove areas were carefully excised for histology and electron microscopy. It was necessary to remove the cartilage and fragments of subchondral bones. Each sample was divided into two blocks which were immediately fixed and embedded for light and electron microscopy. At least three slices were obtained from each block. Each slice was fixed overnight in formalin, embed-




Fig. 1. Scanning electron microscopy of the carbon fiber. The fibers are typically six to nine microns in diameter and possess a relatively smooth surface texture ($\times 8,000$).

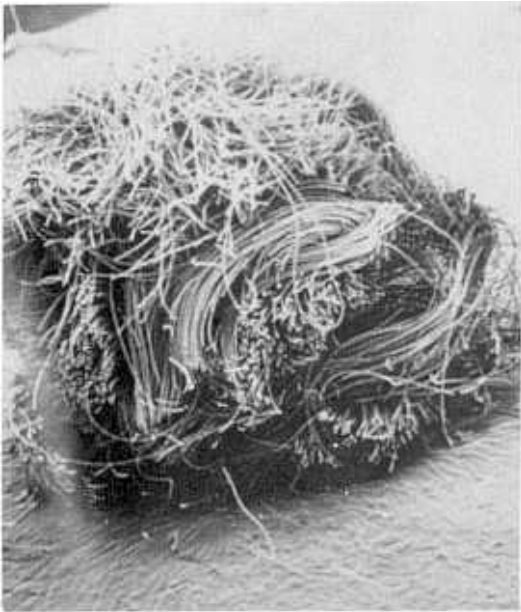

Fig. 2. Scanning electron microscopy of the carbon fiber implant, which is approximately 3.5 mm in diameter and 3 mm in thickness($\times 25$).

ded in paraffin and prepared for histological evaluation using hematoxylin eosin and Masson trichrome stain. The remainder was fixed in 2 percent glutaraldehyde in paraformaldehyde and 0.1 M cacodylate, pH 7.4 for two hours, washed in paraformaldehyde and 0.1 M cacodylated solution, and then fixed for an additional two hours in 1 percent osmium tetroxide. The samples were then rinsed in a buffer and dehydrated in a graded ethanol series. The pieces were placed in small wire baskets, and placed in the pressure chamber of an Hitachi-HCP-2 critical point dryer. The dried tissue was coated with gold by Eiko IB-3 ion coater. Thin sections were examined in a Hitachi S-450 transmission microscope.

RESULTS

Gross Findings

The macroscopic appearance of the healing defects in the control group of the animals showed a poor, depressed repair process occurring within the holes on the patella groove. The repair was much more substantial when the defect was filled with

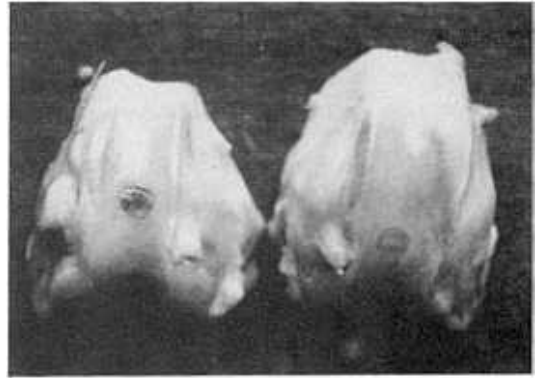


Fig. 3. The gross appearance at 7 days after operation. The left side with the implanted hole was more substantial than right control defect.

the carbon fiber implant on the patella groove of the femur(Fig. 3). There was little or no inflammatory reaction to the adhesion. At one month post-operative, some holes were left clearly visible.

Control defects were depressed below the surrounding articular surface, whereas the implanted defects remained nearly level with the surrounding articular surfaces. A fibrous membrane covered all defects by 2 to 3 weeks. After 4 weeks there was an increased amount of synovial fluid and minimal synovial hypertrophy in both groups. At 6 weeks after the operation, while testing the surface over the defects with a rounded probe, the control holes were easily deformed. The defects containing the carbon fiber implants were significantly harder, much like the stiffness of the surrounding articular surface.

After 2 months the controlled 3.5 mm defects were easily seen. The surface was flush with the surrounding articular cartilage, although the difference in surface texture was easily recognizable. Only two of the twenty animals in the implanted group had defects.

Scanning Electron Microscopic Findings

The repaired surface of the rabbits defective articular cartilage was studied with scanning electron microscopy. One week after the operation, fibrous materials, possibly of fibrin and exudated blood cells, were attached to the surface. After two weeks, lining cells enmeshed with fine fibrils covered most of the surface. After two weeks, cellular

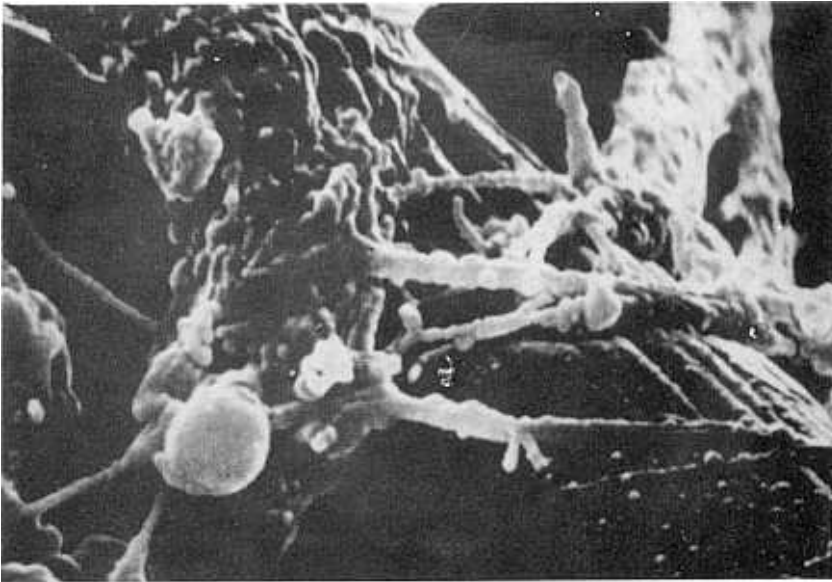


Fig. 4. Scanning electron microscopy after 2 weeks. The cytoplasmic processes of fibroblast engulfed a carbon fiber ($\times 10,000$).

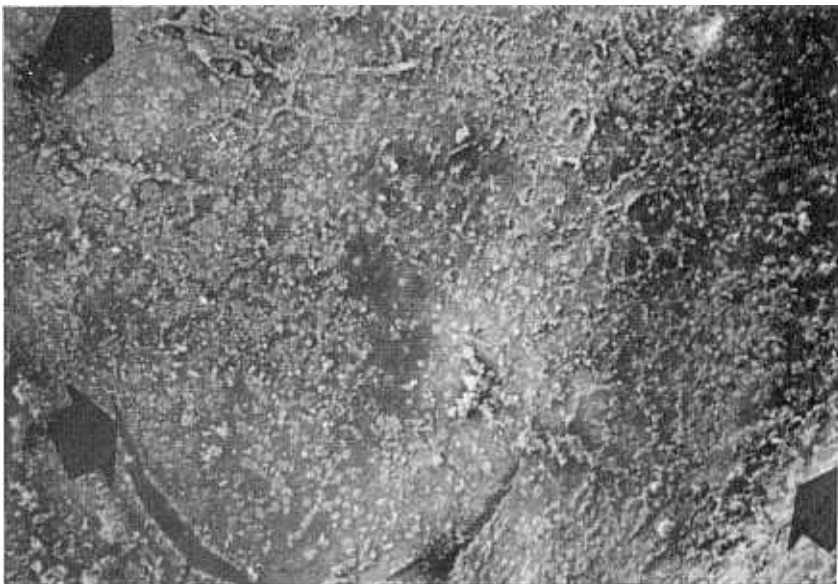


Fig. 5. Scanning electron microscopy at 4 weeks after operation. The implant hole of carbon fiber is not well-defined and a smooth articular surface can be seen ($\times 15$).

protrusion of the fibroblast like cells engulfed each carbon fiber (Fig. 4). When observed in the scanning electron microscope at four weeks post operative,

the control defects were clearly visible. With the carbon fiber implant the defects were not well-defined, and the smooth surface of the articular carti-

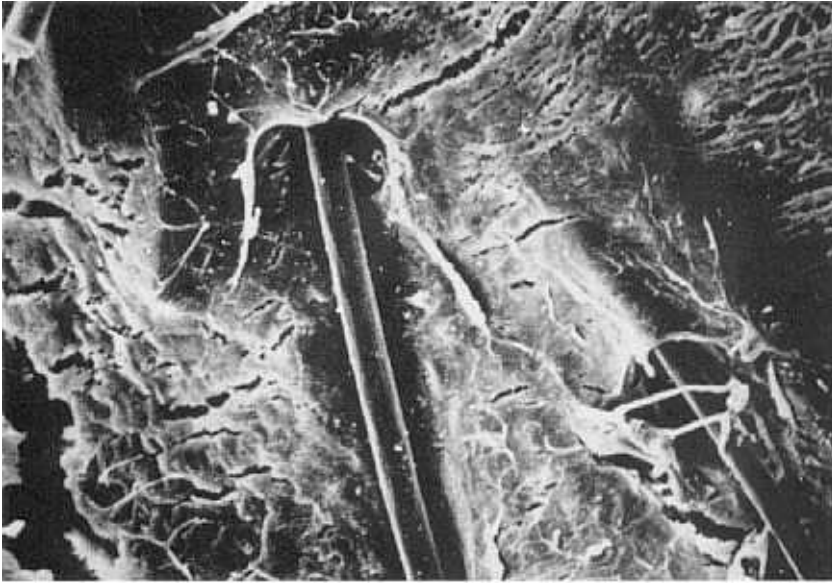


Fig. 6. At 8 weeks after operation. A few carbon fibers were noted on the superficial regenerating articular surface ($\times 7,000$).




Fig. 7. Carbon fiber implant 4 weeks after operation shows the formation of organized fibrous tissue above and within the implant(H & E, $\times 100$).

lage was commonly seen(Fig. 5). In two out of the twenty cases with implanted defects, carbon fibers were noted on the superficial regenerating surface at eight weeks postoperative(Fig. 6). A crosssection

of implanted carbon fiber area showed that repair tissue orients itself parallel to the carbon fiber bundles.

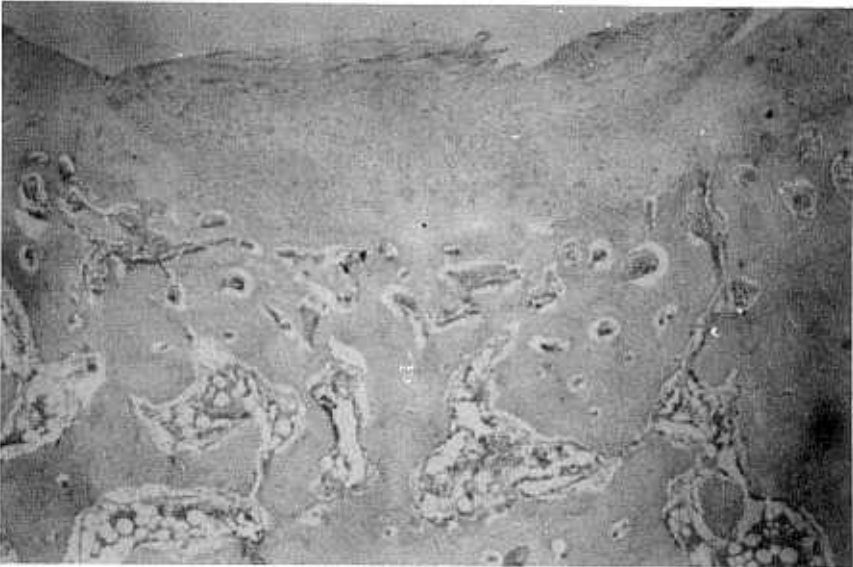


Fig. 8. Controlled defect 8 weeks after operation. It shows overflow and irregular articular surface of regenerating fibrocartilagenous tissue (H & E, $\times 100$).

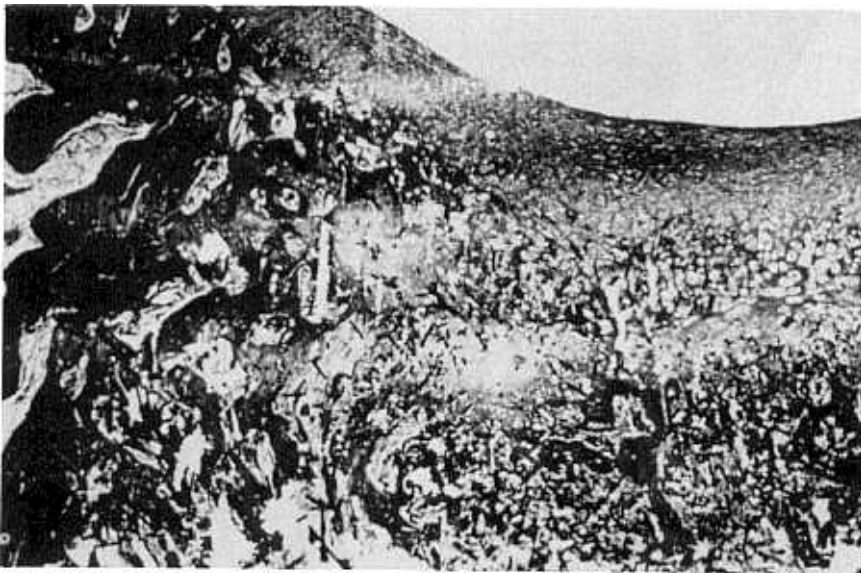


Fig. 9. Histology 8 weeks after operation shows the dense cartilagenous tissue which provided a new surface for the defective cartilage (Masson-trichrome, $\times 100$).

Histological Findings

Histologically, the control defects were initially filled with weak birefringent fibrous repair tissue.

The initial fibrous repair in the implant-filled defects was more prolific with organized fibrous tissue above and within the carbon fiber.

Fibrous and cellular clot elements, as well as

abundant macrophages, were still present in both control and implant at 2 to 3 weeks. Four weeks after the operation, the hole containing the implant was filled with a dense organized matrix of collagen-based fibrous tissue which invaded the trabeculae of the underlying subchondral bone (Fig. 7). The control holes had less fibroblastic response and bony tissue than the implanted holes.

Two months later, observing the control holes through the subchondral plate, plugs of cartilaginous material had appeared in the holes and spread for a variable distance over the articular cartilage. The overflow or irregularity of the regenerating surface was noted in one fourth of the control group (Fig. 8). The cells at the base of the holes had the appearance of chondrocytes. The cells' surface layers were more typical of fibrocartilage, and the usual tangential collagen orientation had been lost. The implant hole had been completely replaced with hypercellular cartilaginous tissue. This cartilaginous tissue provided a new smooth functioning surface for the denuded joint (Fig. 9). It looked like a lattice work of carbon fibers surrounded by orderly collagenous tissue, moderately cellular and with a minimal inflammatory cell infiltrate. Carbon fiber had been used for a structural scaffold. Endochondral ossification was seen in the peripheral and deeper zones around the implant, with invasion of the fibrous tissue into the adjacent bone. Eventually, new bone grew around the carbon implant producing a strong plug of organized tissues. After 2 months the control defects were also completely filled, but the replacement tissue was a variable mixture of fibrous tissue and fibrocartilage.

DISCUSSION

Articular cartilage defects which do not involve the subchondral bone have a poor reparative response, whether they are in load-bearing or non load-bearing areas (Depalma et al. 1966; Treadwell and Mankin 1986).

Many techniques have been used to repair the osteochondral defects. Periosteal grafting using autogenous tissue, as well as meniscal fibrocartilage, has been commonly used in animals and humans with a high degree of success (Benum 1971). The resulting matrix has become incorporated into the defect by creeping substitution, and, in some cases, revascularization has occurred. Continuous passive motion and exercise enhance the regeneration and repair of articular cartilage in the dog and the rab-

bit, suggesting that mechanical loading of the repair tissue stimulates neochondrogenesis (Honner and Thompson 1971; Thompson 1975).

Drilling alone may encourage vascularization and a fibrous response in small defects, but the repair of larger grade II defects (that is, erosion of articular cartilage down to subchondral bone) by chondrectomy and drilling has been particularly disappointing. The repair process of large osteochondral defects in synovial joints is not entirely clear. Full thickness defects, however, are variably replaced by an ingrowth of vascular connective tissue, arising from primitive mesenchymal cells of the underlying bone (Clarke 1971).

Other workers have considered the use of synthetic materials, such as silicon, nylon carbon fiber, and biological materials, such as collagen sponge, to repair osteochondral defects by producing a fibrous matrix able to withstand functioning loads that are encountered in daily use (Rushton et al. 1983; Ward and Minns 1989).

Carbon fiber has been used for the reconstruction of parallel-fibered tissues such as ligaments and tendons. It induces a proliferation of ordered collagenous fibrous tissue in the direction of the carbon fiber filaments (Forster et al. 1978; Jenkins et al. 1977). Since the study by Minns et al. (1987), filamentous carbon fiber fabric has been shown to become infiltrated rapidly with dense, organized connective tissue in vivo. When implanted in subchondral bone, following excision of the defective area of the cartilage, new fibrocartilage is generated in the interstices of the material.

The implant pads are composed of pure carbon fiber. Carbon fiber is derived by a heat treatment process from polyacrylonitrile fibers. The fibers are converted to fabric form by intricate textile processes. The pad is produced as discs of fabric in varying diameters. Though extremely strong in tension, the pad has little strength in shear and bending and has virtually no "knotting" strength. Consequently, these implants should be positioned to avoid loading that would tend to cause fragmentation. The pads should not protrude outside the line of the original articular surface. We implanted the pad to the non load-bearing of patella groove of femur. Implants are inserted into an undercut in the bone and are fixed only by an interference fit. No cement or stabilization pins are required.

When filled with fibrous tissue, the resultant composite appears mechanically compliant. Its viscoelasticity protects the carbon fibers from mechanical insult which would lead to fragmentation.

The tough collagenous matrix formed this way provides a new articular surface and restores function to the joint. The rapid improvement in viscoelastic properties of woven carbon fiber after implantation demonstrates the vital role of the collagen component. It protects the relatively brittle carbon fiber from high stress and, therefore, prevents fragmentation, a common problem with filamentous carbon fiber (Minns *et al.* 1987). In this study, abundant fibrous tissue invaded the implant interstices and the trabeculae of the subchondral bone. No evidence of implant fragmentation has been seen up to 4 weeks after implantation in the eight knees studied.

Articulating surfaces of joints are susceptible to physical degeneration from either osteoarthritis or trauma (Furukawa *et al.* 1980; Weiss and Mirow 1972). Such conditions commonly result in impaired joint function and considerable pain. Damaged articular cartilage has an extremely limited capacity for regeneration; therefore, extensive surgery may be indicated, arthrodesis, osteotomy or total joint replacement. Frequently, routine joint replacement is an unsatisfactory solution, particularly in young patients, with osteochondritis dissecans and chondromalacia patellae. Still, it is important to ascertain how much strength this repair material provides as a functioning zone of articulation and how it performs viscoelastically to protect the surrounding and underlying bone from dynamic insult and further degeneration. Although the repair material is not as stiff as the articular cartilage, this additional compliance may protect the underlying bone from dynamic loading which produces fatigue fractures, microfractures and further degeneration. In the twenty knees reported in this paper, we have seen neither evidence of disintegration in any of the pads nor migration of carbon fiber debris into the joint cavity or surrounding tissues. But in two out of the twenty cases with implanted cases, carbon fibers were noted on the superficial surface at ten weeks post operation.

Previous studies where complete replacement of full-thickness defects occurred have been limited to small animals and, consequently, to correspondingly small defects. Depalma *et al.* (1966) found complete filling after 16 weeks in all of his 4 mm full-thickness defects. Calandruccio and Gilmer (1962) also produced 4 mm defects. These defects were evaluated at varying times up to 16 weeks and 9 of the 15 were completely replaced (Ghadially *et al.* 1971). In our study, the defects were completely replaced by dense fibrous tissue after 8 weeks.

Applying study information to clinical situations is

difficult. Our study suggests that woven carbon fiber pads deserve further evaluation i.e. a longer period of follow-up and testing in weight bearing articular cartilage lesions.

CONCLUSION

Carbon fiber pads placed in the osteochondral defect of the rabbit knee elicit a dense, organized matrix of fibrous tissue that forms a new biological and functioning smooth articular surface.

A new fibrocartilage was quickly formed in less than six weeks giving good wearing characteristics with fixation through supportive fiber patch.

This study shows that the woven carbon fiber pads have clinical relevance in osteochondral defects, giving a firm, dense and pliable structural covering.

REFERENCES

- Benum P : Autogenous transplantation of apophyseal cartilage to osteochondral defects of joints. *Acta Orthop Scand* 14 : 156, 1944
- Calandruccio RA, Gilmer WS Jr : Proliferation, regeneration, and repair of articular cartilage of immature animals. *J Bone and Joint Surg* 44A : 431, 1962
- Clarke IC : Articular cartilage : A review and scanning electron microscope study. *J Bone and Joint Surg* 53B : 732, 1971
- Convery FR, Akeson WH, Keown GH : The repair of large osteochondral defects. *Clin Orthop* 82 : 253, 1972
- Depalma AF, McKeever CD, Subin DK : Process of repair of articular cartilage demonstrated by histology and autoradiography with tritiated thymidine. *Clin Orthop* 48 : 229, 1966
- Forster IW, Ralis ZA, McKibbin B, Jenkins DHR : Biological reaction to carbon fiber implants : the formation and structure of a carbon-induced 'Neotendon'. *Clin Orthop* 131 : 299, 1978
- Furukawa T, Eyre DR, Koide S, Glimcher MJ : Biochemical studies on repair cartilage resurfacing experimental defects in the rabbit knee. *J Bone and Joint Surg* 62A : 79, 1980
- Ghadially FN, Fuller, JA, Kirkaldy-Willis WH : Ultrastructure of fullthickness defects in articular cartilage. *Arch Path* 92 : 356, 1971
- Havdrup T, Telhag H : Scattered mitosis in adult joint cartilage after partial chondrectomy. *Acta Orthop Scand* 49 : 424, 1978
- Honner, R, Thompson RC : The nutritional pathways of articular cartilage. *J Bone and Joint Surg* 53A : 742, 1971

- Jenkins DHR, Forster IW, McKibbin B, Ralis ZA : Induction of tendon and ligament formation by carbon implants. *J Bone and Joint Surg* 59B : 53, 1977
- Mankin HJ : The response of articular cartilage to mechanical injury. *J Bone and Joint Surg* 64A : 460, 1982
- Minns RJ, Betts JA, Muckle DS, Frank PL : Carbon fiber arthroplasty of the knee : Preliminary clinical experience in a new concept of biological resurfacing. *Recent Developments in Orthop Surg* 44 : 1, 1987
- Minns RJ, Muckle DS, Donkin JE : The repair of osteochondral defects in osteoarthritic rabbit knees by the use of carbon fiber. *Biomaterials* 3 : 81, 1982
- Minns RJ, Steven FS : The collagen fibril organization in human articular cartilage. *J Anat* 123 : 437, 1977
- Mitchell N, Shepard N : The resurfacing of adult rabbit articular cartilage by multiple perforations through the subchondral bone. *J Bone and Joint Surg* 58A : 230, 1976
- Rushton N, Dandy DJ, Naylor CPE : The clinical, arthroscopic and histologic findings after replacement of the anterior cruciate ligament with carbon-fiber. *J Bone and Joint Surg* 65B : 308, 1983
- Speer DP, Chvapil M, Volz RG, Holmes MD : Enhancement of healing in osteochondral defects by collagen sponge implants. *Clin Orthop* 144 : 326, 1979
- Thompson RC : An experimental study of surface injury to articular cartilage and enzyme responses within the joint. *Clin Orthop* 107 : 239, 1975
- Treadwell BV, Mankin HJ : Synthetic process of articular cartilage. *Clin Orthop* 213 : 50, 1986
- Ward R, Minns RJ : Woven carbon-fiber patch versus Dacron mesh in the repair of experimental defects in the lumbar fascia of rabbits. *Biomaterials* 10 : 425, 1989
- Weiss C, Mirow S : An ultrastructural study of osteoarthritic changes in the articular cartilage of human knees. *J Bone and Joint Surg* 54A : 954, 1972
-