

Histological Studies of Surgically Resected Hepatocellular Carcinoma Following Combined Radiotherapy and Hyperthermia

Jin Sil Seong¹, Eun Kyung Han², Kwang Hyub Han³, Sung Hoon Noh⁴,
Chan Il Park², John J. K. Loh¹ and Heung Jai Choi³

Four cases of hepatocellular carcinoma (HCC) were surgically resected following combined radiotherapy (RT) and hyperthermia (HT). Complete necrosis of the tumor without viable tumor cell was found in one case and extensive tumor necrosis was observed in the other three cases; the percentage of necrosis in the specimens were 40%, 70%, and 80%, respectively. Histologic assessment showed mainly coagulative necrosis in the tumor with focal liquefactive necrosis. Cystic dilatation of sinusoids was observed in both tumor and nontumorous normal liver tissue. Other changes in normal liver tissue were unremarkable except for infiltration of inflammatory cells, fatty change, and proliferation of the bile ducts which can usually be seen beyond the area where any space occupying lesions are present. It is concluded that combined radiotherapy and hyperthermia can significantly induce coagulative necrosis of hepatocellular carcinoma with nonsignificant minimal histologic changes in adjacent nontumorous liver tissue.

Key Words : Hyperthermia, radiotherapy, hepatocellular carcinoma, histological change

The best chance for a cure in the treatment of primary hepatocellular carcinoma (HCC) is early diagnosis and subsequent surgical resection. An advanced stage of HCC, which can be found in most Korean patients with HCC in Korea, and the high incidence of concurrent hepatic parenchymal disease such as liver cirrhosis seriously limit the chance of surgical resection.

Many efforts have been made in the treatment of the advanced HCC; systemic chemotherapy using various drug combination (Falkson et al. 1978; Sciarrino et al. 1985; Vogel et al. 1977), transhepatic arterial embolization (Sakurai et al. 1984; Yamada et al. 1983), internal radiotherapy using I-

131 lipiodol of I-131 antiferritin (Grady et al. 1983; Sitzmann et al. 1987; Yoo et al. 1988) and so on.

Combined radiotherapy (RT) and regional hyperthermia (HT) have also been tried in the treatment of advanced HCC in this institute since 1988 because of the belief that more than additive or even synergistic interaction of radiation and hyperthermia would cause effective tumor necrosis, even the limited radiation dose for fear of radiation hepatitis would not be enough to kill the tumor cell.

Tumor shrinkage of more than 50% of the initial volume with this combined modality was observed in 12 of the 30 patients followed (Seong et al. 1989). Among the patients who showed marked tumor response, four underwent surgical resection.

Herein we report our experience on combined RT and HT for HCC with respect to histological study.

Among the patients who were treated according to the treatment protocol of combined RT and HT for advanced HCC since April 1988, four patients were referred for surgical resection after achieving marked shrinkage of tumor in size following com-

Received October 26, 1990

Accepted March 4, 1991

Departments of Radiation Oncology¹, Pathology², Internal Medicine³, and General Surgery⁴ Yonsei University College of Medicine, Seoul, Korea

Address reprint requests to Dr. J S Seong, Department of Radiation Oncology, Yonsei University College of Medicine, CPO Box 8044, Seoul, Korea, 120-752

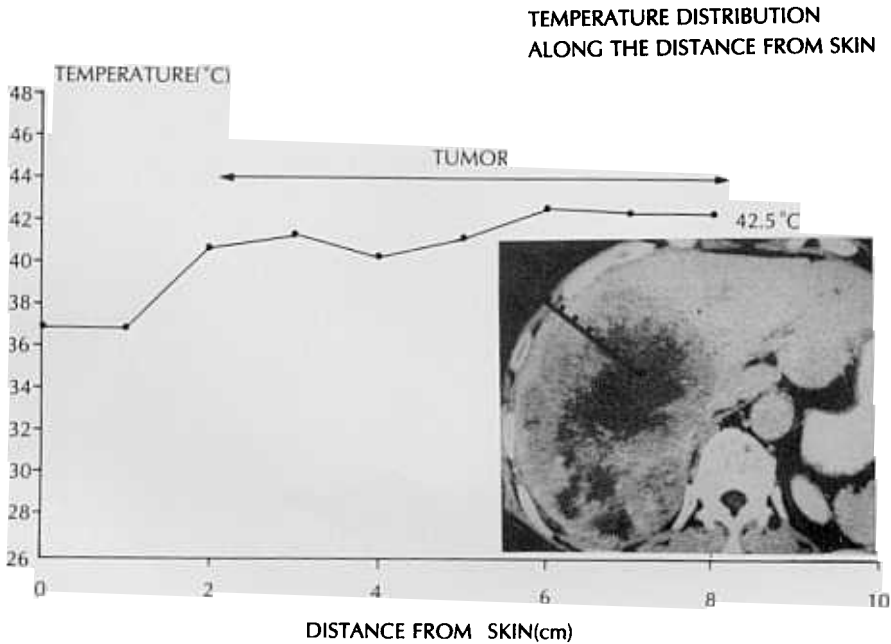


Fig. 1. Thermal distribution in case #1: The temperature of the tumor is between 40°C and 42.7°C while that of skin, subcutaneous tissue, and adjacent normal liver is below 40°C.

bined RT and HT. Those patients are the subjects of this study.

The diagnosis of HCC was confirmed histologically through needle aspiration biopsy along with clinical manifestations, laboratory test (particularly alpha-fetoprotein (AFP), and various imaging examinations including CAT scan, ultrasonography, and angiography.

The treatment protocol consisted of external radiotherapy which include the tumor mass with generous margin, 3060 cGy in 3.5 weeks and hyperthermia.

Hyperthermia was induced twice a week for a total of 6 sessions, using 8 MHz capacitive heating device (Thermotron RF-8; Yamamoto Vinyter Co., Japan). Each hyperthermic session was started within 30 minutes after radiotherapy and continued for 30-60 minutes in all cases. To prevent excessive heating of the surface of the skin, circulating 0.4% NaCl solution between the heat exchanger and electrodes was maintained at the temperature of 5-10 °C. The method of this hyperthermia treatment has also been reported elsewhere (Loh et al. 1989).

Temperature measurement of the tumor during hyperthermia was done in one patient (case #1)

through a thermocouple (Sensortek Inc., Type IT-18, New Jersey) which was inserted into the center of the tumor under ultrasonographic guidance. Temperature profile showed that the temperature in the tumor was between 41°C and 42.7°C with slight difference from one site to another (Fig. 1).

Surgical resection was performed one week after the completion of the treatment in two patients (case #3, 4). The other two patients underwent resection 20 and 52 weeks after the treatment. All the resected livers were cut into 1 cm thick slices after fixation. Each slice containing the tumor was sectioned for histologic assessment.

RESULTS

The main clinical features and treatment results of the patients are summarized in Table 1. In 3 of the 4 patients the tumor shrunk markedly in size following combined RT and HT which were measured from CAT scan.

After surgical resection, complete histological tumor necrosis was found in one patient and considerable extent of necrosis, although incomplete,

Table 1. Clinical features of the patients with hepatocellular carcinoma: surgically resected cases following combined radiotherapy and hyperthermia

Case	Age/Sex	HBsAg	Liver Cirrhosis	AFP (IU/ml)		Tumor size(cm)		RT.HT to op(wk)	Outcome
				*Pre/RT.HT/op		Pre/op			
1	64/M	-	Absent	30300/	6.7/<3	11×16×13/4×3.5×3.5 4.2×3.2×3		20	14mo.alive
2	53/F	+	Absent	30300/1418/	<3	8×10×13/3×3×3 2.5×2×2		52	22mo.alive
3	56/M	+	Absent	137/	<3/3.5	12×9×7/5×5×5 4×2×2		1	15mo.dead
4	46/F	+	Present	1404/*	NT/5	8×8×8/8×8×8		1	5mo.alive

* Pre/before the combined RT/HT RT.HT; just after the combined RT.HT op: after operation NT: not tested

Table 2. Pathology of 4 patients with hepatocellular carcinoma after combined radiotherapy and hyperthermia

Case	Size(cm)	Gross type	Capsule	Percent tumornecrosis	Status of adjacent normal liver tissue	
					Cirrhosis	Cystic dilatation of sinusoid
1	4×3.5×3.5 4.2×3.2×3.2 and spreading	Mixed expanding	++	100%	-	+
2	3×3×3 2.5×2×2	"	++	40%	only septation	+
3	5×5×5 4×2×2	"	++	70%	-	+
4	8×8×8	expanding	++	80%	+	+

was found in the other three patients.

Histologic changes (Table 2)

The tumor necrosis, which was seen in all 4 patients to varying extent, was essentially coagulative necrosis. However, liquefactive hemorrhagic necrosis was also frequently found in the focal area, particularly in case #3; one large tumor nodule was totally replaced by hemorrhagic necrosis which appeared similar to hematoma.

Tumors were encapsulated with a thick tumor capsule (more than 2mm in thickness). Extensive degree of hyalinization of collagen fiber was shown in the capsule with other changes such as foamy cell infiltration, atypical proliferation of fibroblast, and deposition of hemosiderin (Fig. 4b).

In the surrounding nontumorous liver tissue, cirrhosis which had already been present before the combined RT and HT was accompanied in case #4. Some noncirrhotic fibrotic change, septation, was observed in the liver parenchyme of case #2. Infil-

tration of inflammatory cells and fatty change were also observed in other three cases.

Cystic dilatation of sinusoids were observed in both tumor and nontumorous liver tissue in all cases (Fig. 5a, b). In some areas, marked congestion was also noted.

Patient with complete tumor necrosis (case #1, Fig. 2a-d)

A 64-year-old man was admitted with the symptom of right upper quadrant pain for one month.

On admission the liver was palpated 11 cm below the right costal margin. Liver function test was slightly abnormal (alkaline phosphatase 125 IU/L (normal range: 30-115 IU/L), γ -glutamyl transpeptidase 105 IU/L (normal range: 0-30 IU/L), serum glutamic oxaloacetic transaminase 57 IU/L (normal range: 8-30 IU/L), HBsAg, antiHBs and Anti HBe were negative. Serum AFP was more than 30300 IU/ml. Chest roentgenogram findings were normal. Abdominal CAT scan disclosed huge mass

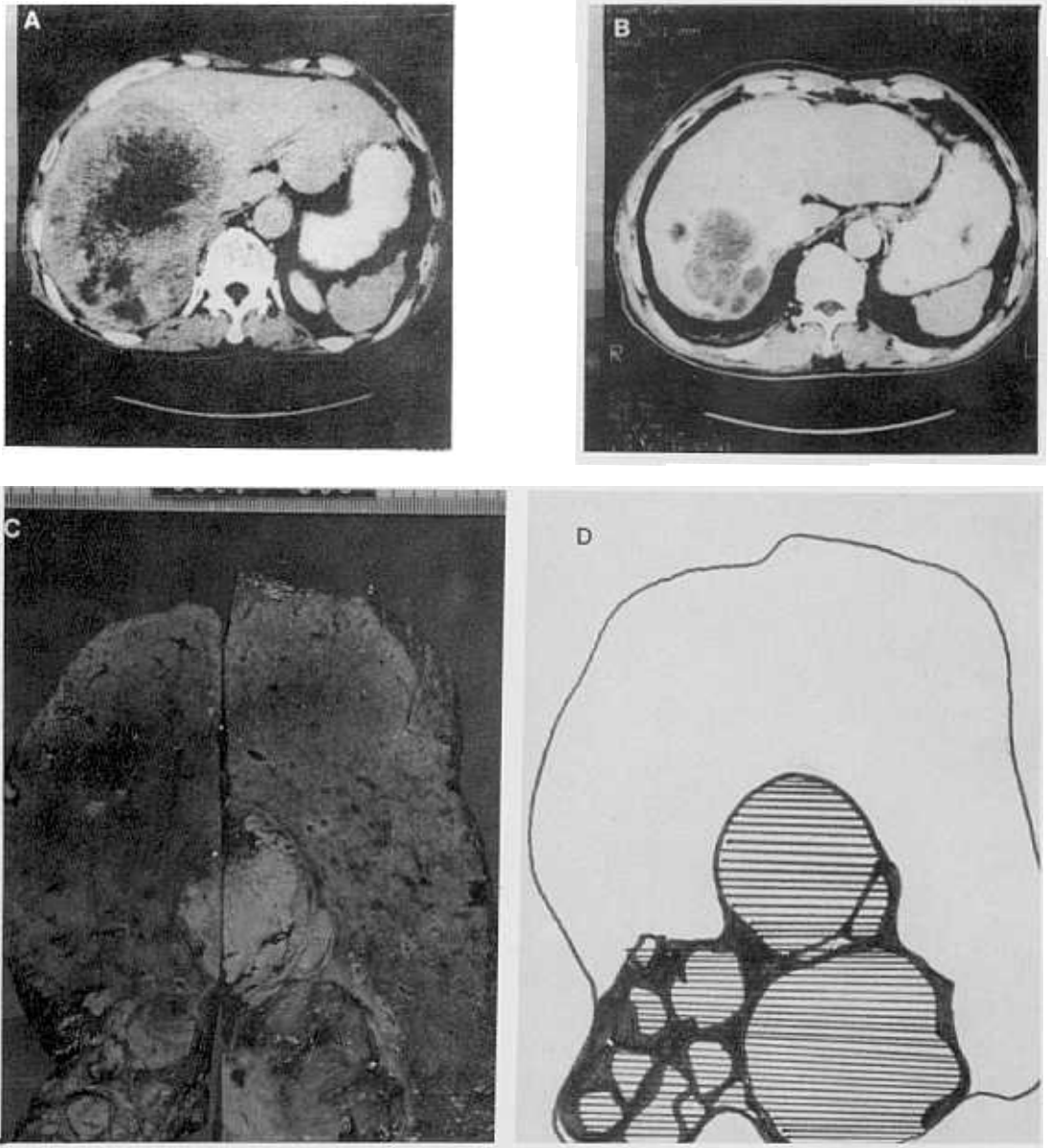


Fig. 2. Case of complete tumor necrosis (case # 1):

A. Pretreatment (RT.HT) CAT scan discloses huge mass with central necrosis in the right lobe of the liver.

B. Previously shown tumor mass is remarkably shrunk in the posttreatment CAT scan.

C & D. Gross view of resected specimen shows round yellowish mass in the center of the specimen with 100% necrosis (shaded areas) and fibrous capsule (black line).

lesion accompanying central necrosis which replaced entire right lobe of the liver with pedunculation. The mass was lobulated, expansile in growth pattern and sized 11×16×13 cm. On angiogra-

phic imaging the tumor appeared to be hypervascular mass. Transhepatic arterial embolization was attempted but failed due to difficulty in the superselection of vessels.

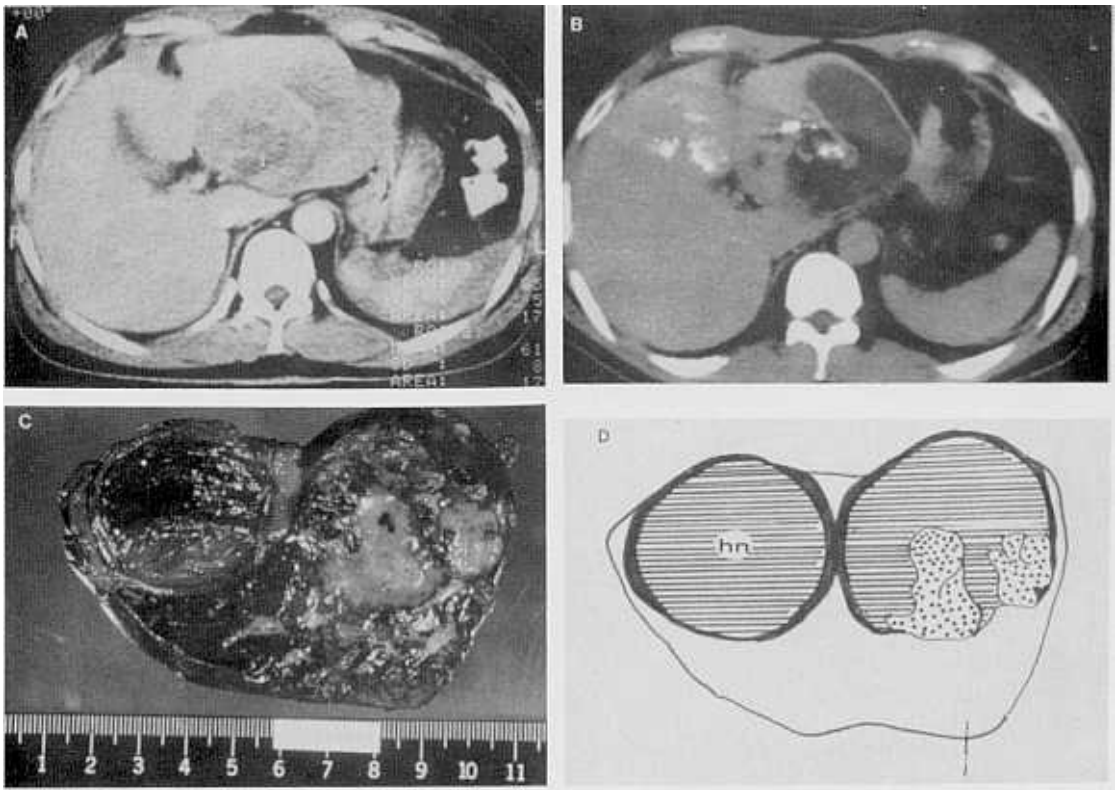


Fig. 3. Case of incomplete tumor necrosis (case #3):

- A. Pretreatment CAT scan shows tumor mass in the left lobe of the liver.
- B. On posttreatment CAT scan, there is no change in the tumor size but the radiodensity in a part of the tumor changed to low density which means necrosis.
- C & D. Gross view of the resected specimen shows tumor mass with 80 % necrosis (shaded area) and residual tumor cells (black dots). Adjacent areas of hemorrhagic necrosis (hn) which coincides with the low density area in the posttreatment CAT scan.

Then combined RT and HT was started. In the first session temperature measurement was performed; the temperature at the 7 cm depth of the tumor was maintained between 42.5°C and 42.7°C for 30 minutes and thermal mapping, which was done just before the heating finished, showed relatively homogeneous temperature profile within the tumor; the temperature in the adjacent normal liver was lower than that in the tumor. The patient tolerated well the entire treatment course without any complication.

Upon completion of the treatment, the liver was still palpable with reduced size, 8 cm below right lower costal margin, and there was slight improve-

ment in pain. Three months after the treatment previously noted, right upper quadrant pain disappeared, there was a weight gain of about 5 Kg, the liver was no longer palpated, and a follow-up CAT scan showed marked regression of the tumor, only 5×7.5×5 cm in size. Serum AFP level decreased from the initial level of more than 30300 IU/ml to 6.7 IU/ml. Four months after the treatment he underwent surgical resection.

The surgical specimen showed two masses; 4×3.5×3.5 cm and 4.2×3.2×3.2 cm, respectively. Each one had thick fibrous capsule containing yellowish-white muddy necrotic material intermingled with hemorrhage. Viable tumor cell was not found

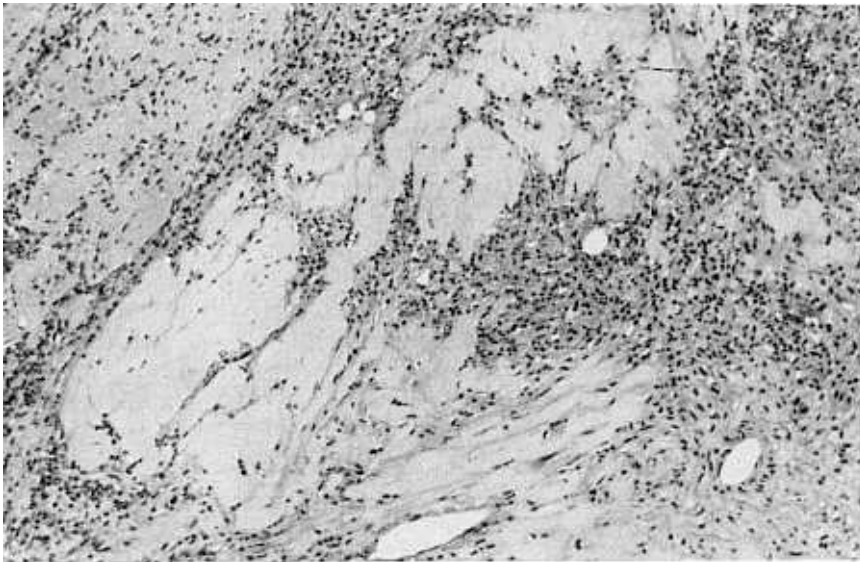


Fig. 4. Histologic changes in tumor capsule includes extensive hyalinization of the collagen fiber, infiltration of foamy histiocytic cells, atypical proliferation of fibroblast, and deposition of hemosiderin which findings are changes of radiation effect.

through close microscopic examination of the specimen.

After the surgical resection, AFP has been less than 3 IU/ml and the patient's general condition is thus far excellent.

Patients with incomplete tumor necrosis
(case # 2, 3 & 4, Fig. 3a-d)

Case #2, A 53 year-old woman, was diagnosed with HCC with a huge 8×10×13 cm sized mass in a CAT scan. Liver function was slightly abnormal only in alkaline phosphatase (215 IU/ml); HBs Ag and antiHBs were both positive; AFP was more than 30300 IU/ml. Chest PA showed chronic bronchitis in both lower lung fields. On angiography the tumor was hypervascular, but transhepatic arterial embolization failed due to severe redundancy of the vessels.

Soon combined RT and HT was done with good toleration. After the treatment AFP decreased to 1418 IU/ml, and a follow up CAT scan disclosed a tumor mass of reduced size, 6×4×4 cm. Systemic chemotherapy was followed; first 2 cycles with 5-FU, adriamycin, and mitomycin C then switched into 5-FU plus DDP for another 4 cycle due to the toxicity. Then AFP elevated again upto 22038 IU/ml with no significant change in tumor size noted in

a follow-up CAT scan. Surgical resection was performed 6 weeks after the last cycle of chemotherapy.

Surgical specimen showed a 5×2.5×2.5 cm sized, well-encapsulated mass. On cut section, the mass consisted of a yellowish-tan friable nodule, 2 cm in diameter, which was surrounded by a yellowish-white, ill-defined fibrotic and necrotic area. It infiltrated the surrounding liver parenchyme but capsule was intact. Microscopic examination showed persistent HCC cells, partly solid and partly trabecular in growth pattern with multifocal hemorrhagic necrosis which occupied approximately 40% of the entire volume. Interlobar non-cirrhotic fibrosis with partial septum formation was also found in adjacent liver parenchyme.

Since then AFP has been maintained at a level of less than 3 IU/ml; she has been disease-free for 1 year 10 months.

Case # 3, A 56-year-old man and case # 4, 46-year-old woman, with 12×9×7 cm and 8×8×8 cm sized massive type tumor, respectively, were both recommended for surgical resection but at first they refused.

Liver function was normal in case # 3 and slightly abnormal in case # 4 (alkaline phosphatase 124 IU/L, SGOT 73 IU/L, SGPT 60 IU/L, and rGT 90

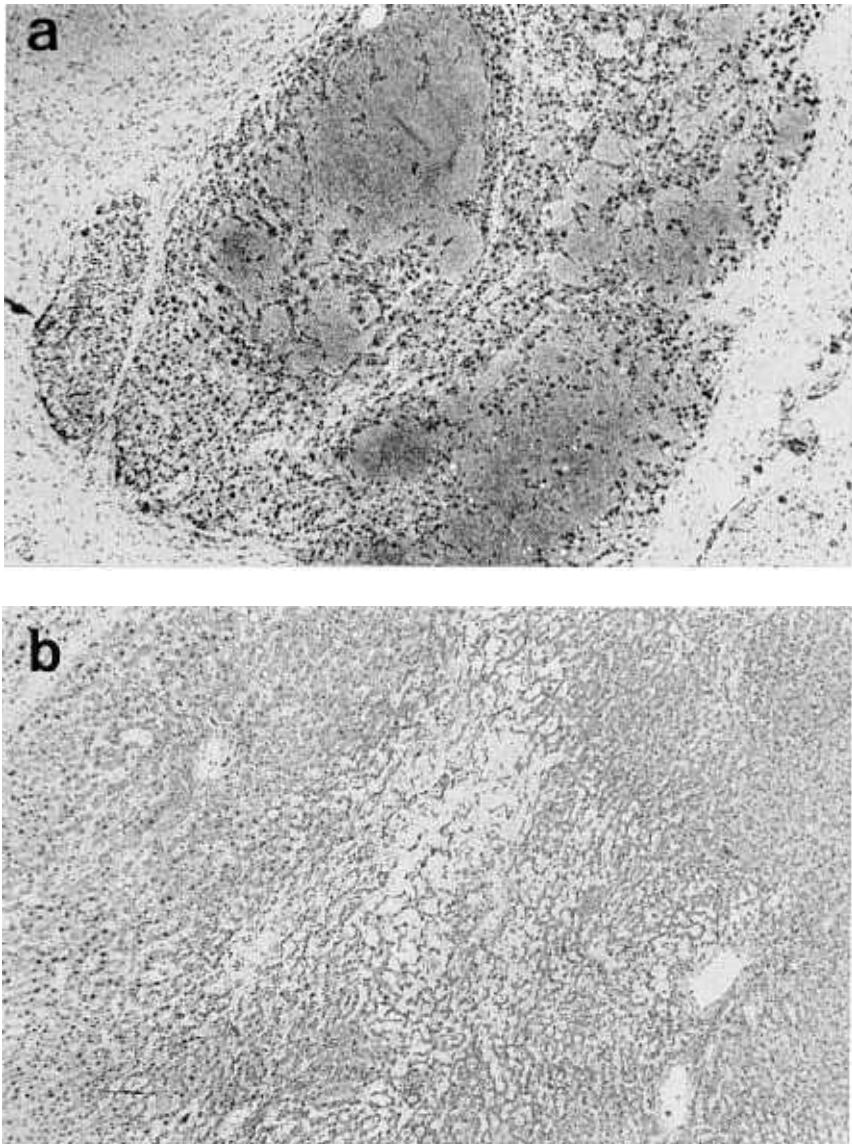


Fig. 5. Common histologic change in both tumor (a) and normal liver tissue (b) following combined RT.HT was cystic dilatation of sinusoid and congestion.

IU/L). AFP was negative in case # 3 and in case # 4, 1404 IU/ml.

Chemoembolization with 40mg adriamycin mixed with lipiodol and gelfoam were tried in both patients but was successful only in case #4. Soon combined RT and HT was started; case # 3 tolerated it very well; case # 4 showed poor tolerance to heat and experienced subcutaneous fat necrosis

over the right costal margin as a complication relating to capacitive type hyperthermia but that was recovered soon.

Upon completion of combined treatment, follow-up CAT scan showed a remaining tumor mass with reduced size; this encouraged the patients to accept surgery. Surgical resection was done 1 wk after the completion of the combined RT and HT in

both patients.

In case # 3, surgical specimen showed two closely attached but well-demarcated masses; 5×5×5 cm one with variegated surface consisted of yellowish necrosis, hemorrhagic area and remaining gray-white soft tissue; while the smaller one, 4×2×2 cm, showed totally hemorrhagic necrosis resembling hematoma. Microscopic examination revealed persistent tumor cells with prominent nuclear polymorphism and cytoplasmic fatty vacuoles. Marked peliosis was also found, and surrounding liver parenchyme was accompanied with partial congestion without cirrhotic change.

In case # 4, well demarcated lobulated mass was shown in the surgical specimen. Its size was 8×8×8 cm and the cut surface was nearly totally replaced by bright yellowish confluent necrotic area. On microscopic examination persistent tumor cells were shown with prominent pseudoglandular pattern and surrounding liver parenchyme was cirrhotic with macronodular type.

Case #4 is still alive after 5 months while case # 3 has survived for 15 months.

DISCUSSION

Since combined RT and HT has been applied to the treatment of advanced HCC in our Institute, more than 100 patients have been treated with this protocol. The treatment result of 30 patients in the early period has been reported; shrinkage of tumor mass of more than 50% of initial volume, partial response, which measured by CAT scan, was seen in 12 out of 30 patients (40%) and median survival, calculated from the first day of the treatment, was 11 months in the patients who showed partial response (Seong et al. 1989). One case of complete disappearance of the tumor mass, which was assessed by CAT scan and subsequent peritoneoscopic biopsy, has been discussed in another report (Suh et al. 1988).

However, several important questions remain to be answered; Does clinically assessed tumor response equal histological tumor response? What are the histological changes in the tumor following combined RT and HT? Are there any significant changes in the surrounding liver tissue; if so, what are the changes?

From this study it is clearly shown that combined RT and HT can induce considerable extent of necrosis of tumor cells and even complete necrosis. An interesting point is that, even in the histologi-

cally complete response case, there still remained residual tumor mass although its size is markedly reduced in preoperative CAT scan. Hence it can be assumed that some of the partial response cases which were evaluated by imaging might have more than a partial response. This dramatic tumorlytic effect of combined RT and HT was accompanied by a sharp decrease of serum AFP from 30300 to 6.7 IU/ml.

The histopathology of hepatic radiation injury has been described by Ogata et al. (1963) and by Reed and Cox (1966). In both reports the most prominent abnormalities were vascular injury, particularly in the small branches of hepatic veins with denudation of endothelium, the appearance of a fibrillar deposit within the vein lumen, and progression to the partial or complete obliteration of veins by dense collagenous tissue. The other changes in the liver were similar to those which were observed in hepatic venoocclusive disease (Budd-Chiari Syndrome); distention of sinusoids with packed erythrocytes predominance in the central vein region of the lobule, with atrophy and sometimes complete disappearance of hepatic parenchymal cells near the lobule centers. However, these changes appeared to be reversible.

The histological changes of the liver following hyperthermia were first described in a report of autopsy finding for the patients who died of heat stroke (Fajardo 1984) or fever therapy (Gore and Issacson. 1949); vacuolization within the hepatocyte and liver cell necrosis appeared with 60 hours after systemic hyperthermia and was followed by liver cell regeneration after seven days (Gore and Issacson. 1949). In a report by Kew et al. (1970) liver cell necrosis, sinusoidal congestion, and dilatation of portal vein were observed in the liver of the patients who died of heat stroke, while those changes were reversible in those patients who survived. Skibba and Condon (1983) and Akuta et al. (1988) reported that there was not any irreversible liver cell change between 41°C and 41.5°C in the rabbit's liver which was heated by interstitial hyperthermia. A similar finding was reported by Brauer et al. (1963). In a recent report by Suh et al (in press) liver damage with 41°C heating was trivial, while irreversible changes including congestion of the sinusoids, dilatation of central and portal vein, and finally liver cell necrosis were appeared when the liver was heated at higher than 42°C. Furthermore the frequency and severity of the liver damage seemed to increase when hyperthermia was combined with radiation.

In our cases we could heat the tumor up to 42.7°C (Fig. 1); It is believed that the interaction of heat and radiation lead to complete tumor necrosis in case #1, because it is not possible that either radiation alone of 3060 cGy or heat alone between 41°C and 42.7°C can cause complete tumor necrosis of such a large HCC mass over 16cm in diameter. It is hard to say that these histologic changes were solely due to hyperthermia or radiation, because the two modalities were combined and both hyperthermia and radiation can cause similar histologic changes in the liver, including dilatation of sinusoids, congestion of vessels, and also coagulative necrosis, which were also frequently seen in our cases. Changes seen in the tumor capsule were those which were commonly observed after irradiation. However, those histologic changes which were seen in our cases are rarely possible with 3060 cGy of radiation alone. Hence, interaction of the two modalities probably would contribute to this kind of histological changes.

The histological changes in the nontumorous liver parenchyme adjacent to the tumor following RT and HT were our major concern. Although the radiation dose to the tumor and adjacent nontumorous hepatic tissue was limited to 3060 cGy, which can hardly cause radiation hepatitis, it was thought that the addition of HT might induce liver tissue injury as well as potentiation of tumoricidal action of radiation. In our study, there was cystic dilatation of sinusoids with congestion in all cases. Other findings such as infiltration of inflammatory cells, noncirrhotic septation, proliferation of the bile duct, and fatty changes were also observed but were compatible with the usual findings frequently seen in the area beyond the space occupying lesion in the liver. Therefore, our study showed that combined RT and HT did not cause fatal histologic change on the nontumorous adjacent liver tissue. there may be many explanations for this. One of possible reasons might be differential heating between normal tissue and tumor. Under the same heating condition temperature rises much more in the tumor than in normal tissue due to the different physiology of the vascular system: i.e., neovasculature in tumor that has immature structure without neurovascular control according to the change in temperature (Emami et al. 1981). Furthermore rich vasculature in normal liver tissue might prevent temperature increase by increasing blood flow. That was also documented in the thermal distribution in case #1. As a matter of fact, histological change in hepatic tissue, mentioned in the earli-

er part of this report, is based on the assumption that the temperature in normal tissue rises over 42°C, which is rarely possible in clinical practice.

Therefore, it is concluded that combined radiotherapy and hyperthermia can induce significant extent of coagulative tumor necrosis of HCC with nonsignificant minimal histologic changes in nontumorous normal liver tissue.

REFERENCES

- Akuta K, Jo S, Hiraoka M, Nishimura Y, Nagata Y, Takahashi M, Abe M: Histological changes of the normal liver by local hyperthermia part 2: Histopathological changes of the rabbit liver by local hyperthermia. *Jpn J Hyperthermic Oncol* 4(1) 1-8, 1988
- Brauer RW, Balam RW, Bond ME, Carroll HW, Grisham JW, Pessotti RL: Reversible and irreversible changes in liver at temperatures approaching critical upper level. *Fed Proc* 22: 724, 1963
- Emami B, Nussbaum GH, Hahn N: Histopathological study on the effects of hyperthermia on microvasculature. *Int J Radiat Oncol Biol Phys* 7: 343-348, 1981
- Fajardo LF: Pathological effects of hyperthermia in normal tissues. *Cancer Res(suppl)* 44: 4826s-4835s, 1984
- Falkson G, Moertel CG, Lavin P: Chemotherapy studies in primary liver cancer. A prospective randomized clinical trial. *Cancer* 42: 2149-2156, 1978
- Gore I, Issacson NH: The pathology of hyperpyrexia: Observations at autopsy in 17 cases of fever therapy. *Am J Pathol* 25: 1029-1060, 1949
- Grady ED, McLaren J, Auda SP: Combination of internal radiation therapy and hyperthermia to treat liver cancer. *South Med J* 76: 1101-1105, 1983
- Kew M, Bersohn I, Seftel H, Kent G: Liver damage in heat stroke. *Am J Med* 49: 192-202, 1970
- Loh JJK, Seong JS, Suh CO: Cooperative clinical studies of hyperthermia using a capacitive type heating device GHT-RF8, *Yonsei Med J* 30: 72-80, 1989
- Ogata K, Hizawa K, Yoshida M, Kitamuro T, Akagi G, Kogawa K, Fukuda F: Hepatic injury following irradiation-a morphological study. *Tokushima J Exp Med* 9: 240-251, 1963
- Reed JB, Cox AJ: The human liver after radiation injury. A form of venoocclusive disease. *Am J Pathol* 48: 597-612, 1966
- Sakurai M, Okamura J, Kuroda C: Transcatheter chemoembolization effective for treating hepatocellular cancer. *Cancer* 54: 387-392, 1984
- Sciarrino E, Simoneti RG, Moil SL: Adriamycin treatment for hepatocellular carcinoma. *Cancer* 56: 2751-2744, 1985
- Seong JS, Loh JJK, Suh CO, Kim GE, Han KH, Lee SI, Roh JK, Kim BS, Choi HJ: Combined radiotherapy

- and hyperthermia for nonresectable hepatocellular carcinoma. *J Kor Soc Ther Radiol* 7: 247-257, 1989
- Sitzmann JV, Order SE, Lkein JL: Conversion by new treatment modalities of nonresectable to resectable hepatocellular cancer. *J Clin Oncol* 5: 1566-1573, 1987
- Skibba JL, Condon RE: Hyperthermic isolation-perfusion in vivo of the canine liver. *Cancer* 51 : 1303-1309, 1983
- Suh CO, Loh JJK, Seong JS: Effect of radiofrequency hyperthermia on hepatocellular carcinoma. *J Kor Cancer Research Ass* 20 : 117-125, 1988
- Suh CO, Moon SR, Seong JS, Chu SS, Park CI : Effects of radiofrequency induced local hyperthermia and radiation on normal rabbit liver. *Yonsei Med J* (in press)
- Vogel CL, Bayley AC, Brooker RJ: A phase II study of adriamycin (NSC 123127) in patients with hepatocellular carcinoma from Zambia and the United States. *Cancer* 39: 1923-1929, 1977
- Yamada R, Sato M, Kawabata M: Hepatic artery embolization in 120 patients with unresectable hepatoma. *Radiol* 148: 397-401, 1983
- Yoo HS, Park CH, Suh JH: Hepatocellular carcinoma: Treatment with a radioiodinated fatty acid ester. *Yonsei Med J* 9 : 166-175, 1988
-