

## Roux-en-Y End-to-Side Esophagojejunostomy with Stapler after Total Gastrectomy

Choong Bai Kim<sup>1</sup>, Kwang Wook Suh<sup>2</sup>, Jang Il Moon<sup>1</sup> and Jin Sik Min<sup>1</sup>

*One hundred gastric cancer patients who underwent total gastrectomy and Roux-en-Y, end-to-side esophagojejunostomy by using stapling devices were analyzed with regard to their operative results. The median time required for the anastomosis was 18 minutes (range of 15 to 45 minutes). A cartridge of 25 mm in diameter was preferred (85% of 25 mm vs. 15% of 28 mm). In 92 patients, procedures were uneventful. Intraoperative problems happened in 8 patients: Two misfirings of stapler due to mechanical problems, in 6 patients, doughnut tissues were incomplete. Mechanical problems were solved by a change of the stapler and for incomplete doughnut tissues, anastomosis was simply reinforced (2 cases) or reanastomosed with restaplings (4 cases). Anastomotic leakage occurred in 2 patients but it was seen only in radiological studies. During the follow up period, two cases of anastomotic stricture were found and they were treated with endoscopic dilatations. There was no operative mortality nor other complication. In addition, routine use of the Levin tube after total gastrectomy was appraised by comparing postoperative courses. Twenty patients were randomly divided into two groups; for 10 patients the Levin tube was removed at the recovery room and for another 10 patients the Levin tube was indwelled until peristalsis returned. Timing of the tube removal did not affect the duration of the hospital stay and starting day of oral intake. We think that the stapler, when properly used, can facilitate the esophagojejunostomy safely and routine use of the Levin tube after total gastrectomy may be unnecessary.*

**Key Words:** Total gastrectomy, esophagojejunostomy, stapler

Esophagojejunostomy after total gastrectomy is a time-consuming procedure and has a risk of several dreadful complications such as leakage or stricture. Stapled anastomosis has facilitated the procedure and is now regarded as a standard technique for reconstruction of the digestive tract after total gastrectomy. Since 1988, we have also performed nearly all the cases of esophagojejunostomy by using the EEA stapler and manipulating the stapler is now regarded as an ordinary procedure in our institution. In

the present study, we present the result of experience of stapled esophagojejunostomy after total gastrectomy.

### PATIENTS AND METHODS

From January 1987 to June 1992, 520 patients underwent total gastrectomy for gastric cancer in the Department of Surgery, Yonsei University Hospital. Among them, 100 patients who underwent esophagojejunostomy by one surgeon (C.B.K) were evaluated for their operative results and complications. Of 100 patients, there were 57 males and 43 females. The median age was 55 (range of 34 to 71).

For mechanical suturing, EEA and TA de-

Received April 24, 1993  
Department of Surgery, Yonsei University College of Medicine<sup>1</sup> and Ajou University College of Medicine<sup>2</sup>

Address reprint requests to Dr. Choong Bai Kim, Department of Surgery Yonsei University College of Medicine, CPO Box 8044, Seoul 120-752, Korea

vices (United States Surgical Corporation, Norwalk, Conn) were used. The techniques employed were similar to those described by Walther *et al.* (1986).

### Operative procedure

All the anastomoses were performed through an abdominal incision and adequate resectional margins could be obtained. After the specimen is removed, an antecolic Roux-en-Y jejunal loop of 50 cm length is prepared. A purse string suture around the cut esophagus is performed with the purse string device (2-0 polypropylene suture). Choice of the cartridge, 25 mm or 28 mm, is based upon the patient's sex and the esophageal diameter. The cartridge without the anvil is then inserted through the open jejunal end and the central rod is made to emerge through a small scalpel incision in the antemesenteric wall 5 cm from the end of the loop. After attaching the anvil to the central rod, the for-

mer is introduced into the esophagus and the purse string suture is tied (Fig. 1A). After the opposition of the jejunum and the esophagus, the stapler is fired. The inverted two-layer anastomosis is completed. The instrument is then withdrawn and the patency of anastomosis is carefully palpated by an index finger through the open jejunal end. Care is taken to ensure that the two "doughnuts" (i.e., the resected tissue between the central rod and the circular knife; one from the esophageal and the other from jejunal wall) are intact. In the presence of intact rings, the open end of the jejunal loop is closed with the TA instrument (Fig. 1B).

### Postoperative treatment

The Levin tube is left with its tip just below the anastomosis. For evaluating whether the routine use of Levin tube after total gastrectomy is necessary, the Levin tube was removed at the recovery room in 10 patients

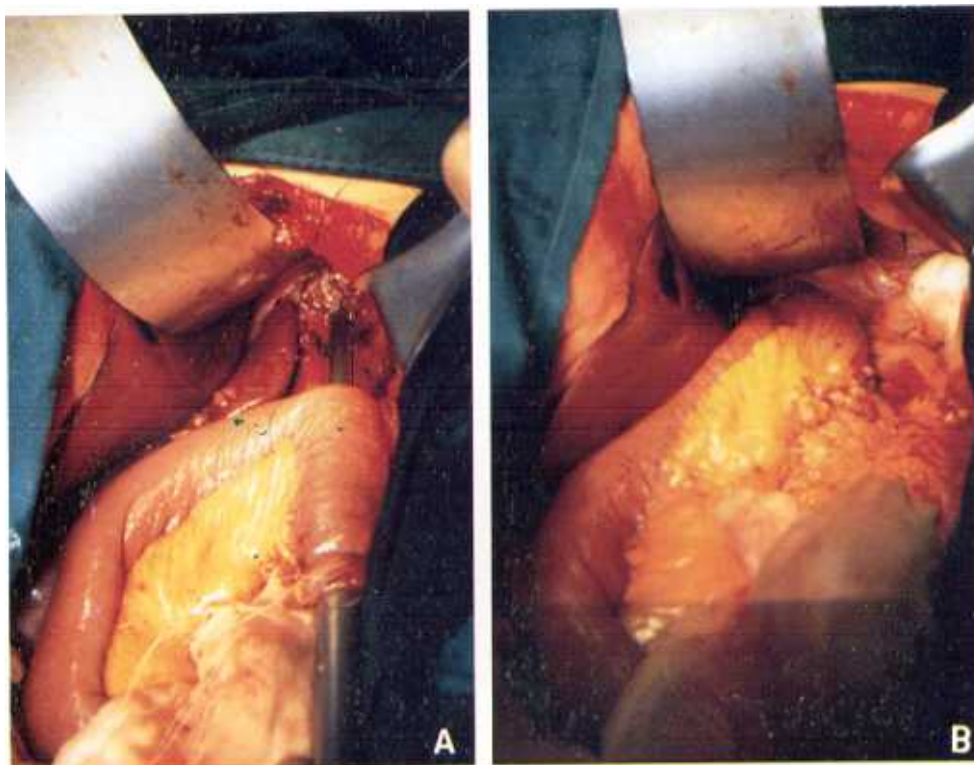


Fig. 1. Operative findings showing preparation (A) and completion (B) of anastomosis.

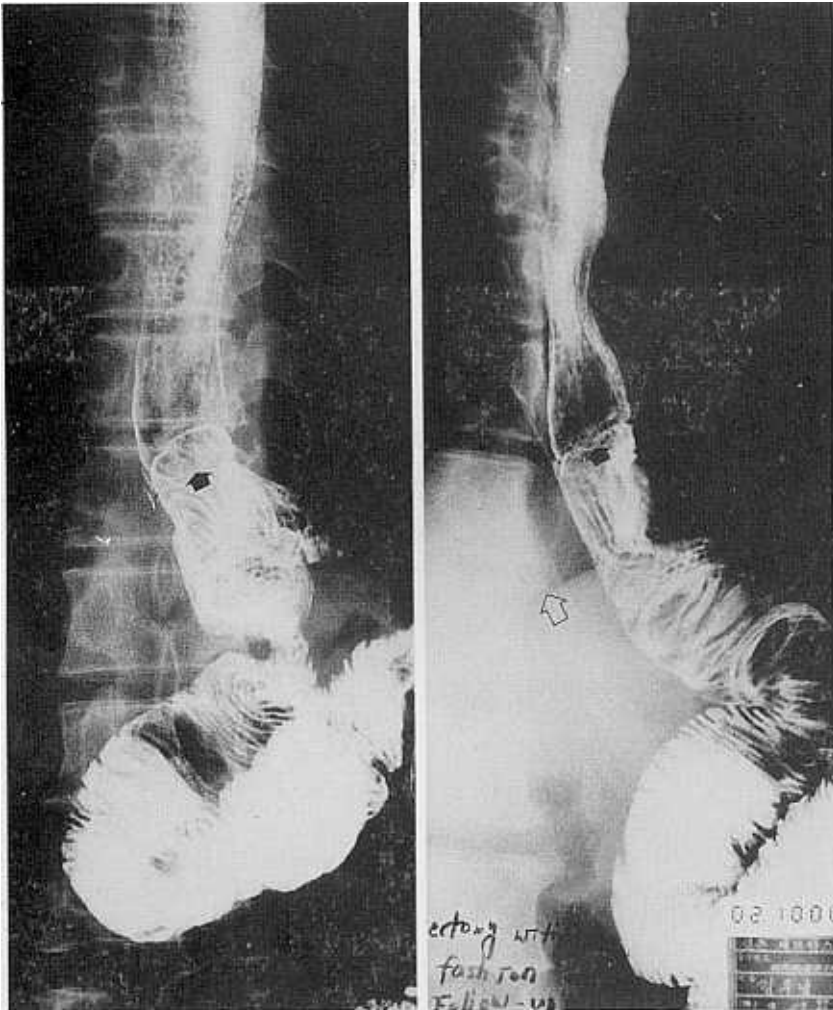
(group I) and their postoperative courses were compared with ten patients (group II) whose Levin tubes indwelled until the peristalsis returned. Statistical comparisons for significance were made by Wilcoxon's signed rank test and p values less than 0.05 were considered statistically significant.

Anastomosis is checked before starting oral intake with swallowing gentian violet dyes. If no leakage is observed through the drain, the patient starts to drink fluids. If the proce-

dures of anastomosis had been eventful, an upper GI series with water soluble contrast medium was performed although the test dyes did not emerge from the drain.

#### Follow-up

After the operation the patients are regularly examined by endoscopy and barium meal study. Each study is performed 3, 6, 9, and 12 months after the operation and every six months after that (Fig. 2).



**Fig. 2.** Barium meal study performed one year after operation. Staples (black arrow) are located on 6cm above the diaphragm (empty arrow). There is no stricture, nor other abnormality.

## RESULTS

The median time required for the anastomosis was 18 minutes (range of 15 to 45 minutes). A 25-mm cartridge was used in 85 patients and a 28-mm cartridge was used in 15 patients. Of the male patients, the 28-mm cartridge was used in 43 patients (75.4%) but in females, the 28-mm cartridge was used in only one patient (2.3%).

In 92 patients, the procedures were uneventful. Intraoperative problems happened in 8 patients. Two patients experienced trouble with a misfiring of the stapler (i.e., the stapler could not be fired) and their mechanical problems were solved by restaplings. In six patients, the doughnut tissues were incomplete (i.e., tissue fragment did not form a ring shape). Unless the esophageal ring was incomplete (4 cases), only reinforcing sutures of the outer coat of anastomosis were made, but in two cases whose esophageal rings were incomplete, reanastomosis by restapling was performed.

Anastomotic leakage occurred in two patients. Both anastomoses had been performed with the 28-mm cartridge and they had undergone a problem during the anastomosis. One patient had undergone tearing of the esophageal mucosa during the advance of the stapler, and the other patient had shown an incomplete doughnut tissue and had taken reinforcing sutures. Both showed minimal leakage of water-soluble contrast medium on radiologic study. The leakages were healed after 7 and 10 days of total parenteral nutrition therapy.

There was no other complication such as hemorrhage, wound problem or intraabdominal abscess (Table 1), and there was no mortality associated with the operation.

During the follow-up period, stricture of esophagojejunostomy not by recurrence, was documented in two patients. In both cases, the pediatric endoscopy (12 mm in diameter) could not be passed and they could hardly tolerate the soft diet. The strictures could be improved by episodes of the dilatation with balloon or Savary dilator.

The mean postoperative day when oral

**Table 1. Intraoperative problems and postoperative complications**

Intraoperative problem	
Misfiring of stapler	2
Incomplete doughnut	6
Postoperative complication	
Stricture <sup>1</sup>	2
Leakage	2
clinical <sup>2</sup>	—
radiological <sup>3</sup>	2
Anastomotic bleeding	—
Intraabdominal abscess	—
Wound infection	1

<sup>1</sup> denotes nonrecurrent benign anastomotic stricture, through which a pediatric endoscopy (12 mm in diameter) cannot be passed.

<sup>2</sup> denotes leakage of test dyes swallowed by mouth

<sup>3</sup> denotes leakage of water-soluble contrast medium on X ray film

**Table 2. Comparison of two groups by postoperative course**

	Group I (N=10)	Group II (N=10)	P value
Mean starting day of oral intake(days*)	4.0	4.3	<0.05
Mean Hospital stay(days*)	15.1	13.1	<0.05

Group I: Includes patients to whom Levin tubes are indwelled until peristalsis returns.

Group II: Includes patients whose Levin tubes are removed at recovery room.

\*, postoperative day

feeding started was 4.0 days in group I and 4.3 days in group II. The difference between groups did not reach statistical significance. The mean postoperative hospital stay was 15.1 days (range of 10 to 19 days) in group I and 13.1 days (range of 10 to 16 days) in group II. The difference between groups did not reach statistical significance (Table 2).

## DISCUSSION

Stapled anastomosis in gastrointestinal sur-

gery has some theoretical advantages over the sutured anastomosis. First, it can save total operating time (Chassin *et al.* 1978; Chassin *et al.* 1984; Tuchmann *et al.* 1985) and facilitate many difficult anastomotic procedures such as esophagojejunostomy or low rectal anastomosis. Second, the internal stapler joins two visceral walls with a fine wire staple that closes into a B-shaped configuration and small vessels within the loop of the B remain open to create the advantage of being viable tissue beyond the B (Chassin *et al.* 1984). The latter one is closely associated with anastomotic patency but also becomes a cause of anastomotic bleeding.

In spite of these advantages, a number of studies failed to prove that the complication rate after the stapled anastomosis was definitely lower than sutured anastomosis (Chassin *et al.* 1978; Chassin *et al.* 1984; Di Matteo *et al.* 1988; Hedberg *et al.* 1984; Latimer *et al.* 1975; Lowdon *et al.* 1982; Reiling *et al.* 1980). The Rate of anastomotic leakage after stapled esophagojejunostomy still ranges from 3% to 10% (Chassin *et al.* 1978; Chassin *et al.* 1984; Tuchman *et al.* 1985; Hedberg *et al.* 1984; Habu *et al.* 1989; Fujimoto *et al.* 1991) and stapled anastomosis enables a high, intrathoracic anastomosis, so leakage is more prone to be a lethal complication such as the posterior mediastinitis. We think this was probably due to misunderstanding and underestimation of the pitfalls of stapling procedure.

First, surgical principles of anastomosis, i.e., adequate blood supply, absence of sepsis, freedom from tension and adequately cleared serosal surfaces, is more strictly upheld in the stapled anastomosis. Because the staple wire is so fine and prone to tear through tissue, absence of tension is more important in a stapled anastomosis than in a sutured anastomosis (Roberts *et al.* 1991).

Second, correct and tight tying of the purse string suture around the esophageal end is an indispensable condition for secure stapled anastomosis. If too loose, the "doughnut" may be incomplete (Habu *et al.* 1989). If too much tissue is incorporated into the purse string suture or clearance of the serosal surface is inadequate, they may protrude outwards making anastomosis insecure. This pitfall is thought to be closely associated with intra-

operative problems in our series. Although Campion *et al.* (1984) have recommended putting a total circular ligature of the esophageal wall around the central rod instead of using a purse string suture, we think that a sufficient over and over suture around the circumference, eight to 10 bites, and making a tight surgical knot are enough to prevent the problem.

Third, the choice of an adequate size cartridge is important. With stapled anastomoses, anastomotic narrowing due to a stricture is a more common complication than leakage. An inverse relationship has been reported between the incidence of benign stricture and the size of the staple head (Muehrcke *et al.* 1989); the incidence of stricture with the 31-mm cartridge was 5.4%, 13.5% with the 28-mm cartridge, and 17% with the 25-mm cartridge. These suggest that a smaller anastomosis is more prone to the development of a stricture than a larger anastomosis. But it is dangerous to consider larger to be better because an oversized stapling head can cause more serious complications such as mucosal tearing and subsequent anastomotic leakage. Thus, choice of the largest cartridge that will not tear the esophageal mucosa is important. In our series, two cases of anastomotic leakage are thought to be chiefly due to an esophageal mucosal tearing rather than other technical errors. Mucosal tearing usually results from uneasy, repeated and forceful advances of an oversized head. Although two cases of the stricture along the anastomosis were probably due to the preference of the 25-mm cartridge, the stricture of anastomosis, as in our series, can be appropriately treated by dilatation with balloon.

As the experience of stapled anastomosis has been accumulated we have had a question about whether a routine use of postoperative nasogastric decompression was necessary. We have observed that trivial amount of intestinal fluids were gathered in the majority of the patients who underwent total gastrectomy. In our series, although their difference did not reach a statistical significance, the postoperative course was assessed to be more comfortable in 10 patients whose tubes were eliminated immediately after the operation than in 10 other patients to whom the Levin tube was left until the peristalsis

returned. This was chiefly due to improvement of a sore throat or inflammation of the upper airway and subsequent shortening of the hospital stay.

So routine use of the Levin tube after total gastrectomy is thought to be unnecessary and the tube may be eliminated as soon as possible unless there is profuse drainage of intestinal fluid or evidence of anastomotic leakage.

In summary, we performed 100 consecutive esophagojejunostomies with stapling devices without any serious complication and could save total operating time. We think that the stapler, when properly used, can facilitate the esophagojejunostomy safely and routine use of the Levin tube after total gastrectomy may be unnecessary.

## REFERENCES

- Campion JP, Grossetti D, Launoid B: Circular anastomosis stapler. An alternative to purse-string suture. *Arch Surg* 119: 232-233, 1984
- Chassin JL, Rifkind KM, Sussman B, et al.: The stapled gastrointestinal tract anastomosis: Incidence of postoperative complications compared with the sutured anastomosis. *Ann Surg* 188: 689-696, 1978
- Chassin JL, Rifkind KM, Turner JW: Errors and pitfalls in stapling gastrointestinal tract anastomoses. *Surg Clin North Am* 64: 441-459, 1984
- Di Matteo G, Cancrini A Jr, Palazzini G, et al.:

- Stapled suture in digestive tract surgery. *Int Surg* 73: 23-28, 1988
- Fujimoto S, Takahashi M, Edoh F, et al.: Stapled or manual suturing in esophagojejunostomy after total gastrectomy: A comparison of outcome in 379 patients. *Am J Surg* 162: 256-259, 1991
- Habu H, Kando F, Saito N, et al.: Experience with the EEA stapler for esophagojejunostomy. *Int Surg* 74: 73-76, 1989
- Hedberg SE, Helmy AH: Experience with gastrointestinal stapling at the Massachusetts General Hospital. *Surg Clin North Am* 64: 511-528, 1984
- Latimer RG, Doane WA, McKittrick JE, et al.: Automatic staple suturing for gastrointestinal surgery. *Am J Surg* 130: 766-771, 1975
- Lowdon IMR, Gear MWL, Kilby JO: Stapling instruments in upper gastrointestinal surgery: A retrospective study of 362 cases. *Br J Surg* 69: 333-335, 1982
- Muehrcke DD, Kaplan DK, Donnelly RJ: Anastomotic narrowing after esophagogastric anastomosis with EEA stapling device. *J Thorac Cardiovasc Surg* 97: 434-438, 1989
- Reiling RB, Reiling WA Jr, Bernie WA, et al.: Prospective controlled study of gastrointestinal stapled anastomoses. *Am J Surg* 139: 147-152, 1980
- Roberts P, Williamson WA, Sanders LB: Pitfalls in use of stapler in gastrointestinal tract surgery. *Surg Clin North Am* 71: 1247-1257, 1991
- Tuchmann A, Dinstl K, Strasser K, et al.: Stapling devices in gastrointestinal surgery. *Int Surg* 70: 23-27, 1985
- Walther BS, Oscarson JEA, Graffner HOL, et al.: Esophagojejunostomy with the EEA stapler. *Surgery* 99: 598-603, 1986