

# Endogenous *Aeromonas Hydrophila* Endophthalmitis in an Immunocompromised Patient

Hee Jin Sohn, MD, Dong Heun Nam, MD, Yeon Suk Kim, MD<sup>1</sup>, Hae Jung Paik, MD, PhD

*Department of Ophthalmology, Gachon University Gil Medical Center, Incheon, Korea*

*Department of Gastroenterology, Gachon University Gil Medical Center<sup>1</sup>, Incheon, Korea*

**Purpose:** To report a case of endogenous endophthalmitis due to *Aeromonas hydrophila* in a patient with distal common bile duct carcinoma and biliary sepsis.

**Methods:** A 72-year-old woman with distal common bile duct carcinoma, obstructive jaundice, diabetes mellitus, and hypertension had a 1-day history of blurred vision, redness, and eye discharges in the right eye. An ophthalmic examination showed no light perception vision, increased intraocular pressure, severe corneal edema, severe anterior chamber reaction, exudative membranes on the anterior lens surface, and severe vitreal reaction. There was no ocular history of trauma, infection, or surgery in either eye.

**Results:** Under the impression of endogenous bacterial endophthalmitis, immediate intraocular cultures and intravitreal antibiotic injections were performed, but the anterior chamber reaction, and the ultrasonogram findings were deteriorated. Evisceration was undertaken because of extrusion of the intraocular contents, and *Aeromonas hydrophila* was isolated by intraocular culture.

**Conclusions:** Endogenous endophthalmitis due to *Aeromonas hydrophila* is rare, but has a rapid clinical course and a poor prognosis, despite of prompt diagnosis and management.

*Korean Journal of Ophthalmology 21(1):45-47, 2007*

**Key Words:** *Aeromonas hydrophila*, Endogenous endophthalmitis, Immunocompromised

The genus *Aeromonas* consists of gram-negative, facultatively anaerobic, rod-shaped, oxidase-positive bacteria that are widely distributed in the aquatic environment. In humans *Aeromonas hydrophila* may cause traumatic wound infection, gastroenteritis, and septicemia, especially in immunocompromised hosts, but endogenous endophthalmitis caused by this agent is rare. Two reports of endogenous endophthalmitis have been described in immunocompetent patients.<sup>1,2</sup> However, to the best of our knowledge, this is the first case of endogenous endophthalmitis caused by *Aeromonas hydrophila* in an immunocompromised patient.

## Case report

A 72-year-old woman with distal common bile duct carcinoma, obstructive jaundice, diabetes mellitus, and hypertension was admitted to our gastroenterology department.

Two days after admission, ophthalmic consultation was sought to evaluate diabetic retinopathy. At initial examination, best-corrected visual acuity was 20/50 in both eyes with incipient cataract, but no sign of diabetic retinopathy. Moreover, there was no ocular history of trauma, infection, or surgery in either eye. Three days later, on day 5 after admission, the patient reported a 1-day history of blurred vision, redness, and eye discharge in the right eye. The patient was alert enough to have promptly reported her symptoms. Ophthalmic examination of the right eye showed a best-corrected visual acuity of no light perception, severe chemosis and injection of conjunctiva, and corneal haziness. Slit-lamp examination revealed an increased intraocular pressure of 30 mmHg, severe corneal edema, a shallow anterior chamber, severe anterior chamber reaction (many cells, flare, and RBCs), exudative membranes on the anterior lens surface, and a mid-dilated pupil (Fig. 1A). Fundus examination was obscured by severe vitreal reaction. A B-scan ultrasonogram showed moderate vitreous opacities (Fig. 1B). Ophthalmic examination of the left eye was unremarkable. Under the impression of endogenous bacterial endophthalmitis, immediate intraocular cultures (anterior chamber paracentesis 0.2 ml, vitreous needle aspiration 0.3

*Received:* February 17, 2006    *Accepted:* January 22, 2007

Reprint requests to Dong Heun Nam, MD, Department of Ophthalmology, Gachon Medical School, 1198 Guwol-dong, Namdong-gu, Incheon 405-760, Korea. Tel: 82-32-460-3751, Fax: 82-32-460-3358, E-mail: eyedawns@gilhospital.com

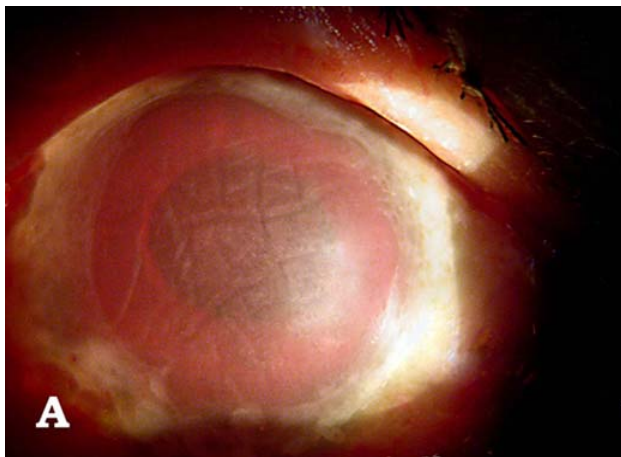


Fig. 1A. Slit-lamp photograph at initial presentation: Severe corneal edema, hyphema, exudative membranes on anterior lens surface, and mid-dilated pupil.

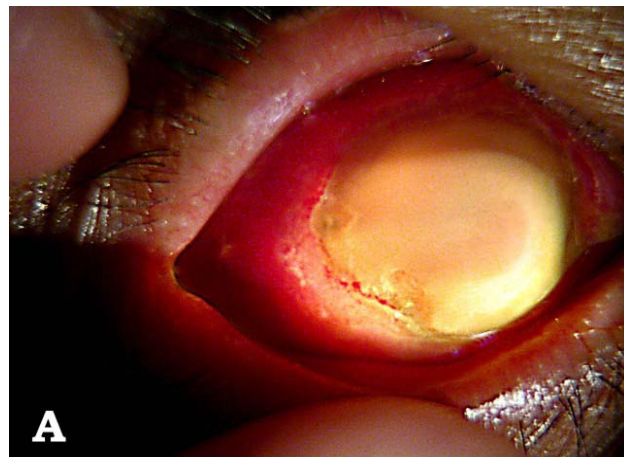


Fig. 2A. Slit-lamp photograph on the day 2 after intravitreal injections: Totally opaque cornea and inferior protrusion of the eyeball.

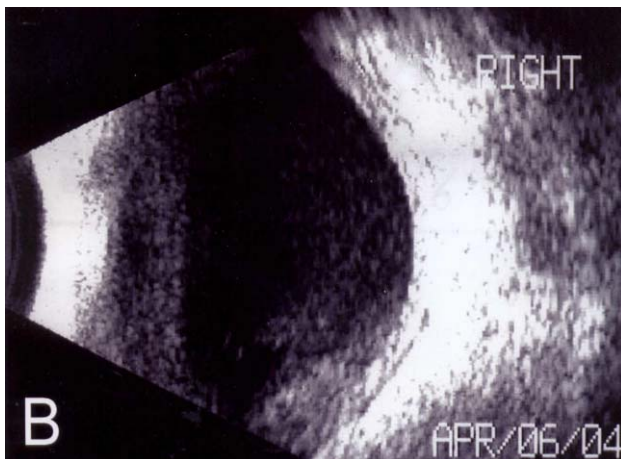

Fig. 1B. B-scan ultrasonograph at initial presentation: Moderate vitreous opacities.

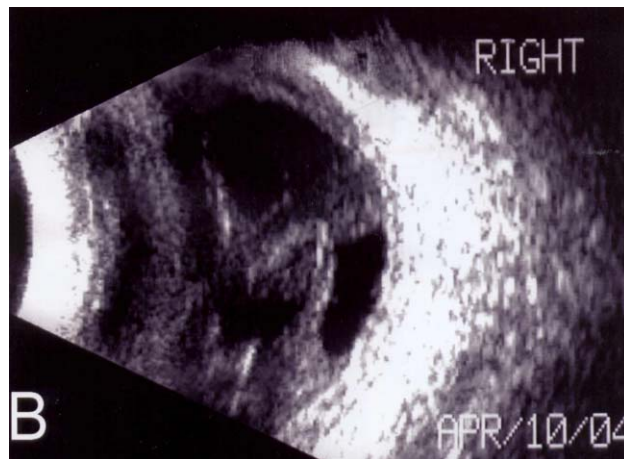

Fig. 2B. B-scan ultrasonograph on the day 2 after intravitreal injections: Increased and condensed vitreous opacities.

ml) and intravitreal antibiotic injections (vancomycin 1 mg/0.1 ml, ceftazidime 2 mg/0.1 ml) were performed with subsequent intravenous antibiotic therapy (Meropenem 2 g per day). Because of corneal haziness, it was impossible to treat the endophthalmitis surgically. Despite the intravitreal injections the anterior chamber reaction and ultrasonogram findings deteriorated, with inferior protrusion of the globe (Fig. 2). Intraocular Gram staining revealed 2+ gram-negative rods and 4+ *Aeromonas hydrophila* sensitive to ceftazidime by intraocular culture. Culture results from urine and bile juice were positive for *Acinobacter Iwoffi/baumannii* and *Enterobacter aerogenes*, respectively. However, blood culture results were negative for *Aeromonas hydrophila*. On day 8 after admission, percutaneous transhepatic biliary drainage was done to control total bilirubin, and on day 6 after intravitreal injections, limbus perforation occurred with extrusion of the intraocular contents (Fig. 3). Evisceration and Medpor<sup>®</sup> (porous polyethylene, Porex Surgical, College

Park, GA, U.S.A.) sphere implantation was done. On day 40 after admission, the patient was discharged from hospital with controlled jaundice, when her predicted survival was less than one year.

## Discussion

Endogenous bacterial endophthalmitis is a rare but potentially sight-threatening condition that occurs when organisms reach the eye via the bloodstream and cross the blood-ocular barrier. It accounts for only 2-6% of all cases of endophthalmitis.<sup>3</sup> Because prompt management is mandatory for saving the eye, clinicians must have a high index of suspicion of this rare but serious condition.

*Aeromonas* species are important pathogens of fish and a variety of animals, and can be pathogenic in patients infected by a contaminated wound or in the immunocompromised. *Aeromonas hydrophila* has been reported to cause

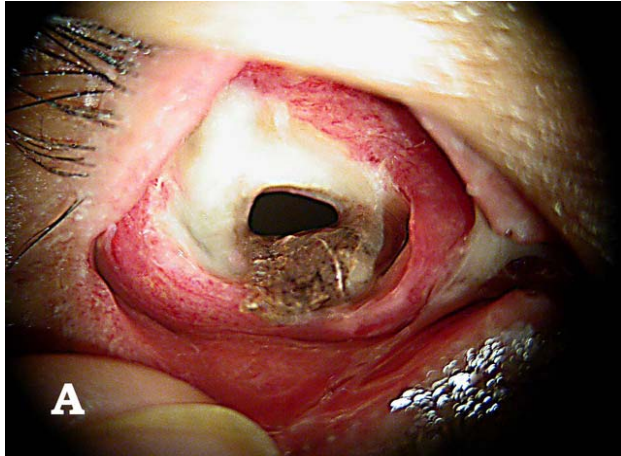


Fig. 3A. Slit-lamp photograph on the day 6 after intravitreal injections: Perforation of the eyeball.

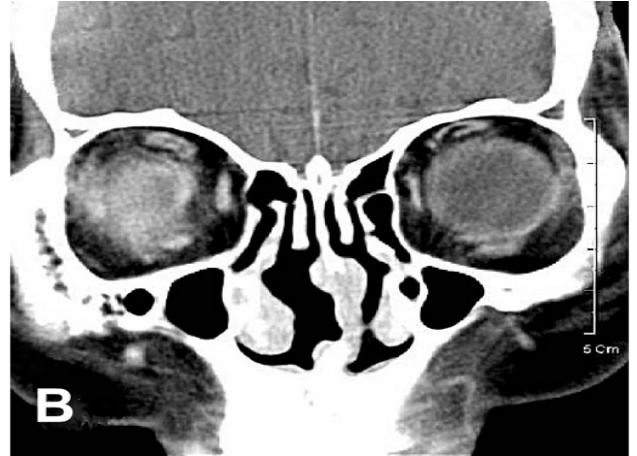

Fig. 3B. Computed tomograph on the day 6 after intravitreal injections: Contracted right eyeball with internal increased densities.

endophthalmitis after a penetrating injury,<sup>4</sup> post-traumatic keratitis,<sup>5</sup> contact lens-related keratitis,<sup>6</sup> and endogenous endophthalmitis.<sup>1,2</sup>

The presence of many RBCs in the anterior chamber is not typical of endophthalmitis, and has not been found in other reported cases of *Aeromonas hydrophila*.<sup>1,2</sup> However, in the present case we found hyphema. Although our patient was not overtly immunocompromised, risk factors such as old age, diabetes, hypertension, and malignancy may have predisposed a state of immune dysfunction. The patient had distal common bile duct carcinoma with obstructive jaundice, but the exact source of the infecting organism remains unclear. It is possible that *Aeromonas hydrophila* was contracted from a long indwelling catheter rather than direct spread from biliary sepsis. In common with two previous reports,<sup>1,2</sup> this case also showed a rapidly worsening course and a poor prognosis despite prompt diagnosis and management.

## References

1. Frieling JS, Rosenberg R, Edelstein M, et al. Endogenous *Aeromonas hydrophila* endophthalmitis. *Ann Ophthalmol* 1989;21:117-8.
2. Tamura T, Hida T. A case of endogenous *Aeromonas hydrophila* endophthalmitis. *Nippon Ganka Gakkai Zasshi* 2003;107:535-7.
3. Jackson TL, Eykyn SJ, Graham EM, Stanford MS. Endogenous bacterial endophthalmitis: a 17-year prospective series and review of 267 reported cases. *Surv Ophthalmol* 2003;48:403-23.
4. Cohen KL, Holyk PR, McCarthy LR, Peiffer RL. *Aeromonas hydrophila* and *Plesiomonas shigelloides* endophthalmitis. *Am J Ophthalmol* 1983;96:403-4.
5. Feaster FT, Nisbet R, Barber JC. *Aeromonas hydrophila* corneal ulcer. *Am J Ophthalmol* 1978;85:114-7.
6. Carta F, Pinna A, Zanetti S, et al. Corneal ulcer caused by *Aeromonas* species. *Am J Ophthalmol* 1994;118:530-1.