
Correspondence

Korean J Ophthalmol 2017;31(5):460-461
<https://doi.org/10.3341/kjo.2017.0032>

A Case of *Rothia mucilaginosa* Keratitis in South Korea

Dear Editor,

Bacterial keratitis is the most common cause of suppurative corneal ulceration, which can lead to visual impairment and frequently presents as an ocular emergency. *Rothia mucilaginosa* (*R. mucilaginosa*), previously known as *Stomatococcus mucilaginosus*, is a Gram-positive, coagulase-negative coccus of the family Micrococcaceae [1]. *R. mucilaginosa* is known as normal flora of the upper respiratory tract and oral cavity. It has been reported to be the causative agents of several diseases such as bacteremia, endocarditis, and urinary tract infection [1]. Recently, it is increasingly recognized as a pathogen associated with ocular infection. To our knowledge, only one keratitis case was reported with *Kocuria palustris* and *R. mucilaginosa* in vitamin A deficiency. We report a case of bacterial keratitis caused only by *R. mucilaginosa*, identified by 16S rRNA gene sequence analysis.

An 89-year-old man presented to Chonbuk National University Hospital with pain in his left eye after walking in mountains to pick up chestnuts 25 days ago. He had diabetes mellitus and underwent cataract surgery in both eyes 8 years before. At initial visit, visual acuity was light perception in his left eye. Slit-lamp examination showed severe ciliary injection, a 5.0 × 4.5 mm sized central corneal epithelial defect with deep stromal infiltration, and moderate anterior chamber reaction with hypopyon (Fig. 1A, 1B). A B-scan ultrasound of the fundus of the left eye was unremarkable. Under diagnosis of corneal ulcer, corneal scraping for culture was done immediately. He was

admitted and started on topical vancomycin 2.5% and ceftazidime 5% eye drops every hour as well as ofloxacin 0.3% ointment. He received intravenous flomoxef (1 g/day) simultaneously. On the 3rd day of hospitalization, corneal epithelial healing began, but anterior chamber reaction and stromal infiltration persisted. On the 8th day, as ocular inflammation gradually decreased, medical treatment was tapered. He was discharged 10 days after initial treatment with a remaining small epithelial defect and mild anterior chamber reaction. The culture of the ulcer grew catalase-positive, Gram-positive cocci forming white colonies. Finally, *R. mucilaginosa* was identified by 16s rRNA sequencing analysis. The criterion for gene sequence identification is homology >98% (ABI plasma 3730XL; Genotek, Kanata, ON, Canada). Two months after initial treatment, the corneal infiltrate and hypopyon were all resolved (Fig. 1C, 1D). Uncorrected visual acuity improved to 20 / 200.

R. mucilaginosa is a rarely detected bacterial species in ocular infection. Only four cases have been reported as follows: postoperative endophthalmitis in a 91-year-old man [2], keratitis in a 58-year-old woman with vitamin A deficiency [3], acute postoperative endophthalmitis after phacoemulsification in a 65-year-old woman [4], and late-onset bleb associated endophthalmitis in a 41-year-old man [5]. Evisceration was performed in two postoperative endophthalmitis cases. However, general outcomes due to ocular infection by *R. mucilaginosa* are unknown due to insufficient clinical reports. Although our case showed relatively good prognosis, unexpected infections can be a harbinger of serious corneal melting. Case reports since 1978 have implicated *R. mucilaginosa* in several systemic infections among patients who are usually immunocompromised [4]. In a previous *R. mucilaginosa* keratitis case, the patient suffered severe dry eye owing to an underlying vitamin A deficiency [5]. In our

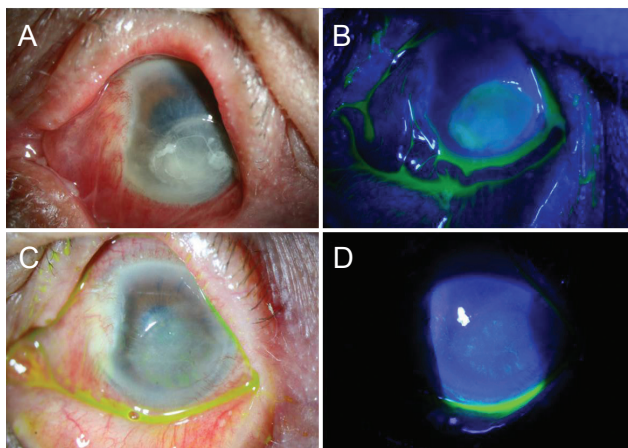


Fig. 1. Slit-lamp photographs of *Rothia mucilaginosa* keratitis at initial presentation. Anterior segment photograph shows severe ciliary injection and chemosis, about a 5.0×4.5 mm sized central corneal epithelial defect and stromal infiltration, Descemet's membrane folding, and hypopyon (A,B). Slit-lamp photographs 2 months after initial treatment. Anterior segment photographs show healed epithelial defect, faint corneal opacity, and peripheral neovascularization (C,D).

case, the patient was not immunocompromised and had no infectious disease history, other than old age. Although the precise cause remains unknown, one of the possible causes of keratitis is trauma to the cornea due to rubbing. We suspect the patient's hand had been contaminated with saliva suitable for transfer of *R. mucilaginosa* to the cornea.

R. mucilaginosa is a facultative anaerobic bacterium, but it can also grow under aerobic conditions [4]. However, it is not easy to identify *R. mucilaginosa* because this rarely isolated species has been often misidentified as streptococcus or coagulase-negative staphylococci [4]. In our case, it was misidentified as coagulase-negative staphylococci at first. We used two automated microbial identification devices called VITEK MS and VITEK2 (BioMérieux, Lyon, France). As the results from both were different, gene sequencing analysis was performed.

To our knowledge, this is the first case of corneal ulcer from *R. mucilaginosa* in South Korea. If there is difficulty treating an intractable corneal ulcer despite

using empirical antibiotics therapy, *R. mucilaginosa* has to be considered and molecular analysis is an accurate method to identify it.

Yong Yeon Song

Department of Ophthalmology, Chonbuk National University Medical School, Jeonju, Korea

Min Ahn, Nam Chun Cho, In Cheon You

Department of Ophthalmology, Chonbuk National University Medical School, Jeonju; Research Institute of Clinical Medicine, Chonbuk National University, Jeonju; Biomedical Research Institute, Chonbuk National University Hospital, Jeonju, Korea

E-mail (In Cheon You): you2ic@daum.net

Conflict of Interest

No potential conflict of interest relevant to this article were reported.

References

1. Ramanan P, Barreto JN, Osmon DR, Tosh PK. *Rothia* bacteremia: a 10-year experience at Mayo Clinic, Rochester, Minnesota. *J Clin Microbiol* 2014;52:3184-9.
2. Tan R, White V, Servais G, Bryce EA. Postoperative endophthalmitis caused by *Stomatococcus mucilaginosus*. *Clin Infect Dis* 1994;18:492-3.
3. Mattern RM, Ding J. Keratitis with *Kocuria palustris* and *Rothia mucilaginosa* in vitamin A deficiency. *Case Rep Ophthalmol* 2014;5:72-7.
4. Alvarez-Ramos P, Del Moral-Ariza A, Alonso-Maroto JM, et al. First report of acute postoperative endophthalmitis caused by *Rothia mucilaginosa* after phacoemulsification. *Infect Dis Rep* 2016;8:6320.
5. Oie S, Mochizuki K, Ishida K, et al. Case of late-onset bleb associated endophthalmitis caused by *Rothia mucilaginosa*. *J Infect Chemother* 2016;22:645-7.