

## Winged Scapula Caused by Rhomboideus and Trapezius Muscles Rupture Associated with Repetitive Minor Trauma : A Case Report

We experienced a rare case of winged scapula that was caused by the rupture of the rhomboideus major and the lower trapezius muscles without any nerve injury in a 12 yr old female after she had carried a heavy backpack. Electrodiagnostic study revealed that the onset latencies, amplitudes and conduction velocities were normal in the long thoracic nerve, the spinal accessory nerve and the dorsal scapular nerve. The needle EMG findings were normal as well. An explorative operation was performed and the rupture of the rhomboideus major and lower trapezius muscles was detected. Direct surgical repair of the ruptured muscle was carried out and the deformity was corrected. The anatomical and functional restoration was satisfactorily accomplished.

**Key Words :** Scapula; Muscle, Skeletal; Wounds and Injuries; Rhomboideus Muscle; Trapezius Muscle Shoulder

**Sam-Gyu Lee, Jae-Hyung Kim\*,  
So-Young Lee\*, In-Sung Choi,  
Eun-Sun Moon<sup>†</sup>**

Department of Physical Medicine & Rehabilitation,  
Research Institute of Medical Sciences, Chonnam  
National University Medical School & Hospital,  
Hwasun Hospital\*, Department of Orthopedic Surgery,  
Chonnam National University Medical School &  
Hospital<sup>†</sup>, Gwangju, Korea

Received : 7 April 2005  
Accepted : 20 June 2005

### Address for correspondence

Jae-Hyung, Kim, M.D.  
Department of Physical Medicine & Rehabilitation,  
Chonnam National University, Hwasun Hospital,  
160 Ilsim-ri, Hwasun-eup, Hwasun-gun,  
Jeollanam-do 519-809, Korea  
Tel : +82.61-379-8280, Fax : +82.61-379-7779  
E-mail : rehabkjh@hanmail.net

\*This study was financially supported by Regional  
Research Centers Program from the Ministry of Edu-  
cation and Human Resources Development.

## INTRODUCTION

Winged scapula is one of the more common scapulothoracic disorders, and it is caused by a number of pathologic conditions. It can be classified as primary and secondary; primary winged scapula may be due to neurologic injury, pathologic changes in the bone or because of periscapular soft-tissue abnormalities. Secondary winged scapula occurs as a result of glenohumeral and subacromial conditions, and it resolves after the primary pathologic condition has been addressed (1). Traumatic winged scapula is not a common malady, and only rarely has winged scapula been attributed to muscular injury. We report here on a patient with winged scapula that was caused by rhomboideus and trapezius muscles rupture associated with repetitive minor trauma.

## CASE REPORT

A 12-yr-old female presented to our outpatient department with a right winged scapula. Her height was 139 cm and her

weight was 38 kg. This condition abruptly developed after climbing a mountain for 2 hr with a rucksack/back-pack weighing about 20 kg at 2 months previous to her hospital visit. At a certain moment, she felt the drooping shoulder with a popping sound. She was born via spontaneous full-term vaginal delivery with a normal APGAR score. She had no specific family history of nerve or muscle diseases. Her growth and developmental history was nonspecific before the onset of winged scapula. Upon the physical examination, a winging deformity of the right scapula was noticed with the lateral deviation and upward rotation of the inferior angle, as observed on the erect neutral posture (Fig. 1A). This abnormality was not detected when both shoulders were abducted (Fig. 1B), but it was aggravated by shoulder flexion (Fig. 1C). The motor and sensory functions of the upper extremities were normal and no side to side differences were revealed. The deep tendon reflexes of the biceps and triceps muscles were normoactive and symmetrical. No significant muscle atrophy in the shoulder girdles and the upper extremities was observed. On the laboratory tests, the routine complete blood count with differential counting, erythrocyte sedimentation rate, C-

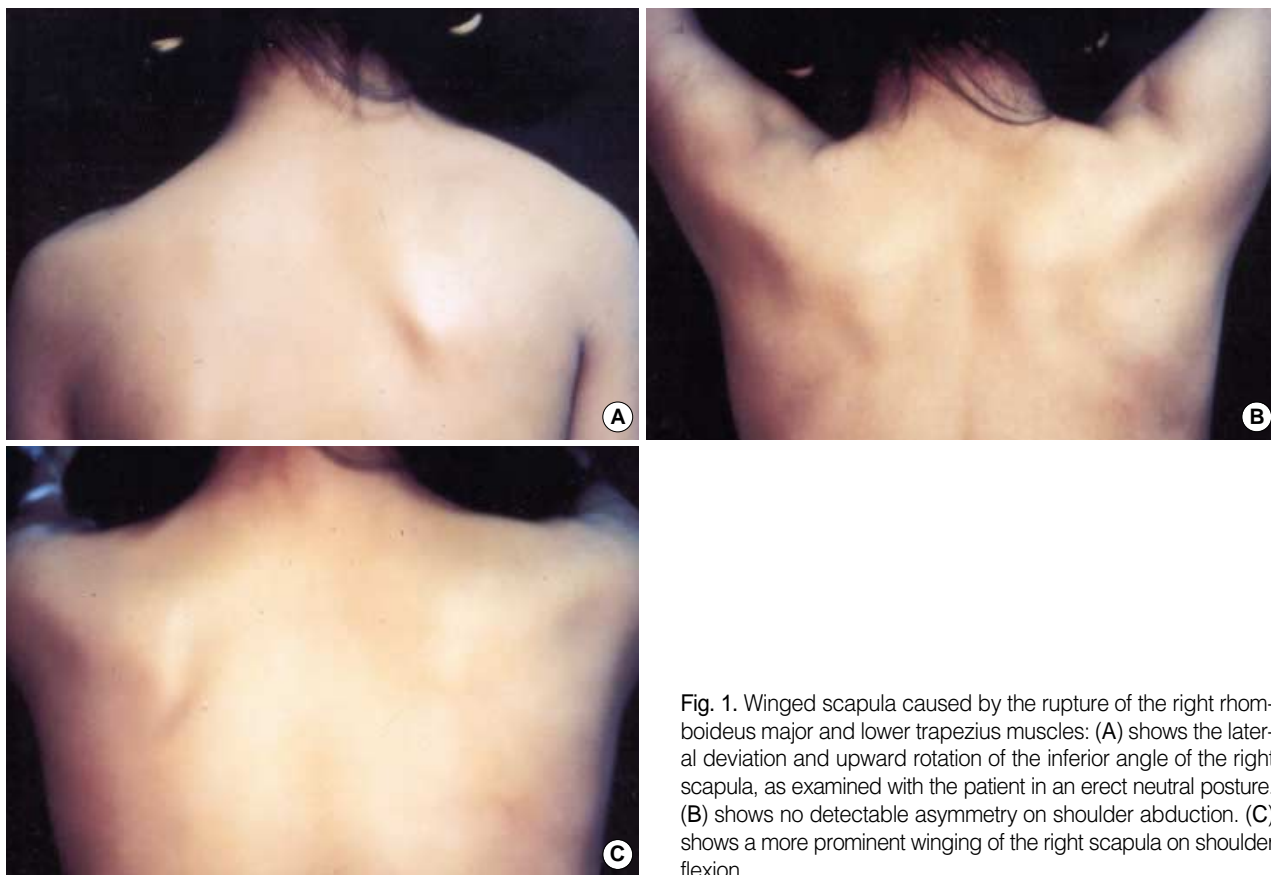


Fig. 1. Winged scapula caused by the rupture of the right rhomboideus major and lower trapezius muscles: (A) shows the lateral deviation and upward rotation of the inferior angle of the right scapula, as examined with the patient in an erect neutral posture. (B) shows no detectable asymmetry on shoulder abduction. (C) shows a more prominent winging of the right scapula on shoulder flexion.

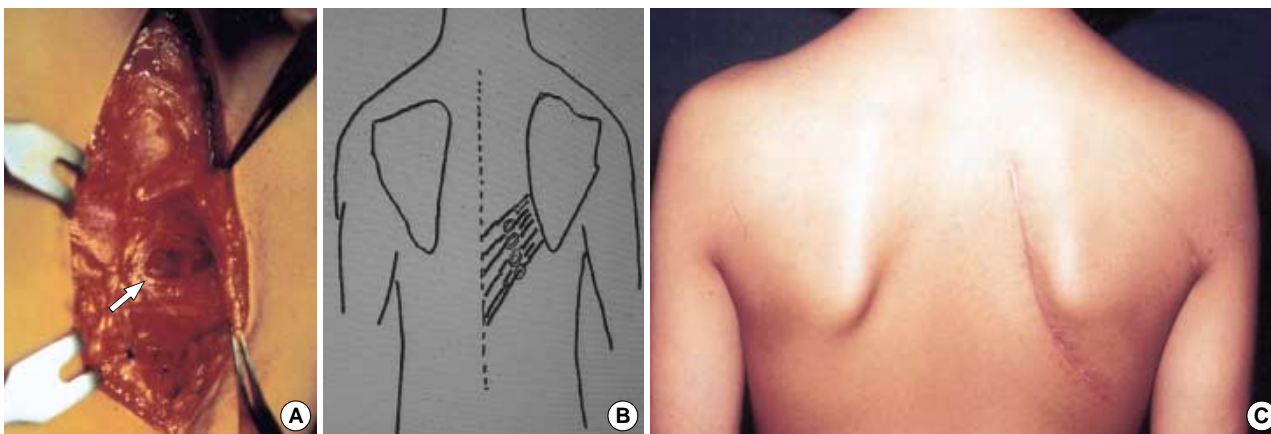


Fig. 2. (A) The intraoperative findings revealed the rupture of some portions of the right rhomboideus major and lower trapezius muscles (white arrow). (B) Postoperative illustration of the rhomboideus major and lower trapezius repair and reefing. (C) Postoperative findings showed restoration of scapular symmetry with the patient in a neutral erect posture.

reactive protein, rheumatoid arthritis factor and urinalysis were normal, and the muscle enzyme tests, including serum creatine kinase, lactate dehydrogenase and transaminase, were also normal. Simple radiological studies, including the chest posterior-anterior view, both the shoulder anterior-posterior views and the scapular view, were nonspecific except for the slight scapular asymmetry.

We examined the nerves by conducting an electrodiagnostic examination that included the long thoracic nerve, the dorsal scapular nerve and the spinal accessory nerves and the muscles including serratus anterior, levator scapula, trapezius and rhomboideus and so on; there were no definitive evidences that indicated any neuropathy or myopathy on electrodiagnosis.

When the pain and functional impairment persisted, surgical intervention then became appropriate. An explorative operation was done. A posterior longitudinal skin incision was made parallel to the vertebral border of the scapula. The subcutaneous tissue was divided. We can observed that the rhomboidius major was ruptured and trapezius lower thoracic bundle displayed thinning (Fig. 2A, B). The right scapula was unstable to the chest wall. Rhomboideus major and trapezius muscle repair and reefing were performed. After the muscle repair, the scapula was stable to chest wall at the time of the operation.

Postoperatively, she achieved the anatomical restoration of her right shoulder and she received rehabilitative treatment for 2 weeks including range of motion exercise of the shoulder and strengthening exercise of the rhomboideus muscles. On the follow up examination, at 2 months after the operation, there was no weakness or deformity of the affected shoulder and no pain nor limitation of shoulder motion. She was satisfied with the recovery of her shoulder function (Fig. 2C).

## DISCUSSION

Winged scapula is defined as a prominence of the medial border of the scapula and it is the most common scapulothoracic disorder (2). The causes of this condition are well-known, and they include brachial plexus injury (2, 3), isolated paralysis of the serratus anterior (4), fascioscapulothoracic muscular dystrophy (5) or injury to the long thoracic nerve that occurs during resection of the first rib for decompression of thoracic outlet compression syndrome (6). This condition can also develop due to subscapular osteochondroma (7). The position of the winged scapula depends on the specific nerve injury and the resulting pattern of muscle paralysis. The most common cause is the paralysis of the serratus anterior muscle that is innervated by the long thoracic nerve (8). The reported anecdotal cases of traumatic winged scapula were almost always related with traction injury to the long thoracic nerve (9-11), trapezius muscle paralysis that usually resulted from injury to the spinal accessory nerve (12, 13) and a disordered rhomboideus muscle that generally resulted from injury to the dorsal scapular nerve (14). Until now, winged scapula caused by direct rupture of rhomboideus and trapezius muscles, especially without scapular fracture, has not been reported on. In our case, we confirmed that the winged scapula was caused by the rupture of rhomboideus major muscle and the lower trapezius muscle, and this was most likely associated with the acute "popping" injury, based on the history and the operative findings. We thought that the winged scapula resulted from the downward traction force on the arm by her heavy back-pack and the repetitive minor trauma to the muscles.

A winged scapular in a patient with normal electromyograms was reported by Sanitate and Jurist in 1995 (15), and they insisted on the possibility of an undetected partial neu-

roparic lesion. They also said that muscular injury should be considered as a very rare cause of winged scapula. The same as their case findings, the electrodiagnostic findings of our case were nonspecific. We thought that there were two possibilities to explain these findings. The first, it takes some time for an abnormal electrical potential to appear (i.e., fibrillation and positive sharp wave) after nerve injury. Abnormal electrical potentials were seen both proximal and distal to the nerve injury 7 days after the injury, and they appeared in the proximal part by day 14 and in the distal part by day 21 (16). Our case had enough time not to observe abnormal findings on electrodiagnostic examinations. The second possibility would be a technical error of the electrodiagnostic examinations. Nardin et al. reported that the accuracy of electrodiagnostic testing was 91% in patients who presented with muscle weakness (17). Further, we could not rule out the possibility of inappropriate placing of the needles on the electrodiagnostic testing.

Postoperatively, the anatomical restoration was achieved and functional restoration of the right shoulder was satisfactorily accomplished by rehabilitative measures that included range of motion exercises for the shoulder and strengthening exercise for the rhomboideus and trapezius muscles.

## REFERENCES

1. Saeed MA, Gatens PF Jr, Singh S. *Winging of the scapula. Am Fam Physician* 1981; 24: 139-43.
2. Duralde XA. *Evaluation and treatment of the winged scapula. J South Orthop Assoc* 1995; 4: 38-52.
3. Fiddian NJ, King RJ. *The winged scapula. Clin Orthop Relat Res* 1984; 185: 228-36.
4. Wiater JM, Flatow EL. *Long thoracic nerve injury. Clin Orthop Relat Res* 1999; 368: 17-27.
5. Copeland SA, Levy O, Warner GC, Dodenhoff RM. *The shoulder in patients with muscular dystrophy. Clin Orthop Relat Res* 1999; 368: 80-91.
6. Wood VE, Frykman GK. *Winging of the scapula as a complication of first rib resection: a report of six cases. Clin Orthop Relat Res* 1980; 149: 160-3.
7. Danielsson LG, el-Haddad I. *Winged scapula due to osteochondroma. Report of 3 children. Acta Orthop Scand* 1989; 60: 728-9.
8. Connor PM, Yamaguchi K, Manifold SG, Pollock RG, Flatow EL, Bigliani LU. *Split pectoralis major transfer for serratus anterior palsy. Clin Orthop Relat Res* 1997; 341: 134-42.
9. Mah JY, Otsuka NY. *Scapular winging in young athletes. J Pediatr Orthop* 1992; 12: 245-7.
10. Schultz JS, Leonard JA Jr. *Long thoracic neuropathy from athletic activity. Arch Phys Med Rehab* 1992; 73: 87-90.
11. Gupta V, Posner B. *Trauma to the long thoracic nerve and associated scapula winging in a low-velocity rear-end automobile collision. J Trauma* 2004; 57: 402-3.
12. Wiater JM, Bigliani LU. *Spinal accessory nerve injury. Clin Orthop*

- Relat Res* 1999; 368: 5-16.
13. Kang HJ, Kim KD, Shin SJ. *Operative treatment of winged scapula: A report of 2 cases. J Korean Orthop Assoc* 1999; 34: 845-8.
14. Burdett-Smith P. *Experience of scapula winging in an accident and emergency department. Br J Clin Pract* 1990; 44: 643-4.
15. Sanitate S, Jurist KA. *Medical scapular winging in a patient with normal electromyograms. Orthopedics* 1995; 18: 292-3.
16. Keresi S, McComas A, Kowalchuk N, Stuart A. *Absence of fibrillation after muscle injury. Exp Neurol* 1983; 80: 645-51.
17. Nardin RA, Rutkove SB, Raynor EM. *Diagnostic accuracy of electrodiagnostic testing in the evaluation of weakness. Muscle Nerve* 2002; 26: 201-5.