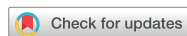

Images in This Issue

Infectious Diseases, Microbiology & Parasitology



A Paragonimiasis Mimicking Gastric Submucosal Tumor

Hyeri Seok ,^{1,2} Tae Sung Sohn ,³ and Kyong Ran Peck ²

¹Division of Infectious Diseases, Department of Medicine, Korea University Ansan Hospital, Ansan, Korea

²Division of Infectious Diseases, Department of Medicine, Samsung Medical Center, Sungkyunkwan University School of Medicine, Seoul, Korea

³Department of Surgery, Samsung Medical Center, Sungkyunkwan University School of Medicine, Seoul, Korea

OPEN ACCESS

Received: Aug 10, 2018

Accepted: Nov 12, 2018

Address for Correspondence:

Kyong Ran Peck, MD, PhD

Division of Infectious Diseases, Department of Medicine, Samsung Medical Center, Sungkyunkwan University School of Medicine, 81 Irwon-ro, Gangnam-gu, Seoul 06531, Korea.
E-mail: krpeck@skku.edu

© 2019 The Korean Academy of Medical Sciences.

This is an Open Access article distributed under the terms of the Creative Commons Attribution Non-Commercial License (<https://creativecommons.org/licenses/by-nc/4.0/>) which permits unrestricted non-commercial use, distribution, and reproduction in any medium, provided the original work is properly cited.

ORCID iDs

Hyeri Seok

<https://orcid.org/0000-0002-2032-9538>

Tae Sung Sohn

<https://orcid.org/0000-0002-9553-3234>

Kyong Ran Peck

<https://orcid.org/0000-0002-7464-9780>

Disclosure

The authors have no potential conflicts of interest to disclose.

Author Contributions

Conceptualization: Seok H, Sohn TS, Peck KR.
Data curation: Seok H. Investigation: Seok H.
Methodology: Seok H. Supervision: Sohn TS, Peck KR. Validation: Peck KR. Writing - original draft: Seok H. Writing - review & editing: Seok H, Sohn TS, Peck KR.

A previously healthy 49-year-old man was referred to the hospital for a symptomatic gastric submucosal tumor that was detected in the computed tomography (CT) during a health screening in July 2017 (**Fig. 1A**). There was incidental bronchopneumonia in the anterior segment of the right upper lobe on the chest CT (**Fig. 1B**). The submucosal septate cystic mass was removed by laparoscopic gastric wedge resection. During the operation, multiple tiny nodules were found in the entire peritoneum, omentum, transverse colon, and the liver surface (**Fig. 1C**). When the mass was dissected, brownish discharge poured out and an oval-shaped worm was found (**Fig. 1D-F**). The trematode was 5–6 mm long and 4–5 mm wide and was characterized by an oral sucker, a ventral sucker, a multilobed ovary, testes in the posterior region of the body, teguments covered with spines, and well-developed vitellaria (**Fig. 1G**). Multiple eggs (size, 50–60 µm) were observed in the lymph node which showed granulomatous inflammation with eosinophil infiltration (**Fig. 1H**). Additional history taking was taken. He is an office worker living in Seoul, and has eaten freshwater crabs several times. Considering the clinical and pathologic findings, praziquantel (25 mg/kg three times a day for two days) was prescribed after the diagnosis of paragonimiasis. Pulmonary paragonimiasis is sometimes mistaken for pulmonary tumors. However, in the case of extrapulmonary paragonimiasis, to suspect parasite infection is not easy before pathologic confirmation. Prior studies have reported some extrapulmonary paragonimiasis identified in the abdominal cavity.^{1–3} Here we report the first case of paragonimiasis mimicking gastric submucosal tumor.

This manuscript was written after receiving the patient's agreement of the publication including private clinical records and images.

REFERENCES

- Oh CR, Kim MJ, Lee KH. A case of intra-abdominal paragonimiasis mimicking metastasis of lung cancer diagnosed by endoscopic ultrasound-guided fine needle aspiration. *Korean J Gastroenterol* 2015;66(1):41-5. [PUBMED](#) | [CROSSREF](#)
- Kim MJ, Kim SH, Lee SO, Choi SH, Kim YS, Woo JH, et al. A case of ectopic peritoneal paragonimiasis mimicking diverticulitis or abdominal abscess. *Korean J Parasitol* 2017;55(3):313-7. [PUBMED](#) | [CROSSREF](#)
- Kim AY. Heterotopic paragonimiasis presented by intra-abdominal masses. *Korean J Gastroenterol* 2013;61(6):351-3. [PUBMED](#) | [CROSSREF](#)

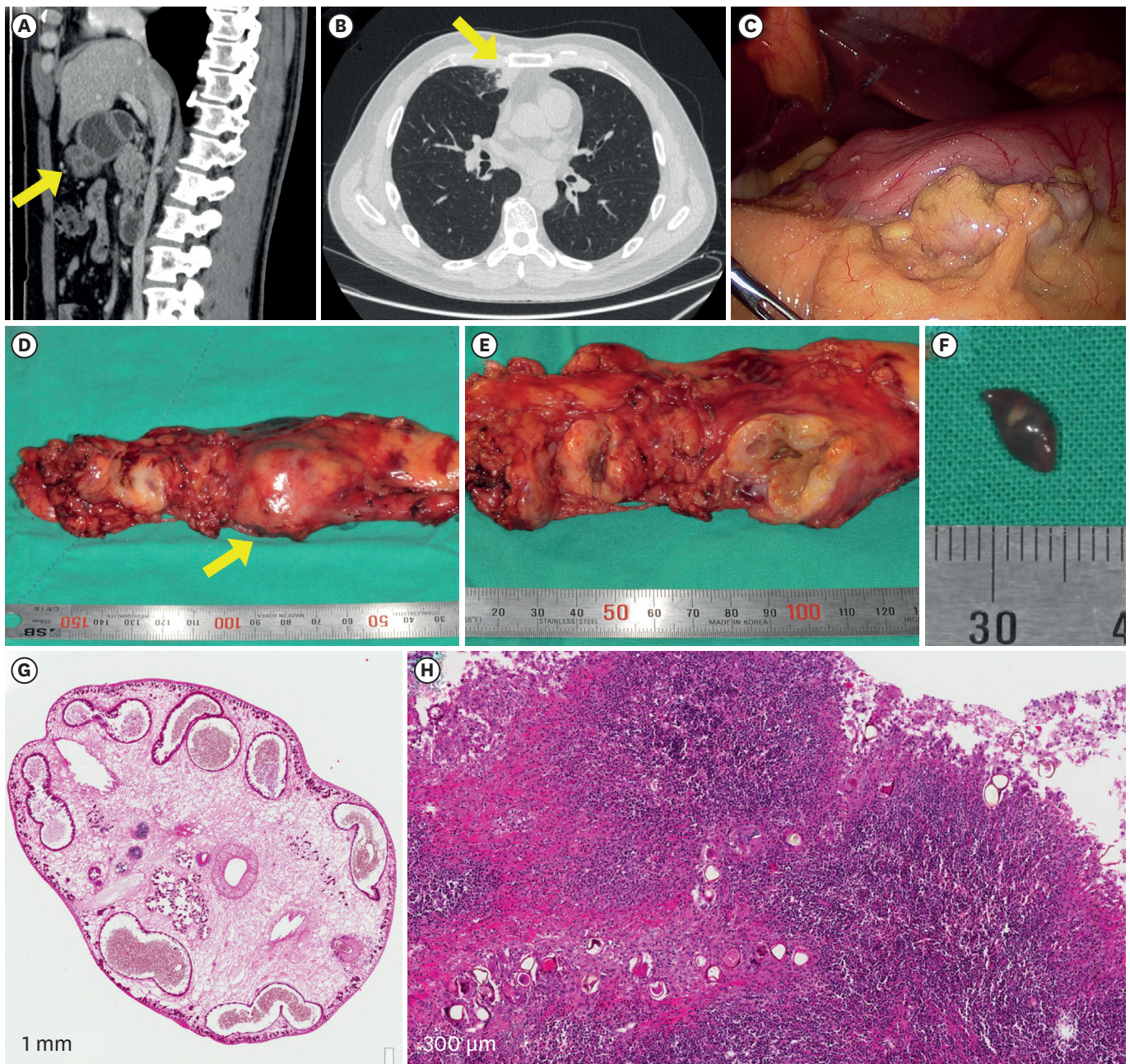


Fig. 1. A case of intra-abdominal paragonimiasis. (A) A gastric submucosal mass is shown in the abdominopelvic CT (yellow arrow). (B) A incidental lung nodule facing pleura are seen in the chest CT. (C) Laparoscopic finding shows multiple tiny nodules on the liver surface and omentum. (D) Gross finding of the gastric submucosal mass (yellow arrow) and lymph nodes. (E) Cross section of the mass. (F) Gross finding of the parasite. (G) Microscopic finding of the parasite (H & E, $\times 40$). (H) Chronic granulomatous inflammation with eosinophil infiltration and parasite eggs (H & E, $\times 200$).
CT = computed tomography, H & E = hematoxylin and eosin.