

# Ocular Surface Discomfort and *Demodex*: Effect of Tea Tree Oil Eyelid Scrub in *Demodex* Blepharitis

Hyun Koo, Tae Hyung Kim,  
Kyoung Woo Kim, Sung Wook Wee,  
Yeoun Sook Chun, and Jae Chan Kim

Department of Ophthalmology, Chung-Ang University  
College of Medicine, Seoul, Korea

Received: 2 July 2012

Accepted: 13 September 2012

Address for Correspondence:

Jae Chan Kim, MD

Department of Ophthalmology, Chung-Ang University Hospital,  
102 Heuksok-ro, Dongjak-gu, Seoul 156-755, Korea  
Tel: +82-2-6299-1689, Fax: +82-2-6299-1668  
E-mail: jck50ey@kornet.net

The authors indicate no financial support or financial conflict of interest. The study protocol was approved by the Institutional Review Board of the Chung Ang University Hospital, Seoul, Korea and was conducted in accordance with the tenets of the Declaration of Helsinki. Informed consent was obtained from all participants.

The purpose of this study was to evaluate the relation between ocular discomfort and ocular *Demodex* infestation, and therapeutic effects of tea tree oil (TTO) in *Demodex* blepharitis patients. Three hundred and thirty-five patients with ocular discomfort were evaluated for ocular *Demodex* infestation and subjective symptoms with ocular surface discomfort index (OSDI) score. Among them, *Demodex*-infested patients were randomized to receive either eyelid scrubbing with TTO (TTO group, 106 patients) or without TTO (Control group, 54 patients) for 1 month. *Demodex* were found in 84% of patients with ocular discomfort. The number of *Demodex* was significantly correlated with age ( $P = 0.04$ ) and OSDI score ( $P = 0.024$ ). After eyelid scrub treatment, *Demodex* count was reduced from  $4.0 \pm 2.5$  to  $3.2 \pm 2.3$  in the TTO group ( $P = 0.004$ ) and from  $4.3 \pm 2.7$  to  $4.2 \pm 2.5$  in the control group ( $P = 0.27$ ). Also, OSDI score was reduced from  $34.5 \pm 10.7$  to  $24.1 \pm 11.9$  in the TTO group ( $P = 0.001$ ) and from  $35.3 \pm 11.6$  to  $27.5 \pm 12.8$  in the control group ( $P = 0.04$ ). In conclusion, *Demodex* number showed a significant positive correlation with age and subjective ocular discomfort. The tea tree oil eyelid scrub treatment is effective for eliminating ocular *Demodex* and improving subjective ocular symptoms.

**Key Words:** Blepharitis; *Demodex*; Ocular Surface; Tea Tree Oil

## INTRODUCTION

*Demodex* (class *Arachnida*, superorder *Acariformes*) is one of the most commonly found ectoparasites in humans (1). Among the many *Demodex* species, only *D. folliculorum* and *D. brevis* are found on the human body, including the face, cheeks, forehead, nose, and eyelids (2). On the skin, *Demodex* colonizes the entire body, approximately  $\leq 5$  per square centimeter, and is associated with follicular pityriasis, pustular folliculitis, and rosacea.

On the eyelids, *D. folliculorum* lives in the eyelash follicles and *D. brevis* lives deep in the meibomian glands and the sebaceous glands of the lashes. They eat skin cells, hormones, and oils in the hair follicle. The pathogenic role of *Demodex* in ophthalmology has long been debated. Some studies indicate that *Demodex* is a nonpathogenic parasite. However, other reports that *Demodex* is an etiologic factor in chronic blepharitis, conjunctival inflammation, and meibomian gland dysfunction. In patients with ocular rosacea, *Demodex* causes unusual manifestations, such as superficial corneal neovascularization, marginal corneal infiltration, phlyctenule-like lesions, superficial corneal opacity, and nodular corneal scars (3-7). Gao et al. (8) reported a high prevalence of *Demodex* in eyelashes with cylin-

drical dandruff and introduced a method of evaluating ocular demodocosis by sampling and counting *Demodex*. Recently, Lee et al. (9) showed that the number of *Demodex* is significantly related to age, ocular discomfort, tear film instability, and poor ocular hygiene. In another study, IL-17, which causes inflammation of the lid margin and ocular surface, was significantly higher in the tears of *Demodex* infested blepharitis patients than *Demodex* free blepharitis patients (10, 11).

Tea tree oil (TTO) is natural oil distilled from the leaf of *Melaleuca alternifolia*. Gao et al. (12) showed its effect for killing *Demodex* in vitro and in vivo and introduced a lid scrubbing treatment with TTO, which has proven effective for decreasing *Demodex* in eyelash.

In this study, we tried to evaluate the relation between ocular surface discomfort and ocular demodocosis and analyzed the therapeutic effects of eyelash scrubbing with TTO and in a large group of ocular demodocosis patients.

## MATERIALS AND METHODS

This study was a prospective, randomized study performed at the Department of Ophthalmology of the Chung-Ang University Hospital.

### Study participants

Three hundred and thirty five patients with ocular surface discomfort, such as dryness, pruritus, ocular pain, or visual disturbance were enrolled between October 1, 2009 and December 31, 2011. Exclusion criteria were as follows: 1) Patient underwent any kind of eye surgery in last 6 months, 2) patients currently using eyedrops other than artificial tears, 3) patients who had eyelid scrubbing treatment previously or currently.

Among those patients, ocular demodecosis (*Demodex* positive) patients were randomly divided into two groups. The TTO group (n = 141) received eyelid scrub with TTO, and control group (n = 140) received eyelid scrub without TTO. One hundred and six ocular demodecosis patients were followed after eyelid scrub with TTO and 54 patients were followed after eyelid scrub without TTO (Fig. 1).

### Ocular examination

All patients underwent complete ophthalmologic examinations, including slit-lamp biomicroscope examination, microscopic *Demodex* examination, and tear sampling. After the potential consequences of the study were explained, informed consent was obtained from all participants for examinations.

Patients filled questionnaires about ocular discomfort (Ocular Surface Disease Index, OSDI) by themselves. The OSDI is a 12-item questionnaire designed to provide a rapid assessment of the ocular discomfort symptoms (light sensitiveness, soreness, blurred vision and etc.) and their impact on vision-related functioning (reading, driving, watching TV and etc.). The questionnaires were assessed on a scale of 0 to 100, with higher scores representing greater ocular discomfort (13).

### Microscopic *Demodex* examination

Ocular demodecosis and treatment response were confirmed in a blind manner by single examiner with microscopic exami-

nation of epilated lashes. A total of eight eyelashes were examined per patient. Two eyelashes with cylindrical dandruff were sampled from each lid and placed on a glass slide. Under a optical microscope in 400 magnification, a 20  $\mu$ L drop of saline was applied by pipette to the edge of the glass slide for lashes without retained dandruff. For lashes with retained heavy dandruff, 20  $\mu$ L of 100% alcohol was added. For the former, the number of *Demodex* was counted immediately, and for the latter the counting time was delayed up to 20 min to allow the cylindrical dandruff to dissolve and to stimulate the migration of embedded *Demodex*. The *Demodex* count was recorded as the total number of mites found in a total of eight lashes per patient.

### Eyelid scrub treatment

Ocular demodecosis patients were divided into two groups. The TTO group received eyelid scrub with TTO, and control group received eyelid scrub without TTO.

TTO (Tea tree certified organic<sup>®</sup>, Sydney Oil Co, Sydney, Australia) was diluted with mineral oil into different concentrations. Weekly lid scrubs with 50% TTO were performed in the clinic, and daily lid scrubs with 10% TTO were advised for four weeks, according to the method reported by Gao et al. (12). In brief, the clinic procedure was as follows: after applying a drop of 0.5% proparacaine, a cotton tip wetted in 50% TTO was used to scrub the lid margin and lash roots three times with a 10-min interval between each scrub. The patients were instructed to continue scrubbing daily at home and advised to close their eyes and massage their lids with medium pressure for three to five minutes using a cotton tip wetted in 10% TTO. After the treatment, the skin was rinsed with clean water and dried with a towel. We advised patients to perform home lid scrubs twice daily.

Control group patients were treated with eyelid scrubs without TTO. The control group patients were asked to scrub their eyelid and lashes with only saline as same as TTO group. We compared the *Demodex* count and OSDI score change of the two groups.

### Statistical analysis

All data are expressed as means  $\pm$  standard deviation (SD). Pre-treatment and post-treatment parameters were evaluated by Student's t-test, and the between-group data were assessed by 1-way analysis of variance (ANOVA) with Scheffe's post hoc tests. *P* value of < 0.05 was considered to be statistically significant. SPSS software version 16.0 (SPSS, Inc, Chicago, IL, USA) was used for data analysis.

### Ethics statement

The institutional review board of Chung-Ang University approved this study (2001-022-10), and all of the methods adhered to the principles of the Declaration of Helsinki.

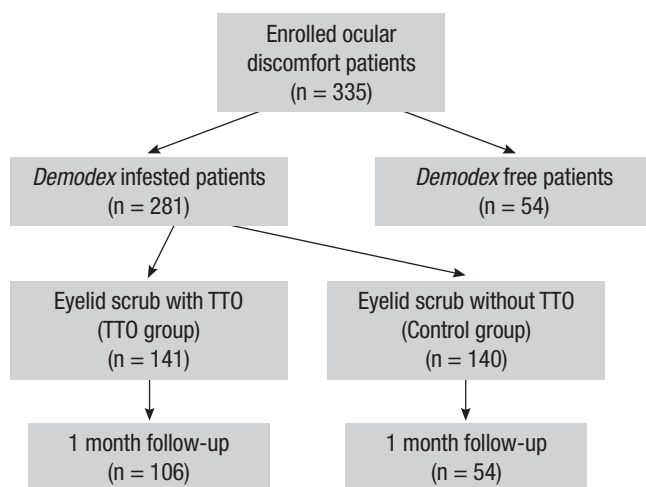


Fig. 1. Flow chart shows the total numbers of eyes enrolled, treated, and observed during the follow-up of the study.

## RESULTS

### Demographic and clinical features

The 335 patients enrolled in this study included 104 men and 231 women, with an average age of  $55.7 \pm 12.4$  yr (range, 23-85 yr). *Demodex* was found in 281(84%) of 335 patients. The mean total *Demodex* count per patient was  $3.4 \pm 3.3$  per 8 cilia. The mean total *Demodex* count per 8 cilia was  $3.2 \pm 3.6$  in men and  $3.5 \pm 3.2$  in women. There was no statistically significant difference in the prevalence of *Demodex* between the sex ( $P = 0.56$ ) (Table 1). *Demodex* was found in 80 of 104 men (77%) and 201 of 231 women (87%).

Among *Demodex* infested patient, most common symptom was ocular dryness (74.7%), and followed by itching sensation (42.7%), ocular irritation (39.1%), visual disturbance (32.0%), conjunctival injection (9.9%), and glare (3.6%).

The prevalence of *Demodex* according to age is shown in Table 2. The average number of *Demodex* per patient increased with age. The total number of *Demodex* per patient was positively correlated with increased age in all patients (Fig. 2A;  $P = 0.04$ , correlation coefficient  $R = 0.563$ ). The mean OSDI score was  $20.1 \pm 11.9$ , and the *Demodex* count showed a significant positive correlation with the OSDI score (Fig. 2B;  $P = 0.024$ , correlation coefficient  $R = 0.512$ ).

**Table 1.** Ocular *Demodex* counts and the OSDI scores of patients with ocular discomfort

Sex	N	Age (yr)	<i>Demodex</i> count (per 8 cilia)	OSDI score
Total	335	$55.7 \pm 12.4$	$3.4 \pm 3.3$	$20.1 \pm 11.9$
Male	104	$56.0 \pm 12.0$	$3.2 \pm 3.6^*$	$19.5 \pm 9.1^\dagger$
Female	231	$55.6 \pm 12.7$	$3.5 \pm 3.2^*$	$20.3 \pm 12.0^\dagger$

Student's t-test. \* $P = 0.56$ ;  $^\dagger P = 0.43$ .

### Tea tree oil treatment group

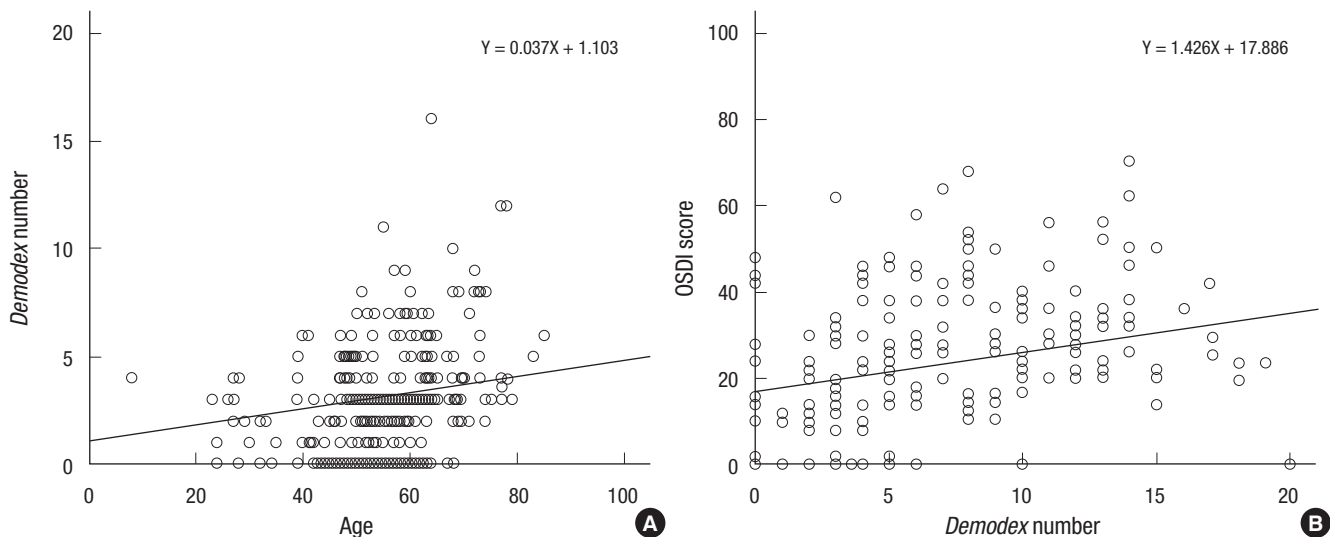
One hundred and six patients with ocular *Demodex* were followed after completing 1 month of TTO scrubs. Patients included 36 men and 70 women, with an average age of  $53.7 \pm 10.3$  yr (range, 23-85 yr). In these patients, the average number of *Demodex* and the OSDI score were significantly decreased. The *Demodex* count was decreased from  $4.0 \pm 2.5$  to  $3.2 \pm 2.3$  ( $P = 0.001$ ), and the OSDI score also decreased from  $34.5 \pm 10.7$  to  $24.1 \pm 11.9$  ( $P = 0.004$ ) (Table 3).

Since the TTO scrub was a daily treatment, the effects were expected to differ according to patient compliance. We divided the patients into three groups according to compliance and compared the effect. In the poor compliance group of patients who scrubbed their eyelids less than 5 times per week, the *Demodex* count and the OSDI score were slightly decreased from  $3.9 \pm 2.7$  to  $3.8 \pm 2.0$  and from  $34.4 \pm 11.3$  to  $34.2 \pm 10.1$ , respectively. However, this result was not statistically significant. In the moderate (5 to 9 times per week) and the good (more than 10 times per week) compliance groups, both the *Demodex* count and the OSDI score decreased significantly, and the changes were statistically significant (Table 3).

Among the tea tree oil treatment group, 23.6% of patients showed eradication of *Demodex* (zero *Demodex*). Patients of good compliance group showed 37.5% eradication rate and

**Table 2.** The relationship between ocular *Demodex* count and patient age

Age (yr)	<i>Demodex</i> count (per 8 cilia)
< 30	$1.8 \pm 1.7$
30-39	$2.4 \pm 2.1$
40-49	$2.5 \pm 2.5$
50-59	$3.1 \pm 2.8$
60-69	$3.9 \pm 3.2$
70 >	$3.8 \pm 3.2$

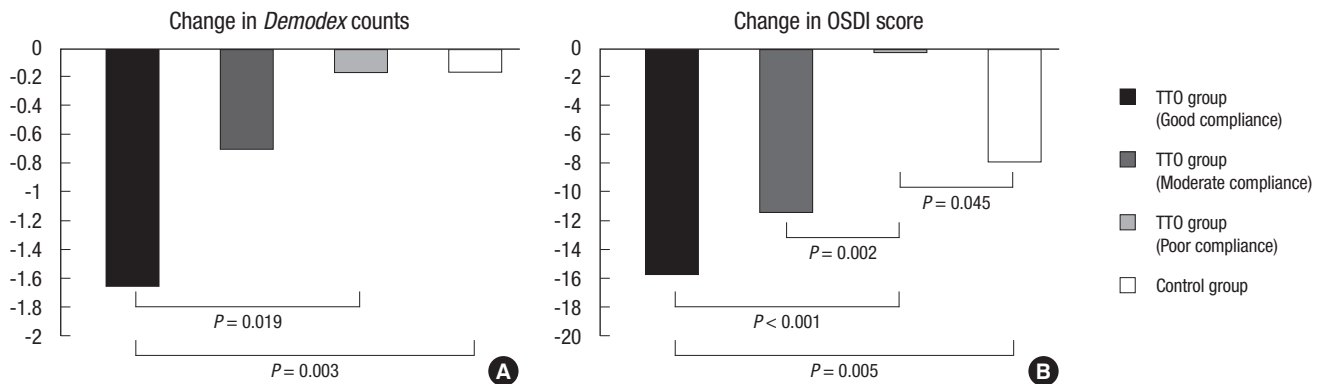


**Fig. 2.** Correlation of *Demodex* with age and ocular surface discomfort index. The number of *Demodex* showed significant positive correlations with increasing age (A;  $P = 0.04$ , correlation coefficient  $R = 0.563$ ) and ocular surface discomfort index (OSDI) score (B;  $P = 0.024$ , correlation coefficient  $R = 0.512$ ) in ocular discomfort patients.

**Table 3.** *Demodex* counts and OSDI scores before and after tea tree oil treatment in ocular *Demodex* patients

Group & Compliance	N	<i>Demodex</i> count (per 8 cilia)			Eradication rate (%)	OSDI		
		Before treatment	After treatment	<i>P</i> value		Before treatment	After treatment	<i>P</i> value
TTO group	106	4.0 ± 2.5	3.2 ± 2.3	0.001	23.6	34.5 ± 10.7	24.1 ± 11.9	0.004
Good (> 10 times/wk)	40	4.2 ± 2.6	2.6 ± 2.5	< 0.001	37.5	35.2 ± 10.5	18.6 ± 11.1	< 0.001
Moderate (5-9 times/wk)	36	4.0 ± 2.2	3.4 ± 2.3	< 0.001	18.9	33.6 ± 12.6	22.3 ± 12.6	< 0.001
Poor (< 5 times/wk)	30	3.9 ± 2.7	3.8 ± 2.0	0.52	10	34.4 ± 11.3	34.2 ± 10.1	0.48
Control group	54	4.3 ± 2.7	4.2 ± 2.5	0.27	7	35.3 ± 11.6	27.5 ± 12.8	0.04

TTO, tea tree oil.

**Fig. 3.** Changes in *Demodex* count (A) and OSDI score (B) after eyelid scrub in TTO group and control group. Group comparisons were performed using ANOVA and Scheffe's post hoc tests. Only significant *P* values are shown.

moderate group showed 18.9% eradication rate. In poor compliance group, only 10% of patients were *Demodex* free after tea tree oil treatment.

#### Control group (eyelid scrub without TTO)

Fifty four patients with *Demodex* were followed after receiving eyelid scrub without tea tree oil. Patients were 20 men and 34 women, with an average age of  $55.6 \pm 11.3$  yr (range, 25-85 yr). The *Demodex* count was decreased from  $4.3 \pm 2.7$  to  $4.2 \pm 2.5$  but not statistically significant ( $P = 0.27$ ). And only 7% of patients were *Demodex*-free after eyelid scrubs without TTO. The OSDI score also decreased statistically significantly from  $35.3 \pm 11.6$  to  $27.5 \pm 12.8$  ( $P = 0.04$ ) (Table 3).

Both TTO treatment group and control group showed *Demodex* decrease after treatment, but TTO group showed higher decrease of mean *Demodex* number (TTO group,  $-0.85 \pm 1.84$ ; Control group,  $-0.17 \pm 1.14$ ) which is statistically significant ( $P = 0.004$ ).

Changes in *Demodex* count and OSDI score of TTO sub-group and control group were compared with ANOVA and Scheffe's post hoc test. Both *Demodex* counts and OSDI scores were significantly decreased in good compliance group compared with poor compliance group or control group. However, *Demodex* decrease in moderate and poor compliance group showed no statistical significance compared with control group (Fig. 3).

## DISCUSSION

The number of *Demodex* increased with patient age in this study. Lee et al. (9) also reported such correlation between age and the number of *Demodex*, for which there are several explanations. Because *Demodex* is a symbiotic mite, old people tend to be more heavily infested with *Demodex*. Also, poor ocular hygiene with increasing age may be associated with an increase of *Demodex*. From our experience, old people with good eyelid hygiene had fewer *Demodex*, while young people with poor eyelid hygiene had more *Demodex*.

*Demodex* feed on skin cells, hormones, and oils that accumulate within the hair follicle (4-6). Therefore, the sex of the host is thought to be related to the prevalence of ocular *Demodex*. However in our study, there was no relationship between the number of *Demodex* and the sex of the patients. There are several reports describing the relationship between rates of *Demodex* infestation and sex, but this topic remains controversial. Türk et al. (14) reported that males have a higher rate of *Demodex* infestation, whereas Forton et al. (15) reported that females have a higher rate. Kemal et al. (16) and Lee et al. (9) reported no relationship between rates of *Demodex* infestation and sex.

In our study, an increase in *Demodex* was correlated with an increase in subjective symptoms. The index demonstrates sensitivity and specificity in distinguishing between normal subjects and patients with ocular discomfort. Higher OSDI scores represent greater ocular subjective disability. The mean OSDI



score of patients with ocular *Demodex* was 20.1, which indicates moderate to severe ocular discomfort. Patients with *Demodex* visited our clinic with various ocular surface symptoms, such as dryness, pruritus, ocular pain, visual disturbance, conjunctival injection, and glare. These symptoms are typical of blepharitis. Many reports suggest that ocular *Demodex* is prevalent in blepharitis patients. Several studies reported that the *Demodex* infestation is related to corneal and conjunctival pathologic features, and the severity of disease decreases after *Demodex* is treated (2-5). Since 84% of patients who complained of ocular discomfort were infested with ocular *Demodex* in our sample, clinicians should be aware of the possibility of ocular *Demodex* and perform appropriate examinations in these patients.

The role of *Demodex* in the pathogenesis of blepharitis and other ocular diseases has long been debated. Although many reports and studies have presented *Demodex* as a non-pathogenic organism, recent studies show evidence of tissue damage in association with *Demodex*. Dry eye syndrome and blepharitis are thought to be related to *Demodex*-induced ocular surface disease. A recent study from Kim et al. (11) proposed a possible mechanism of *Demodex*-induced blepharitis. The study revealed significant differences in the concentrations of a number of cytokines and chemokines in the blepharitis group with ocular *Demodex* compared with the blepharitis group without ocular *Demodex*. Specifically, levels of IL-7, IL-12, and IL-17 in the tears of patients with *Demodex* blepharitis were elevated but then normalized after TTO treatment. The authors concluded that the infestation of *Demodex* mites induces secretion of IL-17, which can stimulate inflammatory or allergic reactions, as well as cause mechanical blockage of follicles, which ultimately results in ocular surface damage.

There have been many attempts to eliminate ocular *Demodex* in blepharitis patients. Gao et al. (12) reported that *Demodex* can be effectively eliminated, in vitro and in vivo, by TTO eyelid scrubs. TTO has traditionally been used in Australia for skin wounds and infections. It is also known for its antibacterial, antifungal, anti-inflammatory, and acaricidal effects (17-20). Gao reported that an eyelid scrub using 50% TTO mixed with shampoo was effective for eliminating *Demodex*. The two main ingredients of TTO, 1,8-cineole and terpinen-4-ol, have acetylcholinesterase-inhibiting effects that produce an acaricidal effect, and also lead the mite to exit the hair follicle and sweep out before mating.

The effects of TTO on ocular demodexosis have been reported previously in our study (10, 11); however, there were no large-scale clinical trials of TTO treatment for ocular *Demodex*. Our results demonstrated that scrubbing eyelashes with TTO decreased *Demodex* counts and improved ocular discomfort. Eyelid scrubbing is one of the most commonly recommended treatments for blepharitis. From our study, simple eyelid scrubbing with saline without TTO might help reducing *Demodex* num-

bers and improve ocular symptoms. However, it is not enough to eradicate ocular *Demodex*. Only 7% of the patients were *Demodex*-free after eyelid scrubbing without TTO, on the other hand, 24% were *Demodex*-free after eyelid scrubbing with TTO. Also TTO group showed significantly higher decrease of mean *Demodex* number and OSDI score elevation than control group.

Patient compliance is a key for successful *Demodex* eradication. TTO group showed variable eradication results according to patient compliance. Eradication rates were varied from 37.5% to 10%. Only eyelid scrubbing more than 10 times per week with TTO showed significant decrease of both *Demodex* and OSDI score. From this result, authors recommend patients to scrub frequently, at least 5 times per week. Eyelid scrub without TTO showed decreased OSDI score but no *Demodex* change. This shows eyelid scrub without TTO has only limited effect on improving subjective discomfort and cannot eliminate the *Demodex*.

Contact dermatitis, allergic reactions, and ocular irritation are well-known complications of TTO treatment. In this study, five of 106 followed patients reported ocular irritation. Most of these symptoms were caused by improper scrubbing. After re-education of eyelid scrubbing method, ocular irritation has been disappeared in these patients. There were no severe complications of TTO treatment. TTO treatment is safe and acceptable for clinical use in patients with ocular *Demodex*. Since patient compliance is a crucial factor for the successful eradication of ocular *Demodex* with tea tree oil, proper patient education is important.

This study focused on the effect of TTO eyelid scrub treatment in patients with ocular *Demodex* infestation. The results show that the severity of ocular surface discomfort has a strong positive correlation with the number of *Demodex* and TTO eyelid scrub treatment is an effective method for eliminating *Demodex* when frequently applied. Although pathologic role of ocular *Demodex* may still in debate, these findings suggest that the treatment of ocular demodexosis may improve ocular discomfort.

## REFERENCES

1. Basta-Juzbasić A, Subić JS, Ljubojević S. *Demodex folliculorum* in development of dermatitis rosaceiformis steroidica and rosacea-related diseases. *Clin Dermatol* 2002; 20: 135-40.
2. English FP, Nutting WB. *Demodicosis of ophthalmic concern*. *Am J Ophthalmol* 1981; 91: 362-72.
3. Kamoun B, Fourati M, Feki J, Mlik M, Karray F, Trigui A, Ellouze S, Hammami B, Chaabouni M, Ayadi A. *Blepharitis due to Demodex: myth or reality?* *J Fr Ophthalmol* 1999; 22: 525-7.
4. Humiczewska M. *Demodex folliculorum and Demodex brevis (Acarida) as the factors of chronic marginal blepharitis*. *Wiad Parazytol* 1991; 37: 127-30.
5. Coston TO. *Demodex folliculorum blepharitis*. *Trans Am Ophthalmol*

- Soc 1967; 65: 361-92.
6. Heacock CE. *Clinical manifestations of demodicosis*. *J Am Optom Assoc* 1986; 57: 914-9.
  7. Morfin Maciel BM. *Demodicidosis in a female patient treated as allergic blepharoconjunctivitis: a case report*. *Rev Alerg Mex* 2003; 50: 232-6.
  8. Gao YY, Di Pascuale MA, Li W, Liu DT, Baradaran-Rafii A, Elizondo A, Kawakita T, Raju VK, Tseng SC. *High prevalence of ocular Demodex in lashes with cylindrical dandruffs*. *Invest Ophthalmol Vis Sci* 2005; 46: 3089-94.
  9. Lee SH, Chun YS, Kim JH, Kim ES, Kim JC. *The relationship between Demodex and ocular discomfort*. *Invest Ophthalmol Vis Sci* 2010; 51: 2906-11.
  10. Kim JH, Chun YS, Kim JC. *Clinical and immunological responses in ocular demodocosis*. *J Korean Med Sci* 2011; 26: 1231-7.
  11. Kim JT, Lee SH, Chun YS, Kim JC. *Tear cytokines and chemokines in patients with Demodex blepharitis*. *Cytokine* 2011; 53: 94-9.
  12. Gao YY, Di Pascuale MA, Li W, Baradaran-Rafii A, Elizondo A, Kuo CL, Raju VK, Tseng SC. *In vitro and in vivo killing of ocular Demodex by tea tree oil*. *Br J Ophthalmol* 2005; 89: 1468-73.
  13. Schiffman RM, Christianson MD, Jacobsen G, Hirsch JD, Reis BL. *Reliability and validity of the Ocular Surface Disease Index*. *Arch Ophthalmol* 2000; 118: 615-21.
  14. Türk M, Oztürk I, Sener AG, Küçükbay S, Afşar I, Maden A. *Comparison of incidence of Demodex folliculorum on the eyelash follicle in normal people and blepharitis patients*. *Türkiye Parazitol Derg* 2007; 31: 296-7.
  15. Forton F, Germaux MA, Brasseur T, De Liever A, Laporte M, Mathys C, Sass U, Stene JJ, Thibaut S, Tytgat M, Seys B. *Demodicosis and rosacea: epidemiology and significance in daily dermatologic practice*. *J Am Acad Dermatol* 2005; 52: 74-87.
  16. Kemal M, Sümer Z, Tokar MI, Erdoğan H, Topalkara A, Akbulut M. *The prevalence of Demodex folliculorum in blepharitis patients and the normal population*. *Ophthalmic Epidemiol* 2005; 12: 287-90.
  17. Messenger S, Hammer KA, Carson CF, Riley TV. *Assessment of the antibacterial activity of tea tree oil using the European EN 1276 and EN 12054 standard suspension tests*. *J Hosp Infect* 2005; 59: 113-25.
  18. Halcón L, Milkus K. *Staphylococcus aureus and wounds: a review of tea tree oil as a promising antimicrobial*. *Am J Infect Control* 2004; 32: 402-8.
  19. Oliva B, Piccirilli E, Ceddia T, Pontieri E, Aureli P, Ferrini AM. *Antimycotic activity of Melaleuca alternifolia essential oil and its major components*. *Lett Appl Microbiol* 2003; 37: 185-7.
  20. Hammer KA, Carson CF, Riley TV. *Antifungal effects of Melaleuca alternifolia (tea tree) oil and its components on Candida albicans, Candida glabrata and Saccharomyces cerevisiae*. *J Antimicrob Chemother* 2004; 53: 1081-5.