

# Methotrimeprazine-induced Corneal Deposits and Cataract Revealed by Urine Drug Profiling Test

Seong Taeck Kim<sup>1</sup>, Jae Woong Koh<sup>1</sup>,  
Joon Mo Kim<sup>2</sup>, Won Young Kim<sup>3</sup>,  
and Gwang Ju Choi<sup>1</sup>

Department of Ophthalmology<sup>1</sup>, Chosun University College of Medicine, Gwangju; Department of Ophthalmology<sup>2</sup>, Kangbuk Samsung Hospital, Sungkyunkwan University School of Medicine, Seoul; Department of Emergency Medicine<sup>3</sup>, Asan Medical Center, Ulsan University College of Medicine, Seoul, Korea

Received: 2 November 2009  
Accepted: 2 February 2010

Address for Correspondence:

Jae-Woong Koh, M.D.

Department of Ophthalmology, Chosun University College of Medicine, 588 Seoseok-dong, Dong-gu, Gwangju 501-140, Korea

Tel: +82.62-220-3190, Fax: +82.62-225-9839

E-mail: clearcornea@paran.com

Two schizophrenic patients who had been taking medication for a long period presented with visual disturbance of 6-month duration. Slit-lamp examination revealed fine, discrete, and brownish deposits on the posterior cornea. In addition, bilateral star-shaped anterior subcapsular lens opacities, which were dense, dust-like granular deposits, were noted. Although we strongly suspected that the patient might have taken one of the drugs of the phenothiazine family, we were unable to obtain a history of medications other than haloperidol and risperidone, which were taken for 3 yr. We performed a drug profiling test using urine samples and detected methotrimeprazine. The patient underwent surgery for anterior subcapsular lens opacities. Visual acuity improved in both eyes, but the corneal deposits remained. We report an unusual case of methotrimeprazine-induced corneal deposits and cataract in a patient with psychosis, identified by using the urine drug profiling test.

**Key Words:** Methotrimeprazine; Cornea Deposits; Cataract

## INTRODUCTION

Phenothiazine was introduced in 1953 and was widely used in psychiatry in the 1960s for the chronic treatment of schizophrenia. By the 1970s, there was a 30% reduction in the hospitalization of schizophrenics, which was attributed to the introduction of phenothiazines, especially chlorpromazine. However, despite its extremely effective antipsychotic properties and a low incidence of extrapyramidal symptoms, the use of phenothiazines has significantly declined over the last decade owing to its ocular complications.

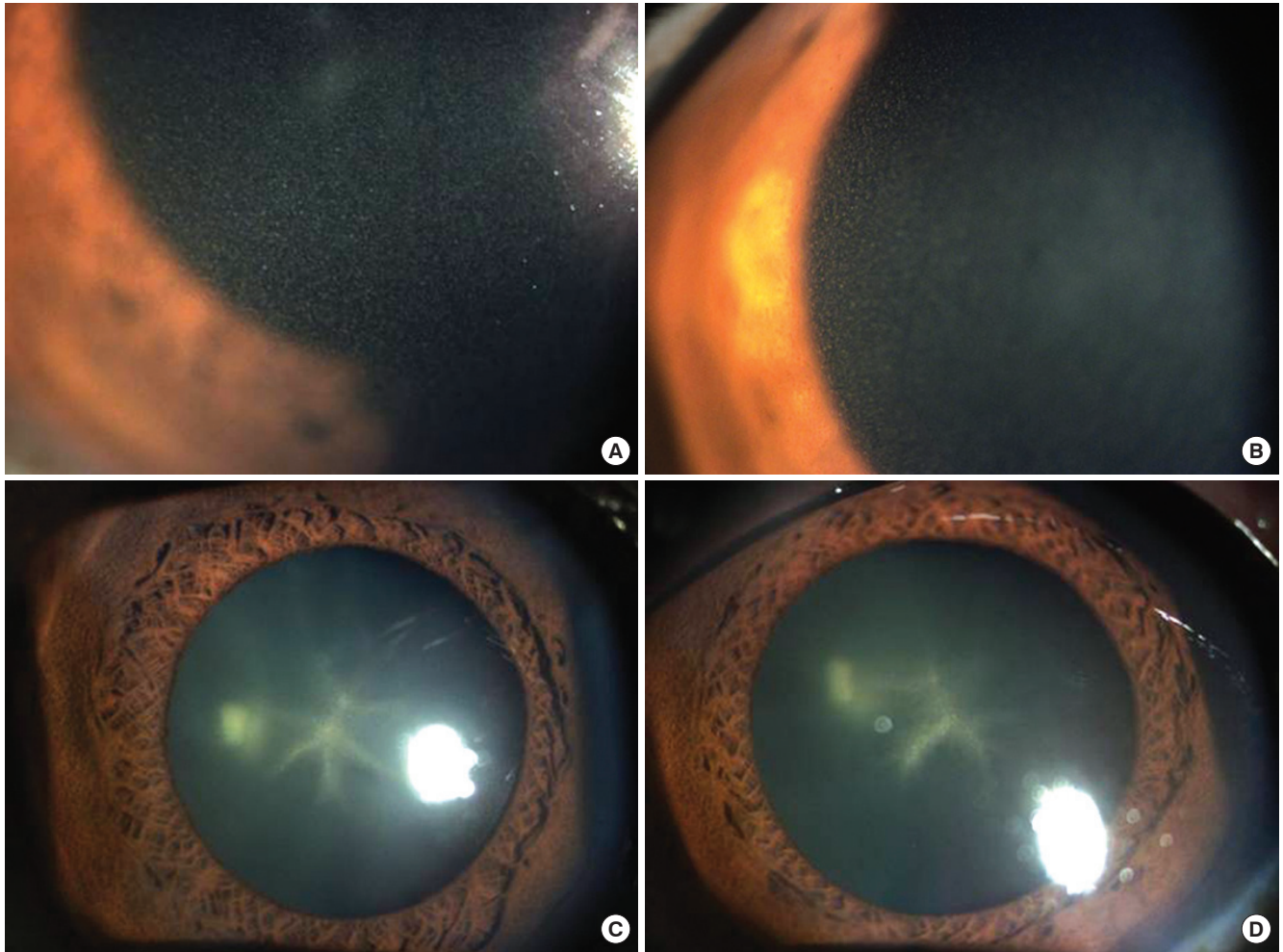
Phenothiazine ocular toxicity affecting the cornea, conjunctiva, and lens was first described by Greiner and Berry in 1964 (1). Since then, numerous authors have described ocular manifestations of long-term phenothiazine therapy. It is hypothesized that phenothiazines denature proteins when exposed to light; the proteins then become opacified and are deposited in the lens, corneal stroma, and conjunctiva (2, 3). These ocular changes persist even after discontinuation of the drug.

There have been several case reports of chlorpromazine-induced corneal deposits and cataracts; however, methotrimeprazine-induced corneal deposits and cataracts are unusual and rare. Herein, we report the first cases, to our knowledge, of methotrimeprazine-induced corneal deposits and cataract.

## CASE REPORTS

### Case 1

A 48-yr-old man, who had been taking medication for schizophrenia, presented with visual disturbance of 6-month duration (June 22, 2006). In a span of 10 yr, he had been hospitalized several times for psychiatric treatment and had been under outpatient observation. Slit-lamp examination revealed fine, discrete, and brownish deposits on the posterior cornea (Fig. 1A, B). In addition, bilateral star-shaped anterior subcapsular lens opacities, which were dense, dust-like granular deposits, were noted (Fig. 1C, D). Best-corrected visual acuity was 20/40 in the right eye and 20/50 in the left eye. Other ocular findings were normal. According to the information provided by his family doctor, the patient had received 3 mg of haloperidol (thioxanthene family) and 6 mg of risperidone (molindone family) per day for 3 yr. Although we strongly suspected that the patient might have taken one of the drugs of the phenothiazine family, we were unable to obtain a history of medications other than those mentioned above. We performed the Remedi HS drug profiling test (Bio-Rad Co., Hercules, CA, USA) by using urine samples and detected methotrimeprazine. Analyzing the medical history, we found that the patient had taken methotrimeprazine habitually by using prescriptions from a different doctor



**Fig. 1.** Slit lamp photographs (Case 1). It showed fine, discrete, and brownish deposits on the posterior cornea. (A) right eye, (B) left eye. It showed characteristic star-shaped deposits in the anterior sub-capsular area. (C) right eye, (D) left eye.

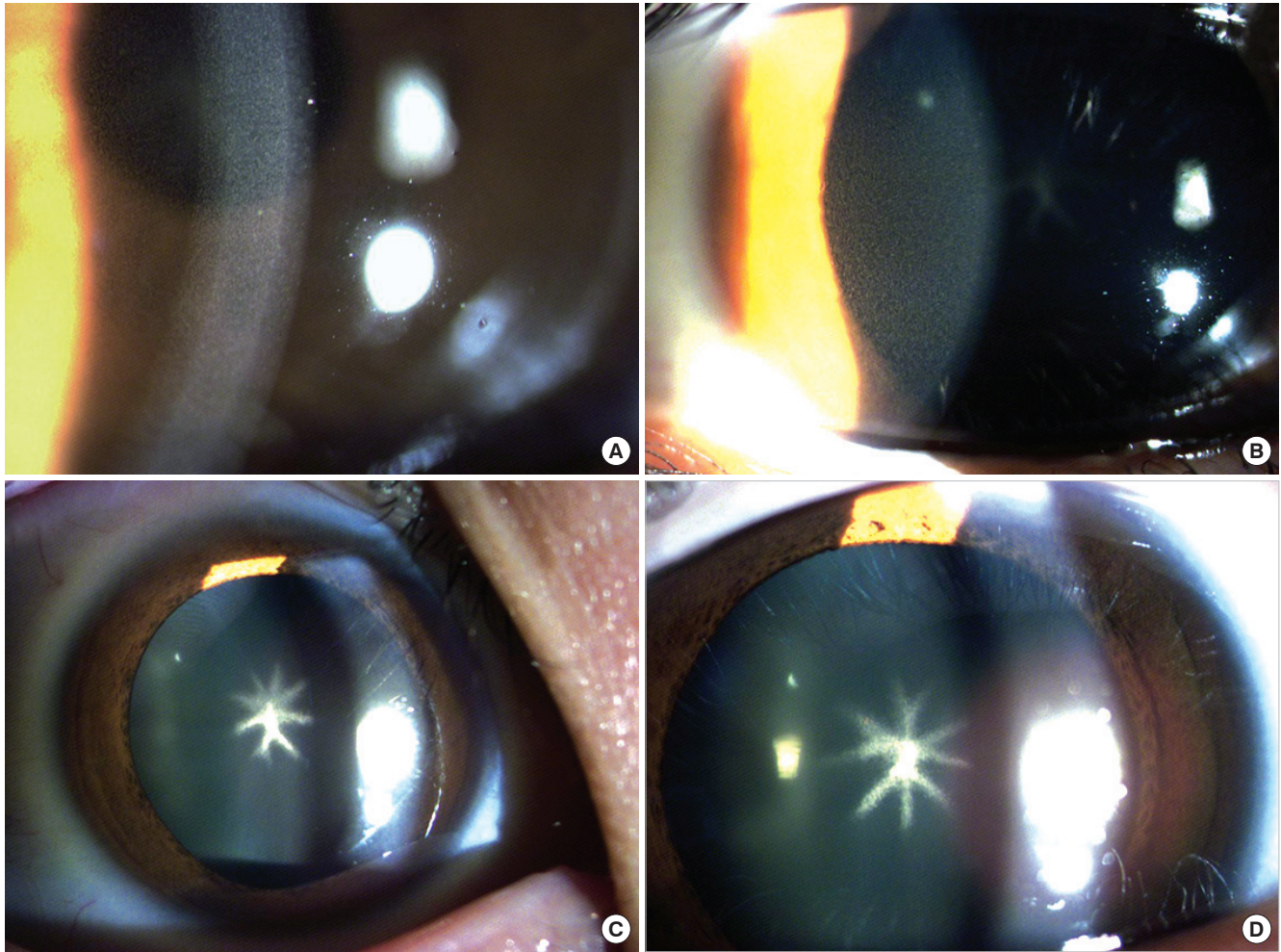
for about 3 yr, whenever he suffered from any anxiety or discomfort. Methotrimeprazine-induced corneal deposits and cataract were diagnosed on the basis of the clinical and laboratory findings. It was then decided that the patient should undergo surgery for the anterior subcapsular lens opacities, and he subsequently underwent phacoemulsification with posterior chamber foldable intraocular lens implantation in both eyes. Topical antibiotics and steroids were used for 4 weeks, with tapering of the steroids. Three years after the operation, visual acuity had improved to 20/20 in both eyes, but the corneal deposits remained.

### Case 2

In another case, a 28-yr-old woman, also being treated for mental retardation, hysteria, and nervous ticks, had been experiencing visual disturbance for over a period of 4 months (Jan 12, 2009). Previously, she had been hospitalized and received outpatient care for these psychiatric illnesses for 4 yr. Slit-lamp examination revealed fine, discrete, and brownish deposits on the posterior cornea (Fig. 2A, B). In addition, bilateral star-shaped an-

terior subcapsular lens opacities, which were dense, dust-like granular deposits, were noted (Fig. 2C, D). Visual acuity was 20/50 in both eyes. Other ocular findings were normal. The patient was treated with 9 mg of haloperidol (thioxanthene family), 300 mg of valproic acid, 1 mg of benztropine, 50 mg of trazodone, and 2.5 mg of diazepam. After diazepam was discontinued, she was given 15 mg of haloperidol, 400 mg of valproic acid, 1 mg of benztropine, and 1 mg of risperidone (molindone family), accordingly. At that time, we strongly suspected that the patient was taking a drug from the phenothiazine family, but we could not find any evidence of such use. However, we did detect methotrimeprazine in her body by using the Remedi HS drug profiling system (Bio-Rad Co., Hercules, CA, USA). Analyzing the medical history, we discovered that the patient habitually took methotrimeprazine over a period of 4 yr by obtaining prescriptions from various doctors, on suffering from any anxiety or discomfort. Furthermore, on the basis of clinical and laboratory results, methotrimeprazine-induced corneal deposits and cataract were detected.





**Fig. 2.** Slit lamp photographs (Case 2). It showed fine, discrete, and brownish deposits on the posterior cornea. (A) right eye, (B) left eye. It showed characteristic star-shaped deposits in the anterior sub-capsular area. (C) right eye, (D) left eye.

## DISCUSSION

Phenothiazines, such as chlorpromazine or methotrimeprazine, have been widely used for the treatment of mental diseases after being introduced to the psychiatric clinics in 1953, and many studies have been conducted on the side effects of overdose and their complications (2-4). Methotrimeprazine is used for the treatment of psychosis, particularly in schizophrenia and manic phases of bipolar disorder. It should never be used in the treatment of agitated depressions because this drug increases agitation through the side effect of akathisia. Methotrimeprazine is also used in lower doses for the treatment of nausea. Long-term medication of phenothiazine accumulates 50 times higher blood concentration in the ocular tissue in comparison to that of other tissues of the body (5). In 1964, Greiner and Berry (1) first described their findings on 70 patients who received long-term medication of chlorpromazine (phenothiazine family), reporting that brown granular pigmentation occurred in the parenchyma of the cornea and a central star-shaped opacity de-

veloped in the center of anterior capsular lens. Especially, many studies were conducted on the correlation between phenothiazine and lens opacity. McCarty et al. (6) reported that ratio of anterior capsular opacity in cataract patients who did not receive phenothiazine medications was 0.2%, while the ratio was 26% for schizophrenia patients who received phenothiazine medication. Ruigomez et al. (7) conducted a study on the incidence rate of cataract of schizophrenia patients and control group subjects. Although the incidence rate of cataract was higher in the control group than in the schizophrenic patients, the incidence rate of cataract in patients under long-term medication of over 300 mg chlorpromazine (phenothiazine family) daily was 8.8 times that of the control group. Rather than reporting schizophrenia as a risk factor of cataract, the authors reported that long-term medication of phenothiazine increases the risk of cataract. It is believed that the clinical changes in the conjunctiva, cornea, and lens observed in patients who received a specific dosage of drugs belonging to the phenothiazine family could be attributed to an increase in the number of melanin cells as-

sociated with exposure of the eyes to ultraviolet rays and the accumulation of abnormal metabolites due to a phototoxic reaction resulting from the photosensitization of chlorpromazine that is present in a high concentration in the eyes exposed to visible and ultraviolet rays. Further, mutual interaction with phenothiazine probably caused excessive production and accumulation of melanin or melanin analogs. There is a controversy regarding the toxic level of phenothiazine. DeLong et al. (8) reported in 1965 that changes in the eyes were rare when the total dosage of chlorpromazine was 500 mg, that the characteristic eye findings were generally observed in patients receiving a dosage of over 1,000 mg, and that these findings were observed in more than 90% of patients receiving a dosage of over 2,500 mg. Thaler et al. (9) reported in 1985 that if the psychiatric conditions may require a daily dosages exceeding 800 mg of chlorpromazine, pigmentation of lens can begin to occur within as early as 14 to 20 months of treatment. Dosages consisting of 2,000 mg of chlorpromazine daily have caused lenticular changes within as early as only 6 months of therapy. As the dosage increased, changes in the eyes became more distinct and such changes continued after stopping the medication. Lal et al. (10) conducted a study on 15 patients with pigmentation in the skin and corneal endothelium due to long-term usage of phenothiazine by replacing phenothiazine with other neuroleptics (haloperidol, levomepromazine, trifluoperazine, and thioproperazine). They reported that ocular changes usually persist after the administration of the drug is stopped, but skin pigmentation can be reversible. They reported that mechanisms of pigmentation of the skin and cornea might be different from each other.

Although we strongly suspected that the patients in these cases might have taken one of the drugs of the phenothiazine family, we were unable to obtain a history of medications other than haloperidol and risperidone. We performed the Remedi HS drug profiling test (Bio-Rad Co., Hercules, CA, USA) by using urine samples and detected methotrimeprazine. The Remedi HS drug profiling system used automated, high-performance liquid chromatography to identify the presence of antipsychotic

and anaesthetic drugs for the confirmatory urinalysis. The sensitivity and specificity were calculated over 80% both in literature (11). There have been several case reports of chlorpromazine-induced corneal deposits and cataract; however, methotrimeprazine-induced corneal deposits and cataracts are unusual, and identification by means of a urine drug profiling test are even rare.

## REFERENCES

1. Greiner AC, Berry K. *Skin pigmentation and corneal and lens opacities with prolonged chlorpromazine therapy.* *Can Med Assoc J* 1964; 90: 663-5.
2. Howard RO, McDonald CJ, Dunn B, Creasey WA. *Experimental chlorpromazine cataracts.* *Invest Ophthalmol* 1969; 8: 413-21.
3. Jung BS, Lee TH, Lee HY. *Ocular findings associated with long-term chlorpromazine therapy.* *J Korean Ophthalmol Soc* 1996; 37: 1951-7.
4. Kim HS, Choi HJ, Yun YS. *Two cases of chlorpromazine-induced corneal and lenticular opacity.* *J Korean Ophthalmol Soc* 2002; 43: 2349-53.
5. Potts AM. *The concentration of phenothiazines in the eye of experimental animals.* *Invest Ophthalmol* 1962; 1: 522-30.
6. McCarty CA, Wood CA, Fu CL, Livingston PM, Mackersey S, Stanislavsky Y, Taylor HR. *Schizophrenia, Psychotropic medication and Cataract.* *Ophthalmology* 1999; 106: 683-7.
7. Ruigómez A, García Rodríguez LA, Dev VJ, Arellano F, Raniwala J. *Are schizophrenia or antipsychotic drugs a risk factor for cataracts? Epidemiology* 2000; 11: 620-3.
8. DeLong SL, Poley BJ, McFarlane JR Jr. *Ocular changes associated with long term chlorpromazine therapy.* *Arch Ophthalmol* 1965; 73: 611-7.
9. Thaler JS, Curinga R, Kiracofe G. *Relation of graded ocular anterior chamber pigmentation to phenothiazine intake in schizophrenics--quantification procedures.* *Am J Optom Physiol Opt* 1985; 62: 600-4.
10. Lal S, Bloom D, Silver B, Desjardins B, Krishnan B, Thavundayil J, Thompson T. *Replacement of chlorpromazine with other neuroleptics: effect on abnormal skin pigmentation and ocular changes.* *J Psychiatry Neurosci* 1993; 18: 173-7.
11. Huang MK, Dai YS, Lee CH, Liu C, Tsay WI, Li JH. *Performance characteristics of DRI, CEDIA, and REMEDI systems for preliminary tests of amphetamines and opiates in human urine.* *J Anal Toxicol* 2006; 30: 61-4.