

## Unusual Complication of Urethral Catheterization: A Case Report

We report an unusual complication caused by urethral catheterization. During a routine urethral catheter change in a 38-yr-old woman, a 14-Fr Foley catheter was accidentally placed into the right ureter through the ureteral orifice. The position of the catheter was confirmed by retrograde urogram through urethral catheter. Percutaneous nephrostomy was performed with subsequent proper replacement of a urethral catheter. Two weeks later, the injured ureter had healed without leakage or obstruction.

**Key Words :** Urinary Catheterization; Ureter; Complications

**Myung Ki Kim, Kwangsung Park**

Department of Urology, Chonnam National University  
Medical School and Research Institute of Medical  
Sciences, Gwangju, Korea

Received : 2 April 2007

Accepted : 21 June 2007

### Address for correspondence

Kwangsung Park, M.D.  
Department of Urology, Chonnam National University  
Medical School and Research Institute of Medical  
Sciences, 8 Hak-dong, Dong-gu, Gwangju 501-757,  
Korea  
Tel : +82.62-220-6703, Fax : +82.62-227-1643  
E-mail : uropark@gmail.com

### INTRODUCTION

Trauma due to urethral catheterization is rarely encountered in women. Herein, we report a very rare complication of urethral catheterization. A 14-Fr Foley catheter was accidentally placed into the right ureter in a 38-yr-old woman.

### CASE REPORT

A 38-yr-old paraplegic woman was referred to a hospital emergency room due to lower abdominal pain following a urethral catheter change. She had no tactile sensation below the level of the umbilicus. Five years before, she had developed neurogenic bladder as a result of a 10th thoracic spinal cord injury. Her bladder was being drained using a urethral Foley catheter. She had no evidence of vesicoureteral reflux. On the day of admission, a catheter change had been performed by the nursing staff, using 14-Fr Foley catheter without undue events. In order to determine the location of the tube and rule out bladder rupture, cystography was performed. There was considerable leakage of contrast media around the mid-ureter, and the Foley catheter tip was observed to be located at the right lower ureter (Fig. 1). After removal of the Foley catheter, cystoscopy was performed. The bladder mucosa was intact and both ureteral orifices were in a typical position and normal shape. Ureteral stenting failed because guide wires could not be passed over the injured site. A new urethral catheter was properly inserted and percutaneous nephrostomy

was performed (Fig. 2A). Two weeks later, antegrade urography showed that the injured ureter had healed without leakage or obstruction (Fig. 2B).

### DISCUSSION

Urethral catheterization is commonly performed and is usually safe, although complications, such as infection, bleeding, injury to the urethra or bladder, or catheter malfunction can ensue (1). The two most common complications related to Foley catheters, particularly in males, are urethral trauma and retention of the catheter balloon in the urethra (2). Serious complications such as bladder perforation and/or peritonitis (3) and rectovesical fistula (4) have been reported. Traumatic urethral catheterization is rarely encountered in women. To our knowledge, injury to the ureter as a result of urethral catheterization is very rare. The authors cannot explain the cause of the present complication. Because the ureteral orifice was orthotopically located, direct insertion of a 14-Fr catheter, a large device, into the ureter through the ureteral orifice without pretreatment or mechanical dilatation is completely unexpected. It is unclear whether the right ureteric orifice was patulous at the time of catheterization. Urethral catheterization into the ureter is more common when the patient is catheterized on an empty bladder (5). The only way to avoid such injury would be adherence to the basic principles of catheterization, e.g., to confirm the location of the balloon before inflation, by the aspiration of urine.

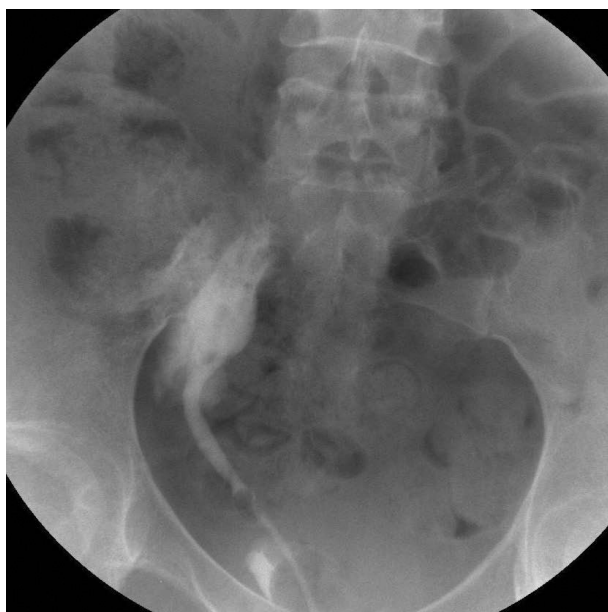


Fig. 1. Instillation of contrast media through a Foley catheter to assess proper positioning. The foley catheter tip was found in the right lower ureter, and there was extravasation of contrast media around the right ureter.

In conclusion, although the current case is an extremely rare example, we should perform urethral catheterization with particular care.

### ACKNOWLEDGMENT

We thank Jennifer Macke for assistance in editing the text.

### REFERENCES

1. Lowthian P. *An uncommon complication of urethral catheterization.*

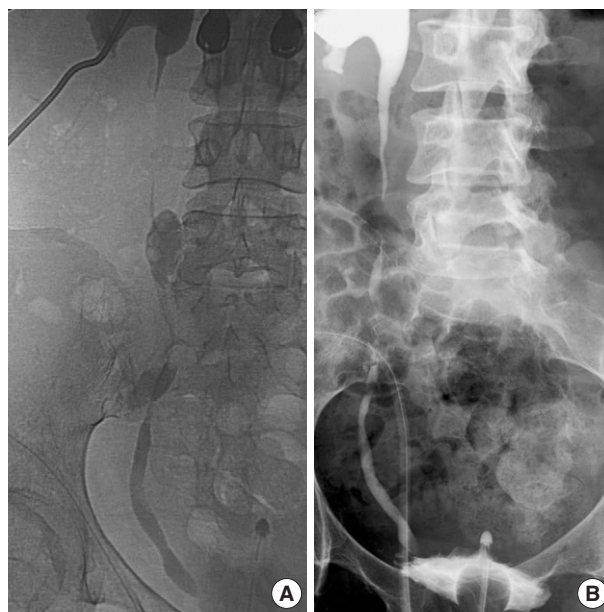


Fig. 2. (A) Antegrade urography shows proper positioning of the nephrostomy catheter and the injured ureter site. (B) Two weeks later, follow-up antegrade urography showed that the injured ureter was healed without leakage or obstruction.

*Br J Urol* 1996; 78: 805.

2. St Luce S, Ninan AC, Hall JA, Kimberl IJ, Petros JA, Issa MM. *Role of transrectal ultrasonography in diagnosis and treatment of retained Foley catheter.* *Urology* 2005; 65: 1001.
3. Merguerian PA, Erturk E, Hulbert WC, Davis RS, May A, Cockett AT. *Peritonitis and abdominal free air due to intraperitoneal bladder perforation associated with indwelling urethral catheter drainage.* *J Urol* 1985; 134: 747-50.
4. O'Gorman S, O'Brien A, Leahy A, Butler MR, Keane FB. *Rectovesical fistula due to indwelling catheter.* *Br J Urol* 1990; 65: 424.
5. Lowthian P. *Aberrant Foley catheter placement into the proximal right ureter.* *BJU Int* 2002; 90: 475-6.