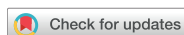

Images in
Cardiovascular Medicine



Unexpected Stenosis within Significantly Enlarged Distal Vessel after Successful Coronary Chronic Total Occlusion Recanalization

Pil Hyung Lee , MD¹, Seung-Whan Lee , MD¹, Maoto Habara , MD², and
Kenya Nasu , MD²

¹Division of Cardiology, Department of Internal Medicine, Asan Medical Center, University of Ulsan College of Medicine, Seoul, Korea

²Department of Cardiovascular Medicine, Toyohashi Heart Center, Aichi, Japan

OPEN ACCESS

Received: Dec 6, 2018

Revised: Jan 17, 2019

Accepted: Jan 30, 2019

Correspondence to

Seung-Whan Lee, MD

Division of Cardiology, Department of Internal Medicine, Asan Medical Center, University of Ulsan College of Medicine, 88, Olympic-ro 43-gil, Songpa-gu, Seoul 05505, Korea.

E-mail: seungwlee@amc.seoul.kr

Copyright © 2019. The Korean Society of Cardiology

This is an Open Access article distributed under the terms of the Creative Commons Attribution Non-Commercial License (<https://creativecommons.org/licenses/by-nc/4.0>) which permits unrestricted noncommercial use, distribution, and reproduction in any medium, provided the original work is properly cited.

ORCID iDs

Pil Hyung Lee

<https://orcid.org/0000-0001-7339-9188>

Seung-Whan Lee

<https://orcid.org/0000-0002-2662-5952>

Maoto Habara

<https://orcid.org/0000-0002-5905-9715>

Kenya Nasu

<https://orcid.org/0000-0002-9357-3582>

Conflict of Interest

The authors have no financial conflicts of interest.

Author Contributions

Conceptualization: Lee PH, Lee SW.

Methodology: Lee PH. Supervision: Lee SW,

Coronary vessels distal to chronic total occlusion (CTO) are frequently accompanied by diffuse luminal narrowing induced by negative remodeling or atherosclerotic plaque. Although flow-mediated vasodilation is anticipated after effective antegrade flow restoration,¹⁾ final vasomotor response of distal segment is often unexpected and should be considered in the stenting strategy.

A 48-year-old man, a heavy smoker with dyslipidemia and hypertension, was referred after failed percutaneous coronary intervention (PCI) of CTO in the right coronary artery (**Figure 1A**). CTO-PCI was attempted via primary retrograde approach through a septal collateral because

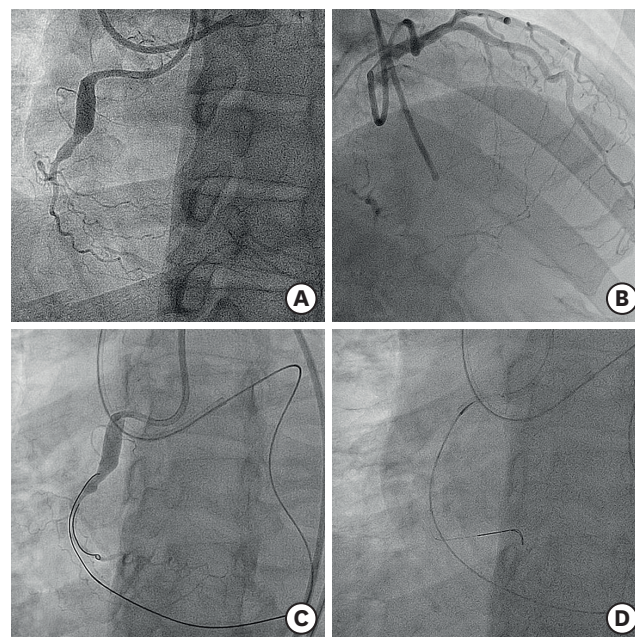


Figure 1. Baseline coronary angiography and procedure. (A) Diagnostic coronary angiography demonstrated CTO of the right coronary artery. (B) Because of the ambiguous proximal cap, a retrograde approach through a septal collateral was selected. (C) Direct wire crossing technique with an intermediate stiff Ultimate Bros 3 (Asahi Intecc, Aichi, Japan) guidewire was used to cross the CTO lesion. (D) Retrograde wire was externalized into the guiding catheter.
CTO = chronic total occlusion.

Habara M, Nasu K. Validation: Lee PH, Habara M, Nasu K. Writing - original draft: Lee PH. Writing - review & editing: Lee PH, Lee SW, Habara M, Nasu K.

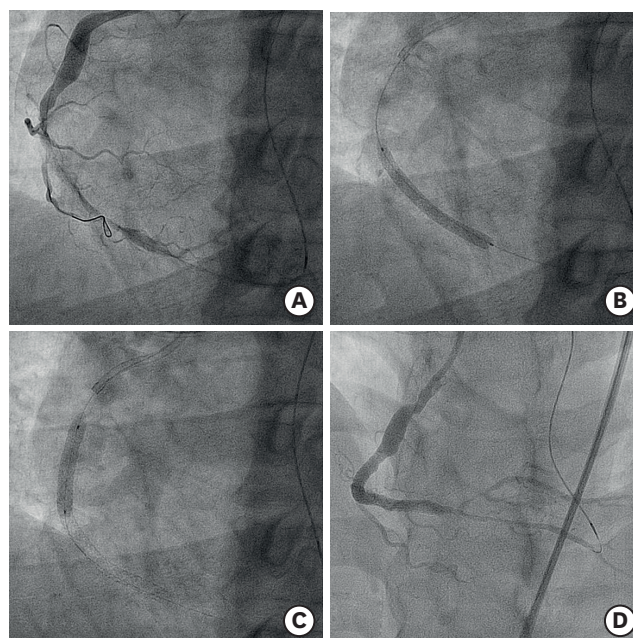


Figure 2. Stent implantation and final result. (A) A distal landing zone was identified after predilation of the CTO lesion. (B, C) Two drug-eluting stents (Resolute Onyx, 4.0×22 and 3.5×38 mm) were implanted in the middle segment of the right coronary artery. (D) Final result with angiographic evidence of diffuse luminal narrowing of distal bed (**Supplementary Video 1**). CTO = chronic total occlusion.

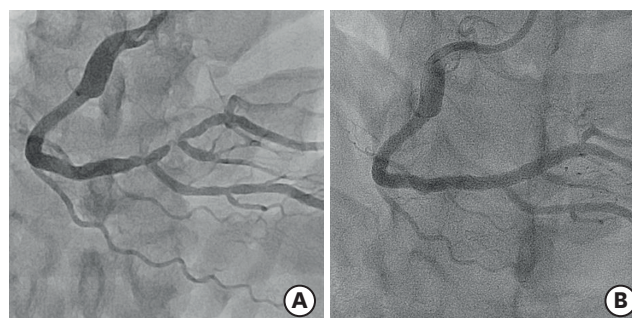


Figure 3. Angiographic follow-up. (A) A 9-month angiographic follow-up showed a significant improvement in the diameter of the whole distal bed, with an unexpected severe “true” stenosis within the enlarged vessel. (B) A 3.5×30 mm Resolute Onyx stent was used to treat the lesion (**Supplementary Videos 2 and 3**).

of ambiguous proximal cap (**Figure 1B-D**). PCI was successful with two drug-eluting stent implantation, 4.0×22 and 3.5×38 mm, in the middle segment (**Figure 2A-C**). Diffuse luminal narrowing at the distal bed persisted after flow restoration and repeated intracoronary nitroglycerin administrations (**Figure 2D, Supplementary Video 1**). Angiographic follow-up at 9 months showed significant improvement in the whole distal bed diameter with unexpected “true” tight stenoses within the enlarged vessel (**Figure 3A, Supplementary Video 2**). These lesions were successfully treated with another 3.5×30 mm stent (**Figure 3B, Supplementary Video 3**).

The treatment strategy has been inconsistent for luminal narrowing distal to CTO lesion, which undergoes variable degrees of diameter improvement after successful CTO recanalization.²⁾ Predicting the original distal bed vessel size or differentiating the vessel shrinkage and plaque burden contribution to luminal narrowing is difficult owing to limited

practical methods,³⁾ watchful waiting with follow-up angiography is a reasonable strategy to decide the final treatment for such lesions.

SUPPLEMENTARY MATERIALS

Supplementary Video 1

Persistent luminal narrowing of distal bed after flow restoration

[Click here to view](#)

Supplementary Video 2

Unexpected “true” tight stenoses within the enlarged vessel at 9-month follow-up

[Click here to view](#)

Supplementary Video 3

Successful implantation of a 3.5×30 mm stent in the distal segment

[Click here to view](#)

REFERENCES

1. Galassi AR, Tomasello SD, Crea F, et al. Transient impairment of vasomotion function after successful chronic total occlusion recanalization. *J Am Coll Cardiol* 2012;59:711-8.
[PUBMED](#) | [CROSSREF](#)
2. Zivelonghi C, Suttorp MJ, Teeuwen K, et al. Clinical implications of distal vessel stenosis after successful coronary chronic total occlusion recanalization. *JACC Cardiovasc Interv* 2018;11:2343-5.
[PUBMED](#) | [CROSSREF](#)
3. Neishi Y, Okura H, Kume T, Fukuhara K, Yamada R, Yoshida K. Prediction of chronic vessel enlargement by a novel intravascular ultrasound finding. *Circ J* 2015;79:607-12.
[PUBMED](#) | [CROSSREF](#)