

Review Article



Treatment of Femoropopliteal Artery In-stent Restenosis

Wonho Kim , MD¹ and Donghoon Choi , MD, PhD²

¹Division of Cardiology, Eulji University Hospital, Eulji University School of Medicine, Daejeon, Korea

²Division of Cardiology, Department of Internal Medicine, Severance Cardiovascular Hospital, Yonsei University College of Medicine, Seoul, Korea



Received: Mar 1, 2018

Accepted: Mar 6, 2018

Correspondence to

Donghoon Choi, MD, PhD

Division of Cardiology, Department of Internal Medicine, Severance Cardiovascular Hospital, Yonsei University College of Medicine, 50-1, Yonsei-ro, Seodaemun-gu, Seoul 03722, Korea.
E-mail: cdhlyj@yuhs.ac

Copyright © 2018. The Korean Society of Cardiology

This is an Open Access article distributed under the terms of the Creative Commons Attribution Non-Commercial License (<https://creativecommons.org/licenses/by-nc/4.0>) which permits unrestricted noncommercial use, distribution, and reproduction in any medium, provided the original work is properly cited.

ORCID iDs

Wonho Kim
<https://orcid.org/0000-0003-0704-6901>
Donghoon Choi
<https://orcid.org/0000-0002-2009-9760>

Conflict of Interest

The authors have no financial conflicts of interest.

Author Contributions

Writing - original draft: Kim W; Writing - review & editing: Choi D.

ABSTRACT

Femoropopliteal (FP) artery-in stent restenosis (ISR) is a daunting management problem that we continue to face. FP artery-ISR rates after primary stent implantation are relatively high. Although repeat FP artery-ISR and the need for additional interventions remain all too common, little consensus exists regarding the best treatment algorithm. In this article, we review the limitations of the currently used devices for the endovascular treatment of FP artery-ISR and discuss which strategies are the most effective and safe.

Keywords: Peripheral artery disease

INTRODUCTION

Atherosclerotic disease in the femoropopliteal (FP) artery consists of perfusion to the legs and feet. Percutaneous transluminal angioplasty (PTA) has been routinely used to manage FP artery disease and is recommended as an alternative to surgical bypass. Recently, newer endovascular approaches such as covered stent, drug-eluting balloon (DEB), drug-eluting stent (DES), or catheter based atherectomy have been introduced as treatment options for FP artery disease. Nevertheless, FP artery-in stent restenosis (ISR) is still a major challenge with endovascular therapy. Limited data exist on the risk factors for FP artery-ISR that require target lesion revascularization (TLR) or target vessel revascularization (TVR) after endovascular revascularization in FP artery disease.^{1,2)} The goal of this article is to help the practicing cardiovascular interventionist consider the optimal choices for the management of patients with FP artery-ISR.

PATHOPHYSIOLOGY OF FP ARTERY-ISR

FP artery is the most common arterial segment treated by endovascular therapy.³⁾ Endovascular therapy for FP artery disease, at least in Korea, has been largely limited to conventional balloon angioplasty (BA) or (nitinol) self-expandable stent implantation, and these are considered safe and relatively effective therapies.³⁾ After BA or self-expandable stent implantation, the local vasculature reacts with an inflammatory response that precipitates neointimal hyperplasia (NIH).⁴⁾ In addition to lesion-specific factors, such as a longer lesion

length and smaller vessel diameter, patient characteristics, including diabetes mellitus and smoking history, can increase the risk of ISR.^{5,6)} Although the use of self-expandable stents has improved the patency rate of PTA in FP artery disease, the incidence of FP artery-ISR ranges from 15% to 32%, and a FP artery-ISR peak seems to occur between 9 and 15 months after PTA. After 2 years, the occurrence of FP artery-ISR is low, and probably, the lesions are more related to the evolution of atheromatous disease rather than NIH.^{7,8)} Stent implantations are associated with mechanical stressors including vessel elongation, torsion, flexion, and extension increasing the risk of the development of FP artery-ISR. In particular, the distal one-third of the FP artery has poorer endovascular patency rates.⁹⁾

WHICH IS CURRENTLY THE BEST STRATEGY FOR THE TREATMENT OF FP ARTERY-ISR?

A number of endovascular treatments and tools are available in the interventionists' armamentarium for treating FP artery-ISR, such as repeat BA or stent implantation (with a self-expandable stent, covered stent, or DES), cutting or scoring balloon angioplasties angioplasty, cryoplasty, and catheter based atherectomy, all providing good immediate success rates (**Table 1**). Nevertheless, no standard treatment exists for the treatment of FP artery-ISR.

DEB

They is standard BA Catheter surface coated with a thin layer of anti-proliferative drug combined with an excipient or spacer substance, which facilitates drug transfer to the vessel wall.¹⁰⁾ Randomized trials have shown that DEB for FP artery disease is associated with less restenosis and TLR than conventional BA.¹¹⁾ In the treatment of FP artery-ISR, the advantages of DEB include drug delivery and inhibition of NIH, more uniform drug-tissue transfer and potential amelioration of vessel healing due to the absence of a pro-inflammatory durable polymer surface coating. Recently, several randomized trials comparing DEB with conventional BA for the treatment of FP artery-ISR have been reported. Most previously assessed data on FP artery-ISR treatment with DEB have been convincing (**Figure 1**). The Femoral Artery In-Stent Restenosis (FAIR) trial showed that DEB for FP artery-ISR was associated with less recurrent restenosis and a better clinical outcome than conventional BA without an apparent difference in safety issue.¹²⁾ Freedom from TLR was significantly higher in

Table 1. Endovascular treatment or FP artery-ISR

BA
Conventional BA
Cutting BA
DEB angioplasty
Stent in stent
(Nitinol) self-expandable stent implantation
DES implantation
Catheter based atherectomy
Laser atherectomy
Directional atherectomy
Rotational atherectomy
Bypass surgery

BA = balloon angioplasty; DEB = drug-eluting balloon; DES = drug-eluting stent; FP = femoropopliteal; ISR = in stent restenosis.

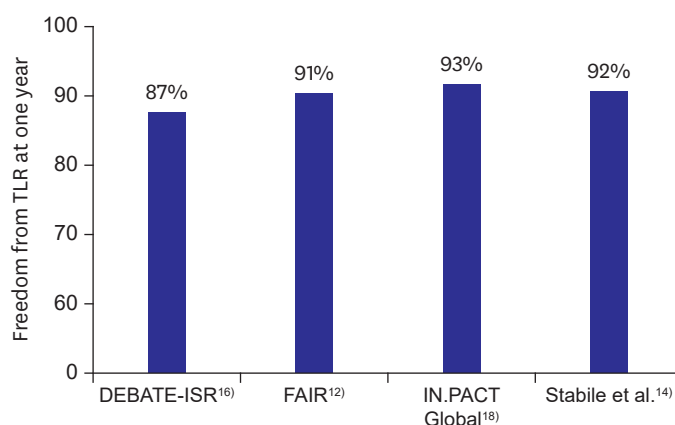


Figure 1. Freedom from TLR at one year in patients with FP artery-ISR.

DEBATE-ISR = Drug-Eluting Balloon in peripheral inTervention for In-Stent Restenosis; FAIR = Femoral Artery In-Stent Restenosis; FP = femoropopliteal; ISR = in stent restenosis; TLR = target lesion revascularization.

the DEB group than in the conventional BA group (90.8% vs. 52.6% at 12 months; $p < 0.001$). In the Paclitaxel Balloon Versus Standard Balloon in In-Stent Restenoses of the Superficial Femoral Artery (PACUBA) trial, the 12-month primary patency rates were 40.7% (95% confidence interval [CI], 0.26–0.64) versus 13.4% (95% CI, 0.05–0.36) (log-rank $p = 0.02$) in the DEB versus conventional BA group.¹³⁾ Data from a single center showed a one year primary patency rate of 92.1%, regarding the role of DEB in the treatment of FP artery-ISR.¹⁴⁾ In a 2-year follow-up, a primary patency rate of 70.3% was observed.¹⁵⁾ In the Drug-Eluting Balloon in peripheral inTervention for In-Stent Restenosis (DEBATE-ISR) trial, the use of DEB for the treatment of FP artery-ISR showed a significant reduction in restenosis recurrence compared with conventional BA.¹⁶⁾ At 1 year, the TLR rates were 13% in the DEB group and 31% in the conventional BA group ($p = 0.045$). However, the use of DEB for treatment of FP artery-ISR had similar results as conventional BA in terms of the TLR after 3 years of follow-up suggesting a late catch-up phenomenon between 1 and 3 years of follow-up.¹⁷⁾ Recently, the IN.PACT Global study showed that the rate of clinically driven TLR at 1 year was 7.3%, with the use of DEB for the treatment of patients with FP artery-ISR.¹⁸⁾ The use of DEB as the primary treatment of FP artery-ISR has the following advantages. First, DEB provides local delivery of a target-specific drug with theoretical application to the entire arterial surface. Second, its use avoids the downside of a catheter based atherectomy, such as potential embolization or vessel rupture. Third, prolonged DEB inflation enhances the short-term patency outcome in the literature. Fourth, DEBs leave nothing behind and lower metallic stent utilization. Nevertheless, recurrent ISR following the use of DCB is a problem that needs to be considered.

DES

Three different types of stents are available in real clinical practice, a (nitinol) self-expandable stent, covered stent (stent graft), and DES. The use of a covered stent is an additional tool to treat FP artery-ISR. Some retrospective studies have shown favorable results with covered stents.¹⁹⁾²⁰⁾ However, the efficacy of a covered stent in the treatment of FP artery-ISR has not been fully demonstrated yet. Data evaluating the use DEB for FP artery-ISR are relatively sparse. Few studies have investigated the role of DES for the treatment of FP artery-ISR. In Zilver PTX (Cook Medical, Bloomington, IN, USA), the treatment of 119 FP artery-ISR lesions with a paclitaxel-eluting stent had an estimated primary patency rate of 95.7% at 6

months and 78.8% at 1 year.²¹⁾ A retrospective study compared conventional BA with DES implantation for FP artery-ISR. At 2 years, the Kaplan-Meier estimated freedom from the recurrent ISR rates were 79.3% in the DES group and 20.2% in the conventional BA group, respectively ($p < 0.001$).²²⁾ One study compared DES implantation with conventional BA in the treatment of FP artery-ISR. DES implantation was associated with significantly lower incidences of recurrent restenosis (44.1% vs. 90.3%; $p < 0.001$).²³⁾ Many operators advocate a strategy of avoiding repeat stent implantation among patients with FP artery-ISR. When flow-limiting dissection occurs in a subset of patients undergoing conventional BA, then repeat stent implantation may be necessary to maintain an adequate luminal flow. In this condition, DES implantation is strongly recommended over self-expandable stent implantation.

MECHANICAL DEBULKING WITH A CATHETER BASED ATHERECTOMY DEVICE

Unlike balloons and stents, which push plaque into the vessel wall, atherectomy offers the ability to debulk the plaque burden within the vessel.²⁴⁾ Laser atherectomy uses high energy, a monochromatic light beam, to alter or dissolve the atheromatous plaque without damaging the surrounding tissue. The EXCIMER Laser Randomized Controlled Study for Treatment of Femoropopliteal In-Stent Restenosis (EXCITE ISR) study showed the superiority of the combination of laser atherectomy and conventional BA versus conventional BA alone for treating FP artery-ISR.²⁵⁾ In the SALVAGE study, the strategy of laser atherectomy and conventional BA for the treatment of FP artery-ISR was safe and associated with high procedural success.²⁶⁾ However, the use of laser atherectomy is not widely available in Korea.

Directional atherectomy is considered a minimally invasive treatment that removes atheromatous plaques and restores blood flow in the native FP artery. Two types of directional atherectomy devices are available, the SilverHawk™ system (Medgadget, Eugene, OR, USA) and TurboHawk™ system (Medtronic, Minneapolis, MN, USA). They are forward cutting directional atherectomy devices with a rotating blade inside a tubular housing with a collection area (nosecone). In directional atherectomy, however, the theoretical advantage of minimizing repetitive barotrauma to the vessel wall and inhibition of NIH have not been achieved as clinical benefits in the treatment of FP artery-ISR. On the other hand, the JetStream™ atherectomy device (Boston Scientific, Marlborough, MA, USA) is a rotational atherectomy system. This device uniquely combines rotablation with an aspiration capability. The use of JetStream atherectomy showed favorable acute results in treating FP artery-ISR with high procedure success, no device-stent interaction, and favorably low TLR rates. The incidence of primary patency was 72% at 6 months.²⁷⁾

COMBINED TREATMENTS WITH CATHETER BASED ATHERECTOMY AND CONVENTIONAL BA

The combination of catheter based atherectomy with the subsequent use of DEB has the advantage of combined debulking and neointimal modification from atherectomy plus the enhanced anti-restenotic effect of DEB angioplasty. The efficacies of this strategy are published by some authors.²⁸⁾²⁹⁾ The patency rate at 1 year were between 66.7% and 84.7%. This is much better than the use of atherectomy devices alone as a single treatment strategy for FP artery-ISR (**Figure 2**).

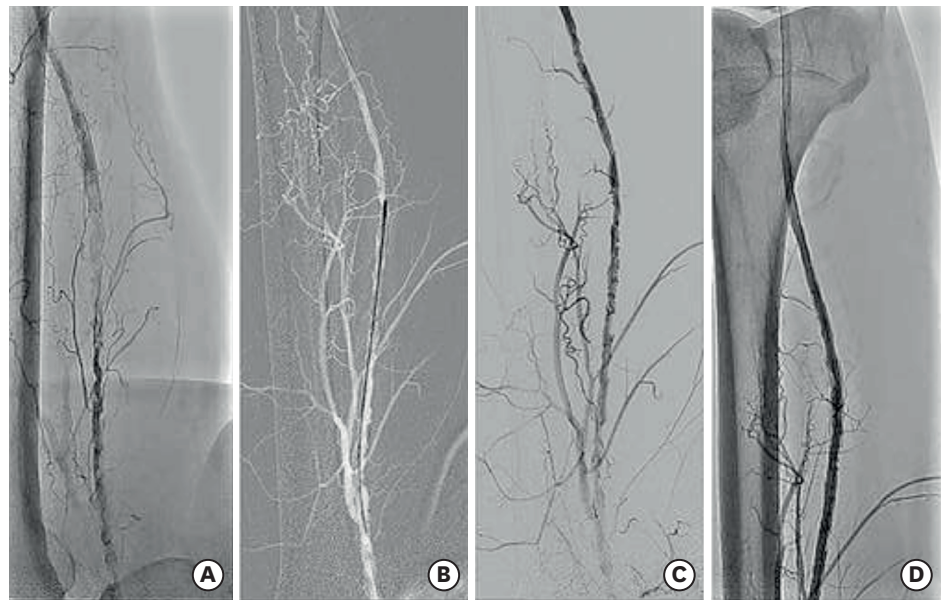


Figure 2. Combination of mechanical atherectomy and DEB angioplasty for FP artery-ISR. (A) Stented fully occluded distal to mid superficial femoral artery. (B) Two passes blades-down, 2 passes blades-up with JetStream atherectomy device. (C) Follow-up angiogram showing residual stenoses. (D) Blood flow fully restored after DEB angioplasty.

DEB = drug-eluting balloon; FP = femoropopliteal; ISR = in stent restenosis.

CONCLUSION

The endovascular treatment of FP artery-ISR has increased over the years and will keep on increasing in the future. Many endovascular devices have been developed and are currently in use. There are still mixed findings on the outcomes after endovascular treatment of FP artery-ISR. Although repeat FP artery-ISR and the need for additional interventions remain all too common, little consensus exists regarding the best treatment algorithm. The use of DEB could be recommended as the first choice of devices to treat FP artery-ISR because of its efficacy and ease of use. In complex lesions, such as in-stent total occlusion and critical limb ischemia with diabetes, DES implantation might be another option. Directional atherectomy for FP artery-ISR seems to be limited by a low patency rate. However, some data suggest that the use of rotational atherectomy is safe and effective. Another field of improvement is the use of drug-eluting devices in association to rotational atherectomy which need to be further evaluated.

REFERENCES

1. Shamma NW. An overview of optimal endovascular strategy in treating the femoropopliteal artery: mechanical, biological, and procedural factors. *Int J Angiol* 2013;22:1-8.
[PUBMED](#) | [CROSSREF](#)
2. Tosaka A, Soga Y, Iida O, et al. Classification and clinical impact of restenosis after femoropopliteal stenting. *J Am Coll Cardiol* 2012;59:16-23.
[PUBMED](#) | [CROSSREF](#)
3. Ko YG, Ahn CM, Min PK, et al. Baseline characteristics of a retrospective patient cohort in the Korean Vascular Intervention Society Endovascular Therapy in Lower Limb Artery Diseases (K-VIS ELLA) Registry. *Korean Circ J* 2017;47:469-76.
[PUBMED](#) | [CROSSREF](#)

4. Hoffmann R, Mintz GS, Dussallant GR, et al. Patterns and mechanisms of in-stent restenosis. A serial intravascular ultrasound study. *Circulation* 1996;94:1247-54.
[PUBMED](#) | [CROSSREF](#)
5. Mehran R, Dangas G, Abizaid AS, et al. Angiographic patterns of in-stent restenosis: classification and implications for long-term outcome. *Circulation* 1999;100:1872-8.
[PUBMED](#) | [CROSSREF](#)
6. Scheinert D, Scheinert S, Sax J, et al. Prevalence and clinical impact of stent fractures after femoropopliteal stenting. *J Am Coll Cardiol* 2005;45:312-5.
[PUBMED](#) | [CROSSREF](#)
7. Dake MD, Ansel GM, Jaff MR, et al. Paclitaxel-eluting stents show superiority to balloon angioplasty and bare metal stents in femoropopliteal disease: twelve-month Zilver PTX randomized study results. *Circ Cardiovasc Interv* 2011;4:495-504.
[PUBMED](#) | [CROSSREF](#)
8. Laird JR, Katzen BT, Scheinert D, et al. Nitinol stent implantation versus balloon angioplasty for lesions in the superficial femoral artery and proximal popliteal artery: twelve-month results from the RESILIENT randomized trial. *Circ Cardiovasc Interv* 2010;3:267-76.
[PUBMED](#) | [CROSSREF](#)
9. Shishehbor MH. Endovascular treatment of femoropopliteal lesions: so many options, little consensus. *J Am Coll Cardiol* 2015;66:2339-42.
[PUBMED](#) | [CROSSREF](#)
10. Byrne RA, Joner M, Alfonso F, et al. Drug-coated balloon therapy in coronary and peripheral artery disease. *Nat Rev Cardiol* 2014;11:13-23.
[PUBMED](#) | [CROSSREF](#)
11. Cassese S, Byrne RA, Ott I, et al. Paclitaxel-coated versus uncoated balloon angioplasty reduces target lesion revascularization in patients with femoropopliteal arterial disease: a meta-analysis of randomized trials. *Circ Cardiovasc Interv* 2012;5:582-9.
[PUBMED](#) | [CROSSREF](#)
12. Krankenberg H, Tübler T, Ingwersen M, et al. Drug-coated balloon versus standard balloon for superficial femoral artery in-stent restenosis: the randomized Femoral Artery In-stent Restenosis (FAIR) trial. *Circulation* 2015;132:2230-6.
[PUBMED](#) | [CROSSREF](#)
13. Kinstner CM, Lammer J, Willfort-Ehringer A, et al. Paclitaxel-eluting balloon versus standard balloon angioplasty in in-stent restenosis of the superficial femoral and proximal popliteal artery: 1-year results of the PACUBA trial. *JACC Cardiovasc Interv* 2016;9:1386-92.
[PUBMED](#) | [CROSSREF](#)
14. Stabile E, Virga V, Salemme L, et al. Drug-eluting balloon for treatment of superficial femoral artery in-stent restenosis. *J Am Coll Cardiol* 2012;60:1739-42.
[PUBMED](#) | [CROSSREF](#)
15. Virga V, Stabile E, Biamino G, et al. Drug-eluting balloons for the treatment of the superficial femoral artery in-stent restenosis: 2-year follow-up. *JACC Cardiovasc Interv* 2014;7:411-5.
[PUBMED](#) | [CROSSREF](#)
16. Liistro F, Angioli P, Porto I, et al. Paclitaxel-eluting balloon vs. standard angioplasty to reduce recurrent restenosis in diabetic patients with in-stent restenosis of the superficial femoral and proximal popliteal arteries: the DEBATE-ISR study. *J Endovasc Ther* 2014;21:1-8.
[PUBMED](#) | [CROSSREF](#)
17. Grotti S, Liistro F, Angioli P, et al. Paclitaxel-eluting balloon vs standard angioplasty to reduce restenosis in diabetic patients with in-stent restenosis of the superficial femoral and proximal popliteal arteries: three-year results of the DEBATE-ISR study. *J Endovasc Ther* 2016;23:52-7.
[PUBMED](#) | [CROSSREF](#)
18. Brodmann M, Keirse K, Scheinert D, et al. Drug-coated balloon treatment for femoropopliteal artery disease: the IN.PACT global study de novo in-stent restenosis imaging cohort. *JACC Cardiovasc Interv* 2017;10:2113-23.
[PUBMED](#) | [CROSSREF](#)
19. Bosiers M, Deloose K, Keirs K, et al. Prevention and treatment of in-stent restenosis. *J Cardiovasc Surg (Torino)* 2010;51:591-8.
[PUBMED](#)
20. Gorgani F, Telis A, Narakathu N, et al. Long-term outcomes of the Viabahn stent in the treatment of in-stent restenosis in the superficial femoral artery. *J Invasive Cardiol* 2013;25:670-4.
[PUBMED](#)

21. Zeller T, Dake MD, Tepe G, et al. Treatment of femoropopliteal in-stent restenosis with paclitaxel-eluting stents. *JACC Cardiovasc Interv* 2013;6:274-81.
[PUBMED](#) | [CROSSREF](#)
22. Tomoi Y, Soga Y, Iida O, et al. Impact of drug-eluting stent implantation for femoropopliteal in-stent occlusion. *J Endovasc Ther* 2016;23:461-7.
[PUBMED](#) | [CROSSREF](#)
23. Murata N, Takahara M, Soga Y, et al. Drug-eluting stent vs percutaneous transluminal angioplasty for treatment of femoropopliteal in-stent restenosis: results from a retrospective 1-year multicenter study. *J Endovasc Ther* 2016;23:642-7.
[PUBMED](#) | [CROSSREF](#)
24. Katsanos K, Spiliopoulos S, Reppas L, et al. Debulking atherectomy in the peripheral arteries: is there a role and what is the evidence? *Cardiovasc Intervent Radiol* 2017;40:964-77.
[PUBMED](#) | [CROSSREF](#)
25. Dippel EJ, Makam P, Kovach R, et al. Randomized controlled study of excimer laser atherectomy for treatment of femoropopliteal in-stent restenosis: initial results from the EXCITE ISR trial (EXCimer Laser Randomized Controlled Study for Treatment of Femoropopliteal In-Stent Restenosis). *JACC Cardiovasc Interv* 2015;8:92-101.
[PUBMED](#) | [CROSSREF](#)
26. Laird JR Jr, Yeo KK, Rocha-Singh K, et al. Excimer laser with adjunctive balloon angioplasty and heparin-coated self-expanding stent grafts for the treatment of femoropopliteal artery in-stent restenosis: twelve-month results from the SALVAGE study. *Catheter Cardiovasc Interv* 2012;80:852-9.
[PUBMED](#) | [CROSSREF](#)
27. Shammas NW, Shammas GA, Banerjee S, et al. JetStream rotational and aspiration atherectomy in treating in-stent restenosis of the femoropopliteal arteries: results of the JETSTREAM-ISR feasibility study. *J Endovasc Ther* 2016;23:339-46.
[PUBMED](#) | [CROSSREF](#)
28. Sixt S, Carpio Cancino OG, Treszl A, et al. Drug-coated balloon angioplasty after directional atherectomy improves outcome in restenotic femoropopliteal arteries. *J Vasc Surg* 2013;58:682-6.
[PUBMED](#) | [CROSSREF](#)
29. Gandini R, Del Giudice C, Merolla S, et al. Treatment of chronic SFA in-stent occlusion with combined laser atherectomy and drug-eluting balloon angioplasty in patients with critical limb ischemia: a single-center, prospective, randomized study. *J Endovasc Ther* 2013;20:805-14.
[PUBMED](#) | [CROSSREF](#)