

Toad Venom Poisoning Resembling Digitalis Intoxication and Hyperkalemia: A Case Report

Dae Woo Hyun, MD, Taek Geun Kwon, MD, Ki Young Kim, MD and Jang Ho Bae, MD

Division of Cardiology, The Heart Center, College of Medicine, Konyang University Hospital, Daejeon, Korea

ABSTRACT

Toad toxin has digitalis-like cardioactive effects that include bradycardia, varying degrees of atrioventricular block, ventricular tachycardia, ventricular fibrillation and sudden cardiac death. We report here on a 54-year-old man who had varying degrees of atrioventricular block and nonsustained ventricular tachycardia two hours after he ate a bowl of toad soup. (*Korean Circulation J* 2007;37:283–286)

KEY WORDS : Toad venoms ; Digitalis.

Introduction

Chan Su or Senso is a traditional Chinese medicine and it is prepared from the dried white secretion of the auricular glands and the skin glands of Toad.¹⁾ The extracts of toad stimulate myocardial contraction and they have anesthetic and antibiotic actions, so they were used for the treatment of dyspnea, edema, palpitation, tonsillitis, sore throat, toothache and sinusitis.¹⁾²⁾

The cardiotonic components in toad venom consisted of bufogenins, bufadienolides or bufotoxins, and these components serve as cardioactive steroids; their structure are similar to those of the conventional cardiac glycosides such as digoxin.³⁾ Bufotoxins have the ability to inhibit the activity of the membrane enzyme sodium-potassium adenosine triphosphatase(Na⁺/K⁺-ATPase).⁴⁾ The patients who overdose with toad medical preparations experience symptoms that are similar to the effects of digoxin intoxication, such as nausea, vomiting, general malaise, tachybradyarrhythmia and cardiopulmonary arrest.¹⁻³⁾⁵⁾

We report here on a case of the toad venom poisoning that showed various degrees of atrioventricular(AV) block and nonsustained ventricular tachycardia(VT).

Case

A 54-year-old man was referred to our hospital due to nausea and vomiting. He had prepared toad soup with two toads for lunch and he ate the soup with makgeolri, raw rice wine. After about 30 minutes after ingestion, he began to suffer from nausea, vomiting, dizziness and numbness over the oral mucosa and both extremities. He visited a local hospital and was referred to our hospital without any preliminary management.

He arrived at our emergency department 2 hours after he ate the toad soup. Physical examination revealed an alert mental status, the blood pressure was 80/40 mmHg, the heart rate was irregular at 36 beats per minute and the body temperature was 36.6°C. The electrocardiogram (ECG) showed varying degrees of AV block, and there was PR prolongation and a tent-shaped T wave(Fig. 1A). The laboratory data revealed a white blood cell count of 12,960/mm³ with 72.5% neutrophils, the hemoglobin was 14.9 gm/dL, the sodium was 132 mmol/L, the potassium 6.09 mmol/L and the creatinine 1.25 mg/dL. His serum digoxin level was 1.62 ng/mL(the therapeutic range of digoxin is from 0.8 ng/dL to 2.0 ng/mL) and he had no previous medication history. He underwent gastric lavage with activated charcoal and an intravenous infusion of the insulin and 20% dextrose for the management of hyperkalemia and to induce temporary pacing. After a bolus injection of atropine, the ECG showed the 1 : 1, prolonged AV conduction(Fig. 2). During his medical management, the electrocardiogram showed nonsustained monomorphic VT(Fig. 3) 4 hours after he ate the toad soup.

The second day of the admission, the potassium level

Received : April 5, 2007

Revision Received : May 23, 2007

Accepted : May 24, 2007

Correspondence : Dae Woo Hyun, MD, Division of Cardiology, College of Medicine, Konyang University Hospital, 685 Gasuwon-dong, Seo-gu, Daejeon 302-718, Korea

Tel: 82-42-600-9400, Fax: 82-42- 600-9420

E-mail: hyundw@kyuh.co.kr

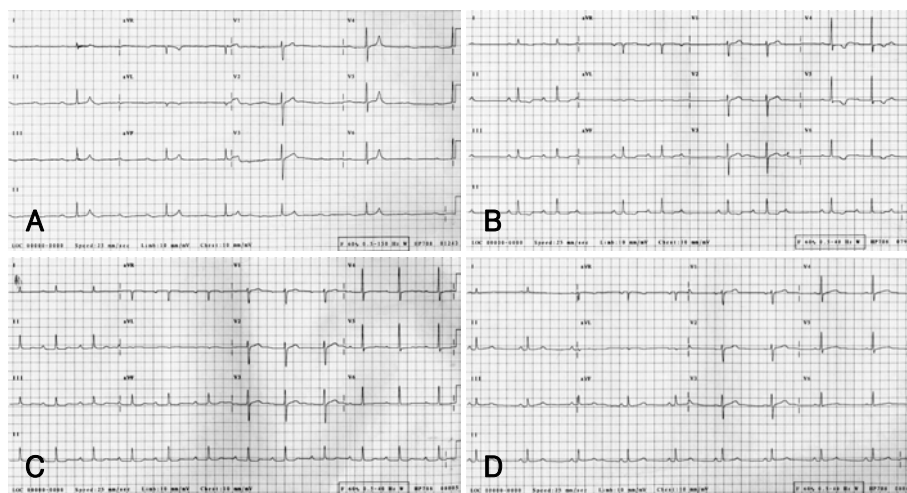


Fig. 1. The serial electrocardiogram changes during admission. A: on admission, the electrocardiogram showed high degree atrioventricular block (AV) and PR prolongation. B: two days after admission, the electrocardiogram showed Wenchebach AV block. C: thirty four hours after admission, the electrocardiogram showed first degree AV block. D: three days after admission, the electrocardiogram showed normal sinus rhythm and no abnormal findings.

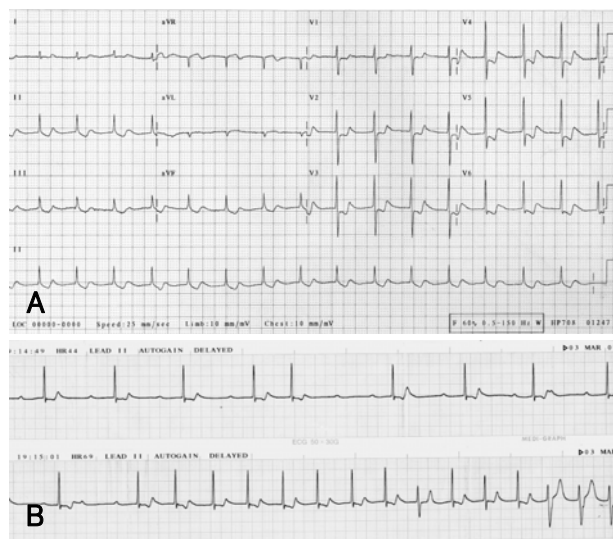


Fig. 2. Electrocardiogram after intravenous atropine injection. A: after intravenous atropine injection, the electrocardiogram showed 1 to 1 and prolonged atrioventricular (AV) conduction. B: the long strip of lead II during atropine injection showed change of the high-degree AV block to 1 to 1 AV conduction.

was 5.14 mmol/L and the digoxin level was 0.21 ng/mL. The ECG showed Wenchebach and first degree AV block (Fig. 1B, C). On the third day after admission, the potassium level was 3.71 mmol/L and the digoxin level was below 0.17 ng/mL. The ECG showed a normal PR interval and no abnormal findings (Fig. 1D). He was discharged on the fifth day of admission and he had no symptoms, abnormal laboratory tests and ECG results at discharge.

Discussion

Toads have a pair of well-defined skin glands behind

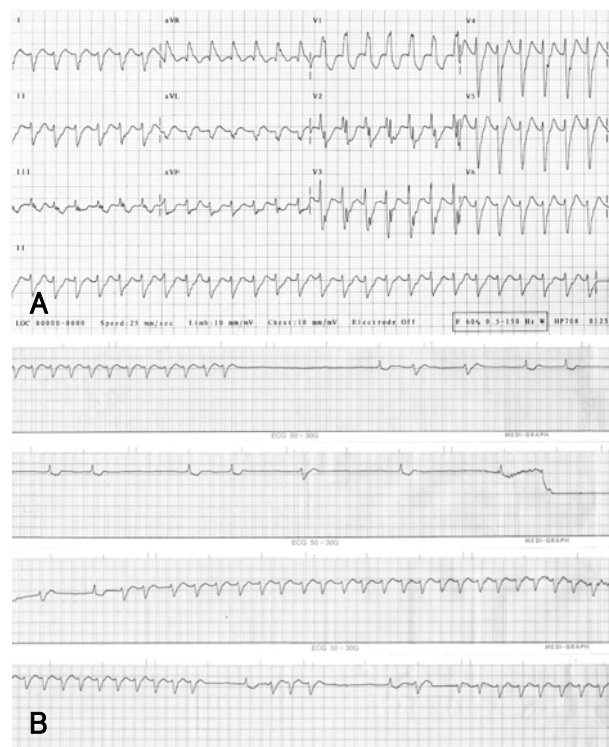


Fig. 3. Electrocardiogram four hours after toad ingestion. The electrocardiogram showed non-sustained ventricular tachycardia. A: the 12 leads surface electrocardiogram. B: a long strip of the lead II.

the eyes, and these glands secrete venom. This venom is found in the skin and plasma.¹²⁾ Previous studies have confirmed that toad venom contains several types of toxic substances.¹²⁾⁴⁻⁶⁾ These toxic substances can be divided into three groups. The first group is the bufotoxins, which have effects similar to the cardiac glycosides, and their exact mechanism of cardiotoxic activity has not been well defined. Yet their clinical activity may be related to their digitalis-like structure. Bufotoxins

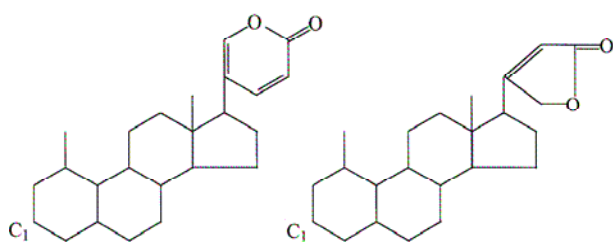


Fig. 4. Cardioactive steroids are based on a steroid nucleus with either a five (cardenolides) or six (bufadienolides) member lactone ring.

(bufadienolides) have a six member lactone ring and the cardenolides, which are cardiac glycosides derived from a plant, they have a five member lactone ring (Fig. 4). The cardioactive compounds in the second group are the catecholamines, and there are several catecholamines in toad venom. Epinephrine has been found at as high as a 5% concentration in the venom. The third group is the indolealkylamines, which include bufonine, serotonin, bufotenine, cinobufotenine and dehydobufotenine. The toxicity of toad venom cannot be abolished or reduced by heating. The signs and symptoms of toad intoxication include fever, blurred vision, a numb sensation over the oral mucosa, seizure, hallucination, dysrhythmias, nausea, vomiting, diarrhea, dizziness, mental confusion, hypotension, sinus arrest with AV block and sudden death.¹²⁾⁷⁾ These symptoms are similar to those of digitalis intoxication.

Cardiac glycoside has a positive inotropic action and it alters the electrophysiology of the heart muscle via binding to and inhibition of the enzyme Na^+/K^+ -ATPase on the surface membrane of myocardial cells.⁸⁾ When Na^+/K^+ -ATPase is inhibited, then the sodium-calcium exchanger removes accumulated intracellular sodium in exchange for calcium. This exchange increases sarcoplasmic calcium and it is the mechanism responsible for the positive inotropic effect of digitalis. Inhibition of the Na^+/K^+ -ATPase pump also results in an increase in extracellular potassium. Since the skeletal muscle, with its sheer mass, contains the major pool of Na^+/K^+ -ATPase in the body, the severity of hyperkalemia is determined by the K^+ released from the skeletal muscles.⁸⁾ Cardiac glycoside also has complex electrophysiological effects that are a combination of indirect, parasympathetic and direct effects on specialized pacemakers and conduction tissues.⁹⁾¹⁰⁾ Digoxin usually decreases the automaticity and it increases the maximal diastolic resting membrane potential in the atrial and AV nodal cells as a result of augmented vagal tone and decreased sympathetic nervous system activity. These effects are accompanied by prolongation of the effective refractory period and decreased AV nodal conduction velocity. At toxic doses, these effects result in various degrees of bradydysrhythmia and slowing of the conduction tissue, along with a decreased refractory period

of the myocardium and increased automaticity. Intracellular calcium overload creates transient depolarizations, giving rise to triggered dysrhythmias. Chi et al⁶⁾ reported that the level of serum potassium has prognostic implications for toad intoxication and if hyperkalemia develops, then the treatment of toad intoxication must be more aggressive to prevent mortality. Besides acute hyperkalemia, the characteristic ECG features may also provide important clues for the diagnosis of cardiac glycoside toxicity. The typical ECG changes include flattened or inverted T waves, shortened QT intervals, depressed ST segments and rhythmic changes. These cardiac glycoside changes may complicate or mask the typical ECG features of hyperkalemia.¹¹⁾ In our case, the ECG showed a varying degree of AV block that resembled the ECG features of digitalis intoxication, and there were narrow and tent-shaped T waves that resembled the ECG features of hyperkalemia (Fig. 1A). Hyperkalemia (6.09 mmol/L) was present in our case and we treated the patient with insulin and dextrose infusion. Digoxin toxicity can be reversed by antidigoxin immunotherapy.¹²⁾¹³⁾ Purified Fab fragments from digoxin-specific antisera are now commercially available. Brubacher et al³⁾ reported that digoxin specific Fab fragments are effective in the treatment of Chan Su poisoning and they may be effective for poisoning by other cardioactive steroids of the bufadienolide class.

Digoxin-like immunoreactive substance was detected in our patient's serum, and elevation of the serum digoxin concentration was noted when this was assayed by an immunological method.¹²⁾¹³⁾ This is possibly due to the similarity in chemical structures between toad venom and digoxin, resulting in crossreactivity of toad venom with the digoxin immunoassay antibody. The method to detect the digoxin level in our hospital is also immunological assay; digoxin was detected in the serum of our patient and he was without previous digoxin medication.

We report here on a 54-year-old man who ate toad soup and the result of the clinical symptoms and laboratory tests showed digoxin intoxication-like effects. The laboratory result showed an elevated digoxin level (1.62 ng/mL) and potassium level (6.09 mmol/L), and the electrocardiogram of the patient showed high-degree, Wenchebach and first degree atrioventricular block and nonsustained ventricular tachycardia. The patient was discharged on the 5th day without any complication after conservative management.

REFERENCES

- 1) Jensen H, Evans EA. *Chemical studies on toad poisoning. Ch'an su, the dried venom of the Chinese toad and the secretion of the tropical toad, B. marinus.* J Biol Chem 1934;104:307-16.
- 2) Lim TH, Leitch IM, Boura AL, Read MA, Walters WA. *Effects of Bufo Marinus skin toxins on human fetal extracorporeal blood vessels.* Toxicol 1997;35:293-304.

- 3) Brubacher JR, Lachmanen D, Ravikumar PR, Hoffman RS. *Efficacy of digoxin specific Fab fragments (Digibind) in the treatment of toad venom poisoning. Toxicon 1999;37:931-42.*
- 4) Flier J, Edwards MW, Daly JW, Myers CW. *Widespread occurrence in frogs and toads of skin compounds interacting with the ouabain site of Na⁺K⁺-ATPase. Science 1980;208:503-5.*
- 5) Schwartz EN, Schwartz CA, Sebben A, Largura SW, Mendes EG. *Indirect cardiotoxic activity the caecilian Siphonops paulensis (Gymnophiona, Amphibia) skin secretion. Toxicon 1999;37:47-54.*
- 6) Chi HT, Hung DZ, Hu WH, Yang DY. *Prognostic implications of hyperkalemia in toad toxin intoxication. Hum Exp Toxicol 1998; 17:343-6.*
- 7) Song CS. *The experimental studies on cardiac glycoside (Ouabain) and electrolytes. Korean Circ J 1971;1:1-22.*
- 8) Causen T. *Clinical and therapeutic significance of the Na⁺, K⁺ pump. Clin Sci 1998;95:3-17.*
- 9) Hauptman PJ, Kelly RA. *Digitalis. Circulation 1999;99:1265-70.*
- 10) Kelly RA, Smith TW. *Pharmacologic treatment of heart failure. In: Goodman and Gilman's Pharmacological Basis of Therapeutics. 8th ed.;1996. p.809-38.*
- 11) Chen CJ, Lin CS, Chang LW, Lin SH. *Perplexing hyperkalemia. Nephrol Dial Transplant 2006;21:3320-3.*
- 12) Dasgupta A, Lopez AE, Wells A, Olsen M, Actor J. *The Fab fragment of anti-digoxin antibody (digibind) binds digitoxin-like immunoreactive componets of Chines medicine Chan Su: monitoring the effect by measuring free digitoxin. Clin Chim Acta 2001; 309:91-5.*
- 13) Lipps BV, Khan AA. *Antigenic cross reactivity among the venoms and toxins from unrelated diverse sourses. Toxicon 2000;38:973-80.*