

Synovial Osteochondroid Metaplasia of the Elbow Joint Mimicking a Fracture – A Case Report –

Jae Ho Yoo, M.D., Bo Kyu Yang, M.D., Seong Wan Kim, M.D., and Min Hong Zoo, M.D.

Department of Orthopaedic Surgery, National Police Hospital, Seoul, Korea

골절로 오인되기 쉬운 주관절 활액막 골연골화생 – 증례 보고 –

유재호 · 양보규 · 김성완 · 주민홍

국립경찰병원 정형외과

We present here a case of synovial osteochondroid metaplasia of the elbow joint that was almost mistaken for a fracture. A 21-year-old military recruit complained of pain at the elbow after a minor direct injury. Since the imaging studies, including simple radiographs and CT scans, showed a small bony fragment, an operation was performed under the impression of fracture of the elbow joint. There was no evidence of acute injury such as bleeding or swelling, and excisional biopsy was done. The histopathological findings of osteochondroid metaplasia surrounded by fibrous tissue and synovium led to the pathologic diagnosis of synovial osteochondroid metaplasia. Clinicians should include this tumorous entity in differential diagnosis when a bony fragment is seen on the radiographs of an acutely injured subject.

Key Words: Elbow, Synovial osteochondroid metaplasia, Fracture

Synovial osteochondroid metaplasia is a tumorous condition in which synovial cells undergoes metaplasia and produce a bony and cartilaginous mass. Although synovial osteochondromatosis of the elbow joint has been frequently reported as multiple lesions^{1,3,4,6,8-10)}, synovial osteochondroid metaplasia presenting as a solitary mass lesion has not been frequently reported in the literature. While the multiple lesions in synovial osteochondromatosis help us to avoid the mis-diagnosis of a fracture, a solitary bony fragment in a patient with synovial osteochondroid metaplasia can cause

the incorrect diagnosis of an acute bony injury. We present here a case of synovial osteochondroid metaplasia of the elbow joint that mimicked a fracture in a military recruit who had undergone minor direct trauma to the joint. The lesion was initially mistaken for an acute fracture.

CASE REPORT

A twenty-one-year-old man presented with acute pain in his left elbow after minor direct trauma to the joint. He was a military recruit and was injured during a military drill. He complained

통신저자 : 유 재 호
서울시 송파구 가락본동 58
국립경찰병원 정형외과
TEL: 02-3400-1244 · FAX: 02-449-2120
E-mail: jadeboy@kornet.net

Address reprint requests to
Jae Ho Yoo, M.D.
Department of Orthopaedic Surgery, National Police Hospital,
58, Garakbon-dong, Songpa-gu, Seoul 138-161, Korea
Tel: +82-2-3400-1244, Fax: +82-2-449-2120
E-mail: jadeboy@kornet.net

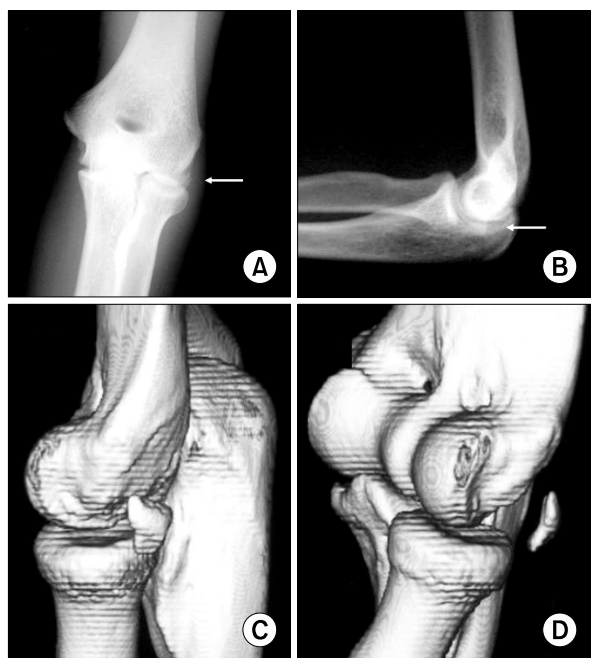

Fig. 1. (A, B) The preoperative anteroposterior and lateral simple radiographs show a radio-opaque density around the radio-capitellar joint (white arrow). (C, D) The reconstructed 3-dimensional computed tomographic images reveal a bony fragment on the posterolateral side of the elbow joint.

of tenderness at the lateral side of his elbow. On clinical examination there was no skin bruise or scratch around the elbow. Although any swelling of the joint was not detected, the range-of-motion was limited due to pain. There was no neurovascular deficit. The simple radiographs showed a radio-opaque density around the radio-capitellar joint, and computed tomography (CT) scans revealed a small bony fragment on the posterolateral side of the elbow joint (Fig. 1). The clinical diagnosis was fracture either of the capitellum or the radial head. To avoid entanglement due to the loose body and to confirm the diagnosis, an operation was performed on the 7th day after presentation. Repositioning of the fractured fragment and internal fixation, or excision of the fragment was planned. The posterolateral approach to the elbow between the anconeus and extensor carpi ulnaris was chosen. There was no soft tissue hematoma, swelling of the joint or any evidence of intra-articular bleeding. The fragment was a 1,5 by 1,3

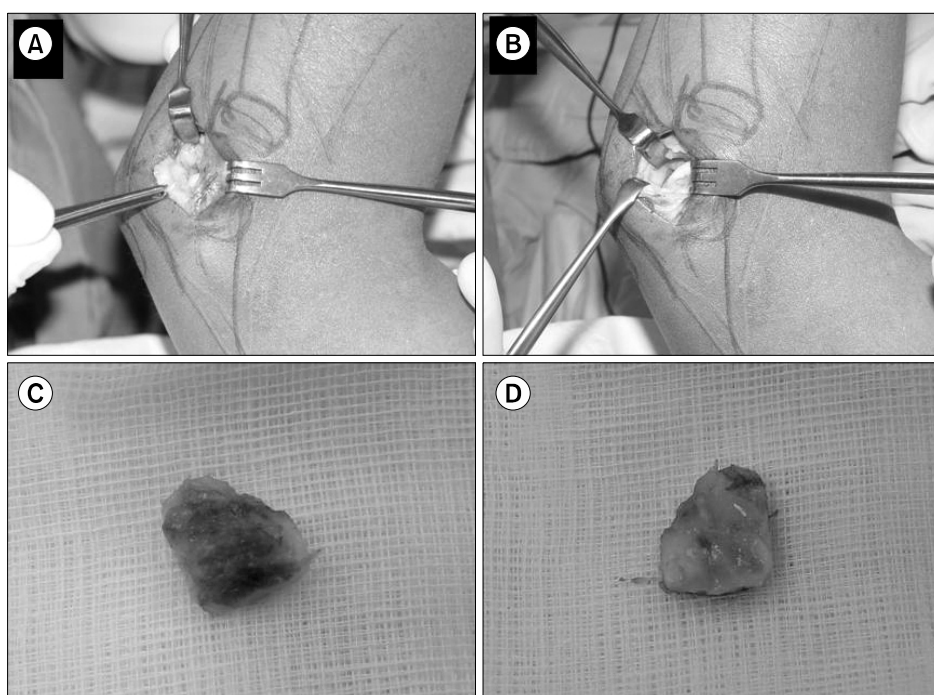


Fig. 2. The operative findings. There was no bruise or evidence of intra-articular bleeding. The mass was encapsulated by the synovium (A) and the surrounding bony structures were intact, including the radial head and capitellum (B). The external surface of the lesion was covered by the joint capsule (C) and the inner surface was covered by the synovial and cartilaginous tissues (D).

by 0.5 cm sized mass embedded in the synovium. The lack of evidence for an acute injury led us to simply excise the fragment en bloc (Fig. 2). Postoperatively, the bone scintigraphy performed 3 days later revealed no evidence of bony injury (Fig. 3). The findings of the histopathological slides were osteocartilagenous tissue buried in the fibromuscular tissue, which was compatible with osteo-

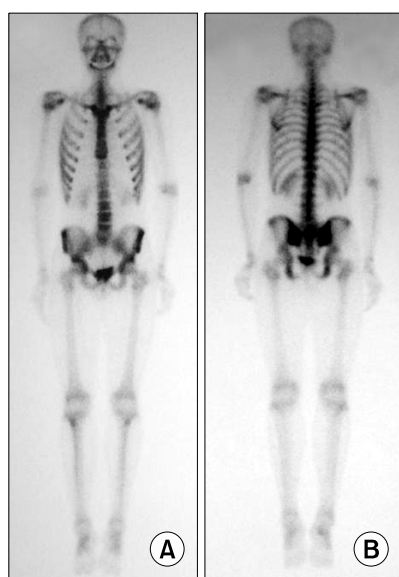


Fig. 3. The bone scintigraphy taken 3 days after excision of the lesion. The absence of a hot spot on the anterior (A) and posterior (B) view implies that there is no acute fracture.

chondroid metaplasia (Fig. 4). The final diagnosis of osteochondroid metaplasia of the elbow joint was made. At postoperative 1 year, he had no difficulty in the activities of daily living, and no evidence of recurrence could be documented.

DISCUSSION

Loose bodies of the elbow joint may originate from osteoarthritis, trauma and osteochondritis dissecans, or they may exist as idiopathic lesion^{1,3}. The common presentations are pain or mechanical symptoms such as catching or locking, none of which is specific^{6,7}. Incidentally detected single loose bodies of the elbow joint that are without pain or mechanical symptoms has received little attention by clinicians. If a bony fragment is seen on a radiograph of an acutely injured person, the clinician is liable to reach the diagnosis of a fracture as the first impression. Synovial osteochondroid metaplasia, which has similar radiologic features to a fracture fragment should be included in the differential diagnosis of an acutely injured joint.

The main phenomenal difference between synovial osteochondromatosis and synovial osteochondroid metaplasia is the multiplicity, although

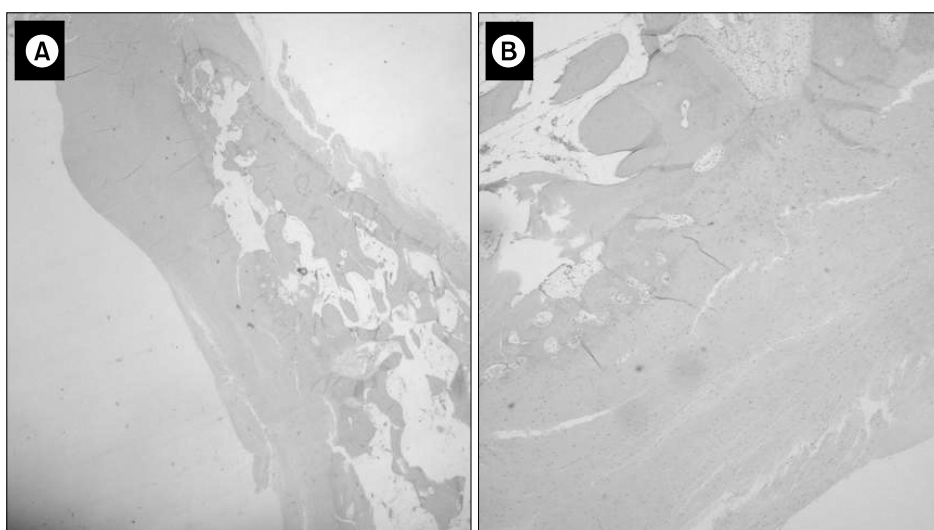


Fig. 4. (A, B) The histopathological findings. The osteochondroid tissue was surrounded by dense fibrous tissue without any evidence of acute hemorrhage (hematoxylin and eosin, $\times 40$ for Fig. 4A and $\times 100$ for Fig. 4B).

the histopathological findings are similar. The clinical manifestation may be related to the mass effect of the lesion. While synovial osteochondromatosis is rarely mistaken for a fracture, synovial osteochondroid metaplasia is liable to be misdiagnosed. The pain in synovial osteochondromatosis may accompany not only exertion, but it may be due to effusion, locking, nerve compression or secondary osteoarthritic changes^{1,7)}. The extra-articular manifestations may be bursitis around the elbow joint⁷⁾ or peripheral nerve compression, including ulnar nerve entrapment neuropathy^{2,10)} and entrapment of both the median nerve at the wrist and the posterior interosseous nerve at the elbow⁵⁾. Operative excision with debridement and synovectomy has often been performed to treat the mechanical symptoms^{6,8,10)}. Synovial osteochondromatosis is rarely associated with malignant transformation and distant metastasis⁹⁾, recurrence^{6,8)} or osteoarthritic change^{6,8)}.

The pain of a current case might originate from the contused soft tissue or exacerbation of the vague pain associated with a tumor. However, even though we included the correct diagnosis in preoperative differential diagnosis, the management plan might not have been different. The operative excision of the lesion might be justified in that the surgical wound was small and the functional impairment associated with the operation itself was minimal. It is, however, important to consider all the possible morbid conditions preoperatively, and to include synovial osteochondroid metaplasia in the differential diagnosis. Omitting this disease from the differential diagnosis might bring about medicolegal conflict in certain situations such as military recruits, industrial workers, etc.

The dearth of definitive preoperative diagnostic methods for synovial osteochondroid metaplasia accentuates the importance of having a clinical suspicion for this disease. None of the diagnostic

test, including simple radiography, CT scans or bone scintigraphy, can provide a definite positive result for the synovial osteochondroid metaplasia or synovial osteochondromatosis. The morphological features on radiographs or CT scans sometimes fall between acute injury and a tumorous condition. Although preoperative bone scintigraphy may be helpful to discriminate acute bony lesion, it cannot exactly discern a tumorous lesion from a fracture. Milgram described 3 histopathological phases in the growth of synovial osteochondromatosis, and they consist of intrasynovial involvement, intrasynovial involvement and free bodies (transitional), and multiple free bodies due to synovial osteochondromatosis⁹⁾; the activity of the lesion is variable according to the phases. The discrimination between acute bony injury and osteochondrogenic tumor might not be clear on hot uptakes, while a tumorous entity cannot be excluded by an absence of hot uptake. Hence, the final diagnosis should be made histopathologically, and a diagnostic suspicion by the physician for this malady is mandatory.

REFERENCES

1. **Bell MS:** *Loose bodies in the elbow.* Br J Surg, 62: 921-924, 1975.
2. **Fahmy NR, Noble J:** *Ulnar nerve palsy as a complication of synovial osteochondromatosis of the elbow.* Hand, 13: 308-310, 1981.
3. **Henderson MS:** *Loose bodies in the elbow joint.* J Am Med Assoc, xxi: 177-180, 1918.
4. **Jeffreys TE:** *Synovial chondromatosis.* J Bone Joint Surg Br, 49: 530-534, 1967.
5. **Jones JR, Evans DM, Kaushik A:** *Synovial chondromatosis presenting with peripheral nerve compression—a report of two cases.* J Hand Surg Br, 12: 25-27, 1987.
6. **Kamineni S, O'Driscoll SW, Morrey BF:** *Synovial osteochondromatosis of the elbow.* J Bone Joint Surg Br, 84: 961-966, 2002.

7. **Matsumoto K, Hukuda S, Fujita M, Kakimoto A, Tachibana S:** Cubital bursitis caused by localized synovial chondromatosis of the elbow. A case report. *J Bone Joint Surg Am*, 78: 275-277, 1996.
8. **Maurice H, Crone M, Watt I:** Synovial chondromatosis. *J Bone Joint Surg Br*, 70: 807-811, 1988.
9. **Milgram JW:** Synovial osteochondromatosis: a histopathological study of thirty cases. *J Bone Joint Surg Am*, 59: 792-801, 1977.
10. **Ruth RM, Groves RJ:** Synovial Osteochondromatosis of the elbow presenting with ulnar nerve neuropathy. *Am J Orthop*, 25: 843-844, 1996.

= 국문초록 =

저자들은 골절로 오인되기 쉬운 주관절 활액막 골연골 화생의 증례를 보고하고자 한다. 군복무 중인 21세 남자가 경미한 직접 가격 후 주관절의 통증을 호소하였다. 단순 방사선 사진 및 전산화 단층 촬영 상 작은 골편이 보여, 주관절의 골절을 의심하고 수술을 시행하였다. 급성 손상에 합당한 출혈이나 부종 등의 소견은 없었으며, 절제 생검을 시행하였다. 골편은 섬유 조직 및 활액막에 피복되어 있었으며, 병리 조직 검사 상 최종 진단은 활액막 골연골 화생이었다. 임상적으로 주관절 급성 손상 환자의 영상 검사 상 보이는 골편의 감별 진단에 활액막 골연골화생을 포함시켜야 할 것으로 사료된다.

색인 단어: 주관절, 활액막 골연골 화생, 골절