

Case Report

Anomalous Insertion of the Medial Meniscus into the Anterior Cruciate Ligament: A Case Report

Ki Hwan Kim, Jae Chan Shim, Kyoung Eun Lee, Ho Kyun Kim, Ghi Jai Lee, Jung Ho Suh

Department of Radiology, Seoul Paik Hospital, Inje University College of Medicine, Seoul, Korea

Anomalies of the medial meniscus are rare and difficult to diagnose clinically. Among these anomalies, anomalous insertion of the medial meniscus into the anterior cruciate ligament is rare. Most of the reported cases had no relation to clinical symptoms and were found incidentally during arthroscopy. We report a rare case of anomalous insertion of the medial meniscus into the anterior cruciate ligament with a brief review of the literature.

Index words : Anomalous insertion · Medial mesniscus · Magnetic resonance imaging (MRI)

INTRODUCTION

Several types of the anomalies have been reported in the literature, although anomalies of the medial meniscus are rare (1-4). They include discoid variants, complete absence of the medical meniscus, hypoplasia of the anterior horn, and anomalous insertion of the medial meniscus (AIMM) into the anterior cruciate ligament (ACL). In AIMM into the ACL, the medial meniscus runs from the anterior horn of the medial meniscus to either the ACL or the intercondylar notch. Familiarity with the characteristic MR findings of this anomaly can contribute to its early detection and prearthroscopic diagnosis. We recently experienced one case of this anomaly, and MR examination showed characteristic features to establish definitive diagnosis of AIMM into the ACL.

CASE REPORT

A 40-year-old man was admitted to our hospital with pain on the anteromedial side of the right knee for 15 days. The patient had no history of trauma, and physical examination revealed tenderness on the anteromedial joint line. The results of McMurray's and Apley's tests were positive on the medial side of the right knee. He complained of anterior knee pain on the hyperextension test, although he had a full range of motion. However, there was neither edema of the knee, hypotrophy of the quadriceps muscle, nor instability of the knee. Plain radiographs showed no specific abnormalities. Coronal MPD images showed a bandlike low-signal intensity with inserting into the ACL at the intercondylar notch level (Fig. 1a). Sagittal modified proton density (MPD) showed a bandlike low-signal intensity which started from the anterior horn of the medial meniscus and ran anteriorly parallel to the anteromedial bundle of the ACL (Fig. 1b). Based on MR findings, the patient was diagnosed with AIMM into the ACL. No therapeutic or diagnostic procedures, including arthroscopy, were conducted. After conservative therapy for 3 months, his pain at the right knee joint was almost relieved, and at further follow-ups, the pain completely disappeared.

• Received; July 17, 2013 • Revised; August 20, 2013

• Accepted; August 28, 2013

Corresponding author : Jae Chan Shim, M.D.

Department of Radiology, Seoul Paik Hospital, Inje University College of Medicine, 85, Jeon-dong 2-ga, Jung-gu, Seoul 100-032, Korea.

Tel. 82-2-2270-0133, Fax. 82-2-2266-6799

E-mail : jcsim96@unitel.co.kr

DISCUSSION

Anomalies of the medial meniscus are rare. The anterior horn of the medial meniscus is the most frequent site of variation (4). Among these rare anomalies, AIMM into ACL is even more infrequent variation. In the study of Cha et al. (6) the frequency of AIMMs was 2.26% (30 MR images obtained from 1326 consecutive knee arthroscopic studies). In the normal knee, the anterior horn of the medial meniscus is attached to the tibial plateau in the area of the

anterior intercondylar fossa in front of the ACL; it remains distinct from the anterior cruciate ligament. The characteristic features of AIMM into the ACL include a low-signal band that extends from the anterior horn of the medial meniscus, running parallel to the ACL up to the insertion site of the ACL or the intercondylar notch (5). Throughout the course, AIMM shows an isointense-signal intensity to the meniscus and the ACL, with a high-signal intensity gap between the ACL and the AIMM. In such anomalies, the medial meniscus has insertion into various sites: the lower part (inferior third) of the ACL, the middle part

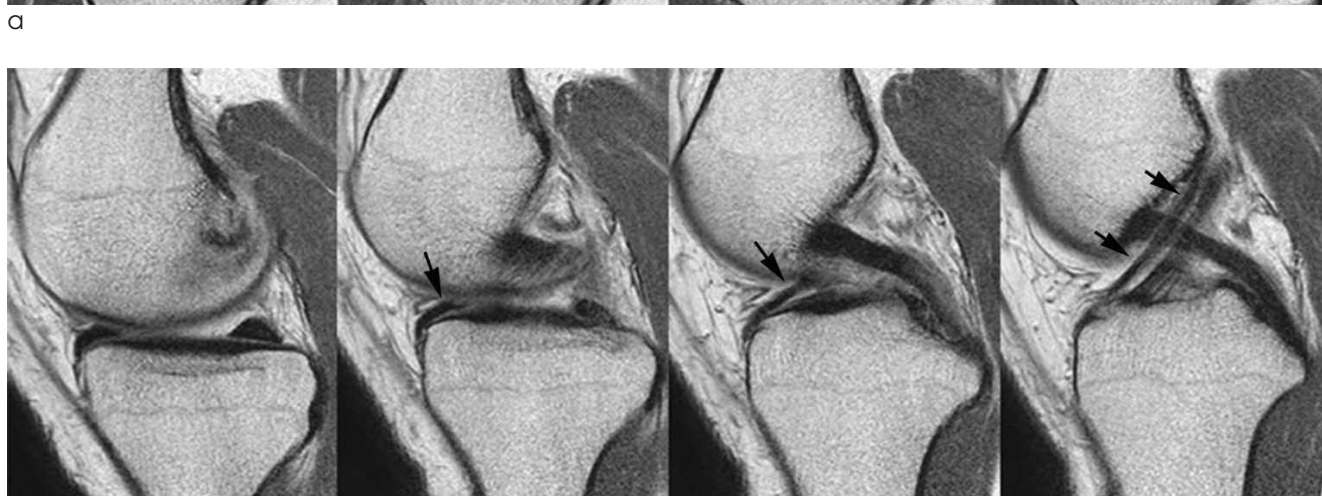
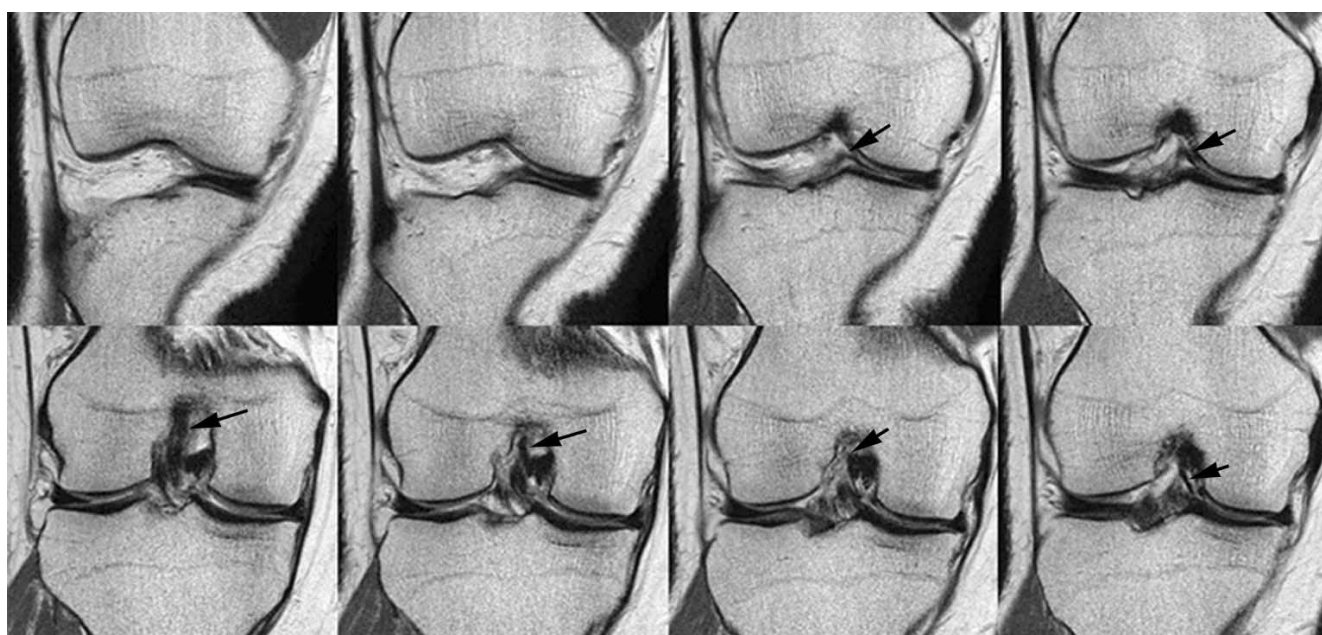


Fig. 1. MR images of a 40-year-old man with anomalous insertion of the medial meniscus into the anterior cruciate ligament. A linear dark signal band arises from anterior horn of medial meniscus and runs parallel to the anterior cruciate ligament on sequential modified proton density (MPD) coronal (**a**) (clockwise direction) and sagittal (**b**) images of the right knee joint.

(middle third) of the ACL, and the superior part (superior third; intercondylar notch) on sagittal MR images, with the lower insertion type being more common (6).

A tear of the anterior horn of the medial meniscus or ACL and infrapatellar plicae should be considered in the differential diagnosis of AIMM. A tear in the anterior horn of the medial meniscus mimics AIMM, but AIMM can be definitively diagnosed by tracing the medial margin of the anterior horn of the medial meniscus on serial T2-weighted sagittal images. In addition, tears confined to the anterior third of the medial meniscus, particularly in its lateral part, are extremely rare, and therefore differentiation between AIMM and the tears is nearly unnecessary in clinical practice (6). Arjun et al. (5) indicated that AIMM could be mistaken for partial rupture of the ACL. However, this anomaly can be detected by tracing from the anterior horn of the medial meniscus to the ACL on thin serial sections of T2-weighted images. An infrapatellar plica is similar to AIMM, with a curvilinear appearance anterior to the ACL on sagittal T2-weighted images (7). However, the origin of the infrapatellar plica does not attach to the anterior horn of the medial meniscus but to Hoffa's fat pad or the inferior pole of the patella, which can be confirmed on MR images and arthroscopic examination. AIMM may complicate the arthroscopic evaluation of the ACL as is the case with infrapatellar plicae (7).

Cha et al. (6) hypothesized that AIMM is a variation of infrapatellar plicae because all cases showed infrapatellar plicae as thin membranes on arthroscopic examination. In addition, AIMM and infrapatellar plica have a chronological similarity in developmental stages according to recent embryological studies (8, 9).

Our case shows the typical MR findings of AIMM into the ACL. On serial sagittal and coronal images, tears of the anterior horn of the medial meniscus and ACL were excluded. Since the ACL started from the anterior aspect of the medial meniscus, our case was

easily differentiated from infrapatellar plica. Generally, AIMM into the ACL does not seem to correlate with knee symptoms. Santi and Richardson (1) reported the case of a patient with bilateral anomalous insertion of the medial meniscus and the habitus of Marfan's syndrome. This patient had no other cause of the anterior medial knee pain, which disappeared after excision of the anomalous meniscal portion. In our case, after conservative treatment and regular follow-ups, the patient's pain in the knee joint was completely relieved, suggesting that the pain may not correlate with AIMM.

In conclusion, AIMM can be misdiagnosed as ACL tear, meniscal tear, or infrapatellar plica and may complicate arthroscopic findings. Familiarity with characteristic MR findings can aid in the early detection of AIMM.

References

1. Santi MD, Richardson AB. Bilaterally painful anomalous insertion of the medial meniscus in a volleyball player with marfanoid features. *Arthroscopy* 1993;9:217-219
2. Diskason JM, Pizzo WD, Blazina MF. A series of ten discoid medial menisci. *Clin Orthop Relat Res* 1982;(168):75-79
3. Riachi E, Phares A. An unusual deformity of the medial semilunar cartilage. *J Bone Joint Surg Br* 1963;45:146-147
4. Johnson LL. Arthroscopic anatomy. In Klein EA, Falk KH, eds. *Arthroscopic surgery. Principles and practice*. 3rd ed. St Louis: Mosby, 1986;493-494
5. Arjun S, Takahashi S, Tang Y, Nakane N, Yonemitsu H. MR appearance of anomalous insertion of the medial meniscus. A case report. *Acta Radiol* 1998;39:554-556
6. Cha JG, Min KD, Han JK, et al. Anomalous insertion of the medial meniscus into the anterior cruciate ligament: the MR appearance. *Br J Radiol* 2008;81:20-24
7. Kosarek FJ, Helms CA. The MR appearance of the infrapatellar plica. *AJR Am J Roentgenol* 1999;172:481-484
8. Mérida-Velasco JA, Sánchez-Montesinos I, Espín-Ferra J, et al. Development of the human knee joint ligaments. *Anat Rec* 1997;248:269-278
9. Ogata S, Uhthoff HK. The development of synovial plicae in human knee joints: an embryologic study. *Arthroscopy* 1990;6: 315-321

전방십자인대에 이상 부착을 보이는 내측 반월상 연골에 관한 증례보고

인제대학교 의과대학 서울백병원 영상의학과

김기환 · 심재찬 · 이경은 · 김호균 · 이기재 · 서정호

내측 반월상 연골에 생기는 기형은 매우 드물고 임상적으로 진단하기 어렵다. 이러한 기형 중에서도 전방십자인대에 이상 부착을 보이는 내측 반월상 연골은 드물다. 대부분의 보고된 증례들은 임상적인 증상과 연관을 보이지 않으며 관절경검사를 하면서 우연히 발견된다. 우리는 드문 증례인 전방십자인대에 이상 부착을 보이는 내측 반월상 연골에 대한 자기공명 영상을 보고하고 문헌을 통한 간략한 검토를 하려고 한다.

통신저자 : 심재찬, (100-032) 서울시 중구 저동2가 85, 인제대학교 의과대학 서울백병원 영상의학과
Tel. (02) 2270-0133 Fax. (02) 2266-6799 E-mail: jcshim96@unitel.co.kr