



(catecholamine)

1

(pheochromocytomas)
(pheochromocytes)
0.1% - 0.3%

90%

10%

(Fig. 2).

가

가

(paragangliomas)

(1).

CA - 125
가

15 × 9 × 8 cm

59

가

4

(Fig. 3).

(Fig. 4).

13 × 10

× 9 cm

가

가

(chromaffin)

(Fig. 1).

가

가

가

40

60

10%

10%
10%

, 10%

, 10%

(1).

가

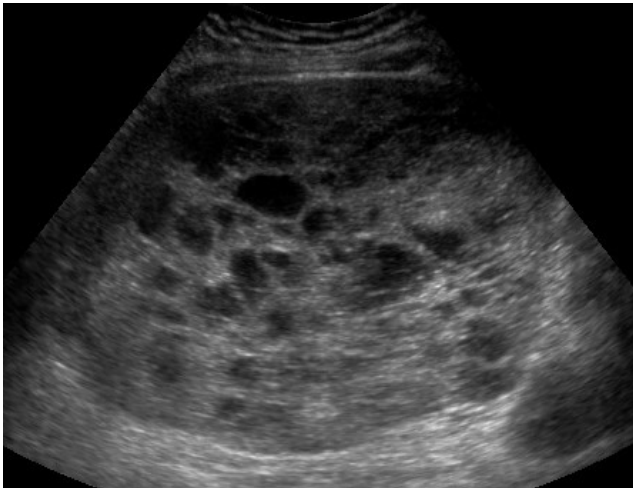
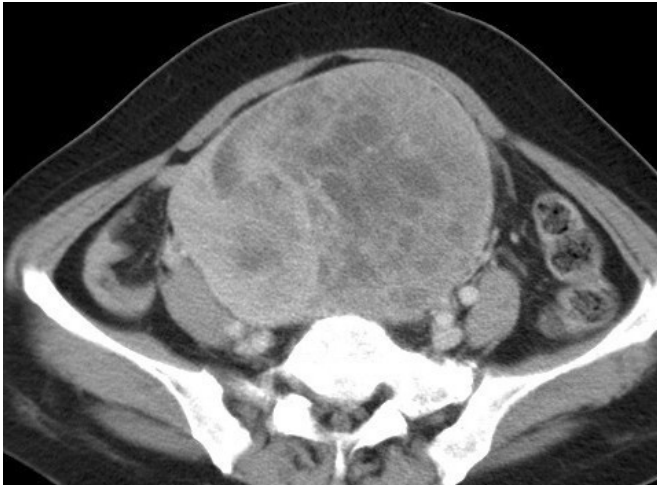
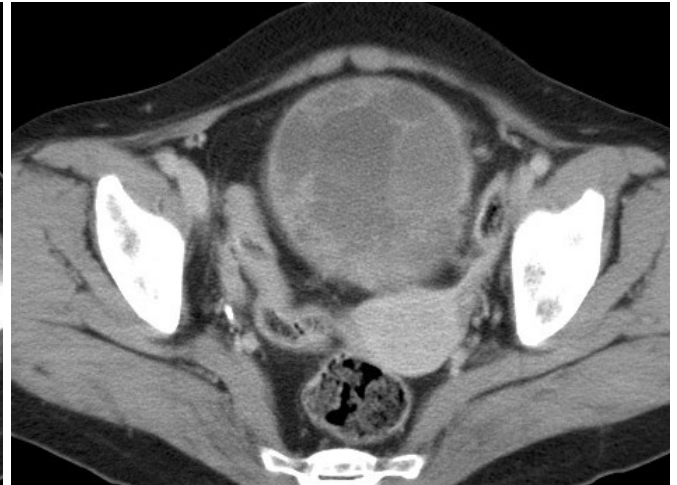
Fig. 1. Transverse US image obtained at the midline level in the pelvic cavity shows a well-defined, heterogeneous solid mass containing internal low echoic portions in the mass.

:
 , , , .
 (2).
 90%가
 (3). 가
 , , , . 90% 가
 (4).
 (3).
 (Valsalva maneuver) 가
 .
 , (metanephrine)
 (vanillylmandelic acid)
 24
 .
 25%
 60% ,



A



B

Fig. 2. Contrast-enhanced CT scan demonstrates heterogeneously enhancing mass with internal low attenuated portions at the level of iliac vessels (**A**) and the body of uterus (**B**).

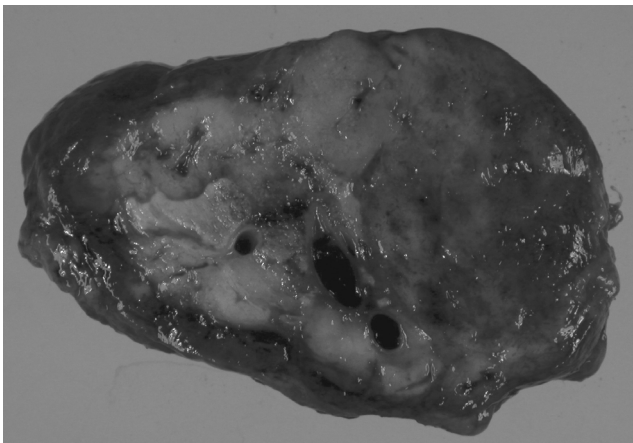


Fig. 3. Photograph of the gross specimen shows a 15 × 9 × 8 cm mass with some areas of focal hemorrhage and tumor necrosis.

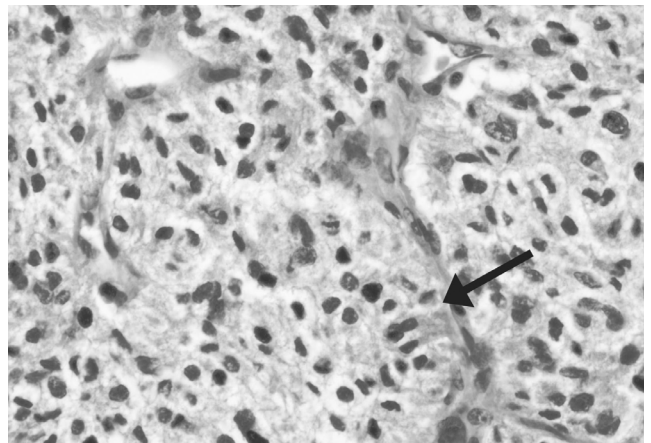


Fig. 4. Photomicrograph (×40; H - E stain) of the paraganglioma shows a small nesting pattern of growth with typical Zellballen (arrow) appearance.

- (5).
- (6).
- (sinusoidal vessel)
- . Yang (7)
- (8).
1. Scopsi L, Collini P, Muscolino G. A new observation of the Carney 's triad, with long follow-up period and additional tumors. *Cancer Detect Prev* 1999;23:435-443
 2. Francis IR, Korobkin M. Pheochromocytoma. *Radiol Clin North Am* 1996;34:1101-1112
 3. Young JB, Landsberg L. *Catecholamines and the adrenal medulla*. In Williams RH, Wilson JD, *Williams textbook of endocrinology*. 9th ed. Philadelphia: Saunders, 1998:705-716
 4. O 'Connor DT. *The adrenal medulla, catecholamines, and pheochromocytoma*. In Goldman L, Bennett JC. *Cecil textbook of medicine*. 21st ed. Philadelphia: Saunders, 2000:1259-1262.
 5. 1994;30: 717-722.
 6. Lee TH, Slywotzky CM, Lavelle MT, Garcia RA. Cystic pheochromocytoma. *Radiographics* 2002;22:935-940
 7. Yang DM, Jung DH, Kim H, Kang JH, Kim SH, Kim JH. et al. Retroperitoneal cystic masses: CT, clinical, and pathologic findings and literature review. *Radiographics* 2004;24:1353-1365
 8. Kuscu E, Oktem M, Eroglu D, Haberal A, Bilezikci B, Demirhan B. Pelvic retroperitoneal paraganglioma mimicking an ovarian mass. *Eur J Gynaecol Oncol* 2005;26:219-20

Non-Functional Retroperitoneal Paraganglioma Mimicking an Ovary Mass: A Case Report¹

Seung Rim Kang, M.D., Kyungran Ko, M.D., Hong Dae Kim, M.D.,
Sang Hee Choi, M.D., Ji Young Woo, M.D.

¹Department of Radiology, Hallym University College of Medicine

The paraganglioma is rare neuroendocrine tumor arising from paraganglionic tissue and most cases show characteristic endocrinological symptoms that are caused by catecholamine secretion. We report here on a case of nonfunctioning retroperitoneal paraganglioma that did not show any neuroendocrine symptoms, and this was misdiagnosed as ovarian tumor by ultrasonography and CT.

Index words : Retroperitoneal space
Ultrasound (US)
Computed tomography (CT)
Neoplasms
Pheochromocytoma
Paraganglioma

Address reprint requests to : Ji Young Woo, M.D., Department of Radiology, Hallym University, Kangnam Sacred Heart Hospital,
948-1, Daerim 1-dong, Yungdungpo-gu, Seoul 150-950, Korea.
Tel. 82-2-829-5241 Fax. 82-2-832-1845 E-mail: bassas@empal.com