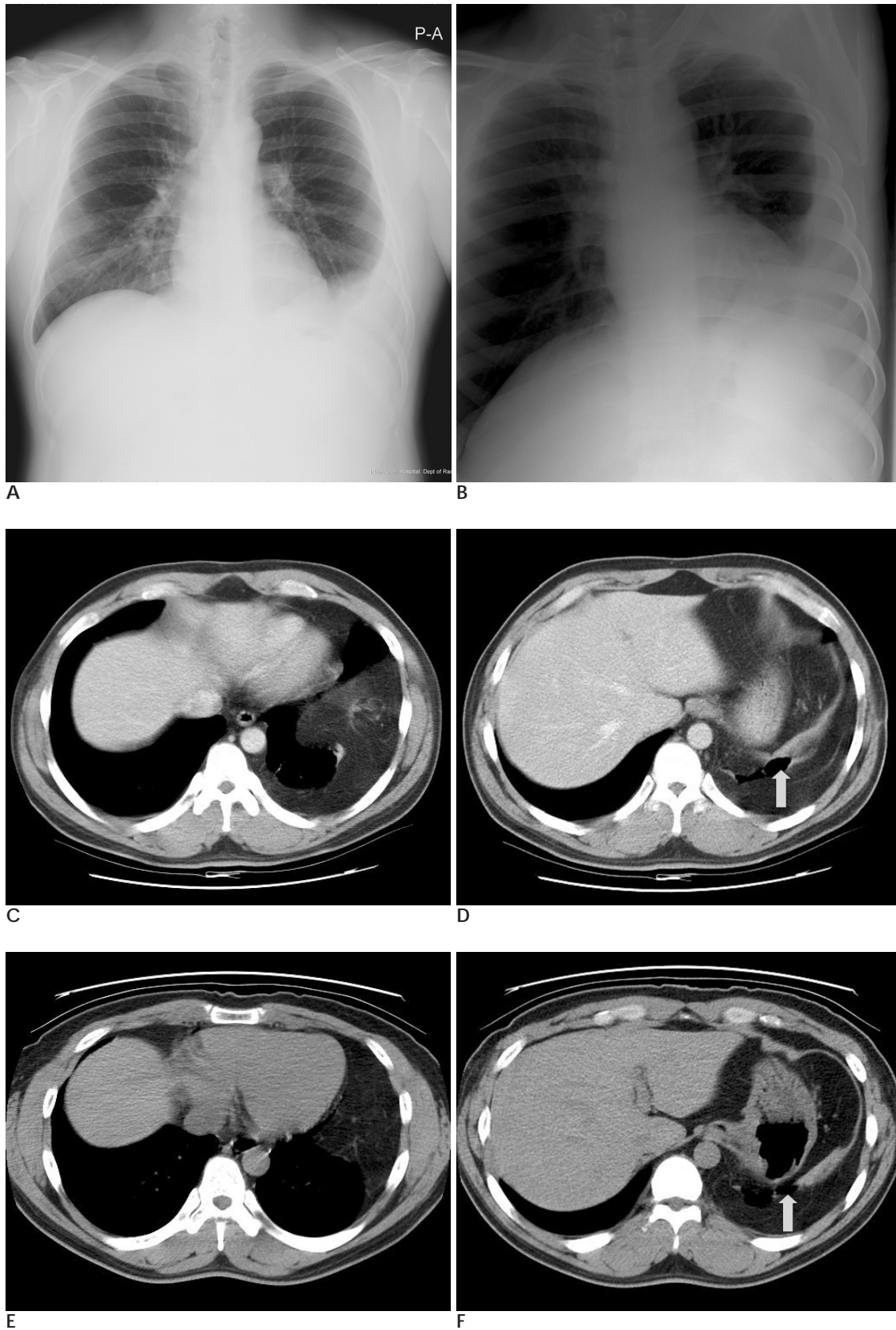
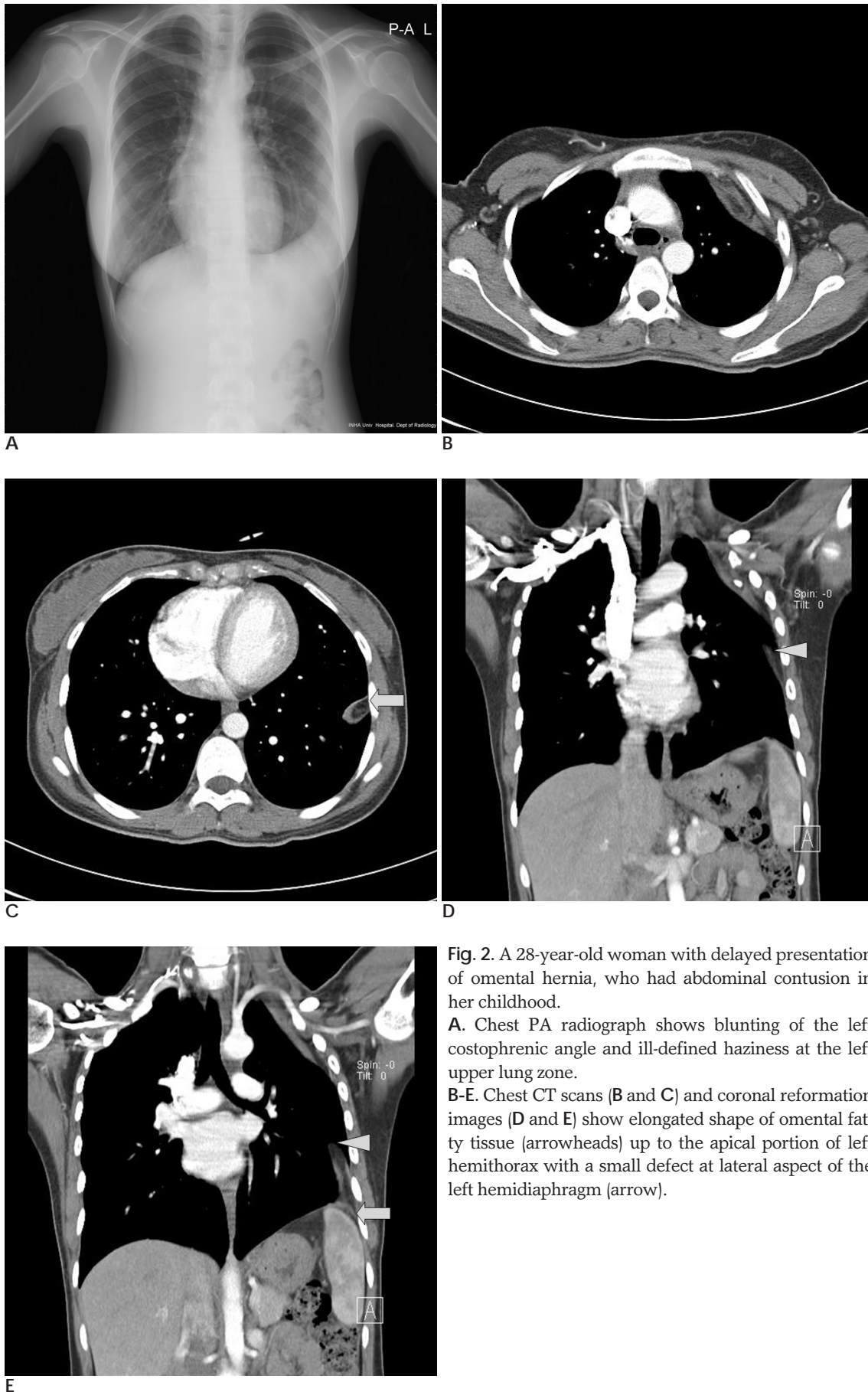


가 10  
,  
.  
2  
(1).  
(Complete H - mole)  
28  
,  
(2).  
(Computed  
tomography, CT)  
,  
(Fig. 2A).  
가 2 cm  
CT  
,  
(Fig. 2B -  
E).  
1  
12  
가 3  
가  
36  
,  
,  
,  
가  
,  
(Fig. 1A, B).  
CT  
(Fig. 1C, F).  
,  
,  
0.8 - 5.0%  
(1, 2).  
가 (2). Shackelton, (1)  
5  
60%,  
40%  
(1).



**Fig. 1.** A 36-year-old-man with delayed presentation of traumatic diaphragmatic hernia, who had left abdominal contusion 12 years ago. **A, B.** Chest PA radiograph shows blunting of the left costophrenic angle. Left lateral decubitus view shows fluid shifting. **C-F.** Chest CT scans on supine position (**C** and **D**) and on prone position (**E** and **F**) show herniated omentum in left thorax and a defect in the postero-superior portion of left hemidiaphragm (arrows).



**Fig. 2.** A 28-year-old woman with delayed presentation of omental hernia, who had abdominal contusion in her childhood.  
**A.** Chest PA radiograph shows blunting of the left costophrenic angle and ill-defined haziness at the left upper lung zone.  
**B-E.** Chest CT scans (**B** and **C**) and coronal reformation images (**D** and **E**) show elongated shape of omental fatty tissue (arrowheads) up to the apical portion of left hemithorax with a small defect at lateral aspect of the left hemidiaphragm (arrow).

가

(2).

가

가

(Video - assisted thoracoscopic surgery)

(6).

(2). Lin, (3)

2 40

가

CT

7.3 (3), Aronchick, (2)

43%

(2).

1 가

, CT

(4).

, CT

가 (Morgagni foramen)

가 (5),

10

가,

, CT

가

, CT,

(4).

1. Shackleton KL, Stewart ET, Taylor AJ. Traumatic diaphragmatic injuries: spectrum of radiographic findings. *Radiographics* 1998;18: 49-59
2. Aronchick JM, Epstein DM, Geftter WB, Miller WT. Chronic traumatic diaphragmatic hernia: the significance of pleural effusion. *Radiology* 1988;168:675-678
3. Lin YK, Huang BS, Shih CS, Hsu WH, Huaug MH, Lee CH. Traumatic diaphragmatic hernia with delayed presentation. *Zhonghua Yi Xue Za Zhi* 1999;64:223-229
4. Roth DZ, Siwak C, Burrowes PW, MacGregor JH. Trauma-induced omental herniation simulating pleural effusion: case report. *Can Assoc Radiol J* 2004;55:157-159
5. 1985;21:945-953
6. Freeman RK, Al-Dossari G, Hutcheson KA, Huber L, Jessen ME, Meyer DM, et al. Indications for using video-assisted thoracoscopic surgery to diagnose diaphragmatic injuries after penetrating chest trauma. *Ann Thorac Surg* 2001;72:342-347

## **Traumatic Diaphragmatic Hernia with a Delayed Presentation: A Report on Two Cases of Omental Herniation that Simulated Pleural Effusion<sup>1</sup>**

Bong Wan Noh, M.D., Yong Sun Jeon, M.D., Yong Han Yoon, M.D.<sup>2</sup>,  
Soon Goo Cho, M.D., Kyung Hee Lee, M.D.

<sup>1</sup>*Department of Radiology, Inha University Hospital*

<sup>2</sup>*Department of Cardiovascular & Thoracic Surgery, Inha University Hospital*

Traumatic diaphragmatic hernia may show a delayed presentation and it rarely simulates pleural effusion. We report here on two asymptomatic cases that were diagnosed by performing chest CT.

**Index words :** Hernia, diaphragmatic  
Omentum  
Pericardium, fluid

Address reprint requests to : Kyung Hee Lee, M.D., Department of Radiology, Inha University College of Medicine,  
7-206 3rd St, Shinheung-dong, Choong-gu, Incheon 400-711, Korea  
Tel. 82-32-890-2565 Fax. 82-32-890-2743 E-mail: radjeon@inha.ac.kr