

(Retropharyngeal Bronchogenic Cyst):¹

.²

(bronchogenic cyst) (primitive ventral foregut) (1). (Fig. 3). (mediastinum) . (retropharyngeal) , 가 , (foregut 가 duplication cyst) 60% , (pseudostratified ciliated columnar epithelium) , (serous), (hemorrhagic), (viscous) (2). (carina) (50%), (20%), (15%), (10%) (tracheobron - chial tree) (2). 2.4 × 1.0 5 cm (Fig. 1). , T1 (Fig. 2). , T2 (3), (4), (5) (supraclavicular) (6), (carotid sheath) (tracheoesophageal groove) (7), (suprasternal notch) (8), (9), (10)

X

¹가
²가

가
T2-
T1-
(2).
가 (branchial cleft

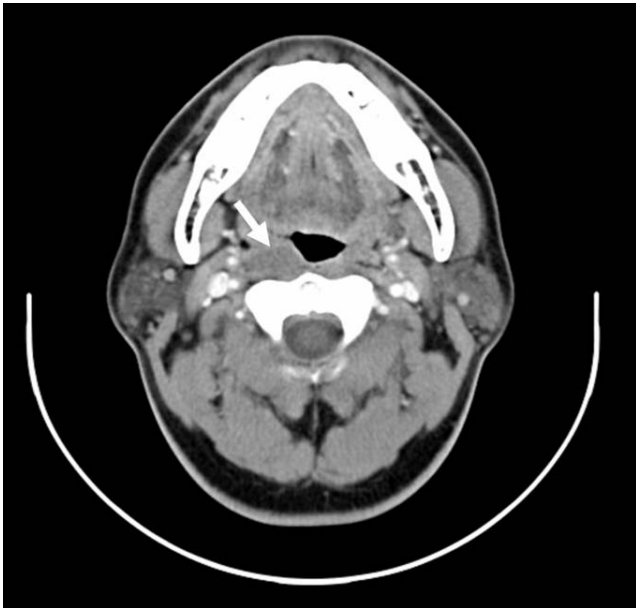


Fig. 1. A 45-year-old man with right retropharyngeal bronchogenic cyst. Axial CT scan demonstrates an ovoid hypodense mass (arrow) in the right retropharyngeal space.

cyst), 가 (thymic cyst), (cystic degeneration), (papillary thyroid carcinoma), (thyroglossal duct cyst), (teratoma), (neurogenic tumor), (cystic hygroma), (tracheal diverticulum)

(neuroblastoma), (ectopic thyroid)
(10).
가

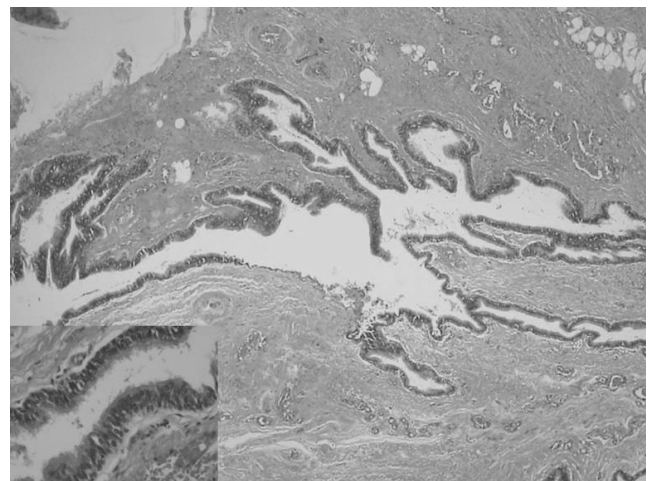


Fig. 3. Bronchogenic cyst is lined by ciliated pseudostratified columnar epithelium. (H & E $\times 40$) ; inlet (H & E $\times 400$)

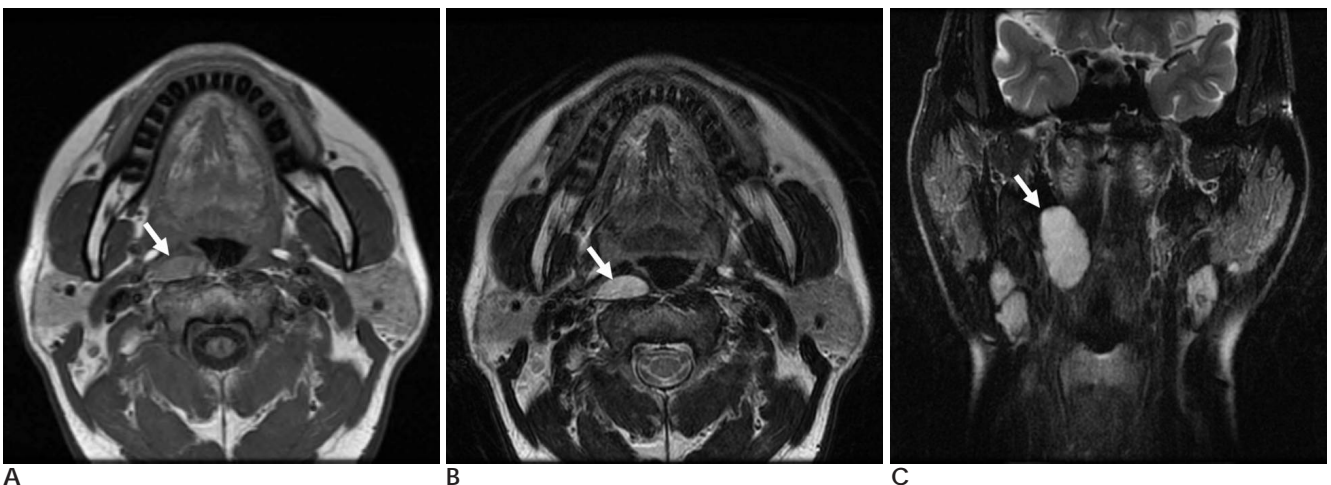


Fig. 2. A 45-year-old man with right retropharyngeal bronchogenic cyst.
A. T1-weighted axial MR image shows a well-defined oval cystic mass (arrow) with intermediate signal intensity in the right retropharyngeal space.
B. On T2-weighted axial MR image, the mass shows bright signal intensity (arrow).
C. On T2-weighted coronal MR image, the elongated shape of the mass (arrow) in superior-inferior direction is well demonstrated in retropharyngeal space.

1. Berrocal T, Madrid C, Novo S, Gutierrez J, Arjonilla A, Gomez-Leon N. Congenital anomalies of the tracheobronchial tree, lung, and mediastinum: embryology, radiology and pathology. *Radiographics* 2004;24: e17
2. Webb WR, Higgins CB. *Thoracic Imaging: Pulmonary and Cardiovascular Radiology*. Philadelphia: Lippincott Williams & Wilkins. 2005:253-255
3. Kim YC, Goo JM, Han JK, Lee KH, Lee HS, Im JG. Subphrenic bronchogenic cyst mimicking a juxtahepatic solid lesion. *Abdom Imaging* 2003;28:354-356
4. , , . : 2007;57:451-453
5. Kim NR, Kim HH, Suh YL. Cutaneous bronchogenic cyst of the abdominal wall. *Pathol Int* 2001;51:970-973
6. Rapado F, Bennett JD, Stringfellow JM. Bronchogenic cyst: an unusual cause of lump in the neck. *J Laryngol Otol* 1998;112:893-894
7. McManus K, Holt GR, Aufdemorte TM, Trinkle JK. Bronchogenic cyst presenting as deep neck abscess. *Otolaryngol Head Neck Surg* 1984;92:109-114
8. Hadjihannas E, Ray J, Rhys-Williams S. A cervical bronchogenic cyst in an adult. *Eur Arch Otorhinolaryngol* 2003;260:216-218
9. Shimizu J, Kawaura Y, Tatsuzawa Y, Maeda K, Suzuki S. Cervical bronchogenic cyst that presented as a thyroid cyst. *Eur J Surg* 2000;166:659-661
10. Jacob JK, George S, Roy BR, Preethi S, Ranjith VT, Pappachan JM. Retropharyngeal bronchogenic cyst. *Otolaryngol Head Neck Surg* 2007;136:1025-1026

J Korean Radiol Soc 2008;59:83 - 85

Retropharyngeal Bronchogenic Cyst¹

Ye-il Kim, M.D., Kook-jin Ahn, M.D., Jee-young Kim, M.D., Seong-tae Hahn, M.D., Youn Soo Lee, M.D.²

¹Department of Radiology, The Catholic University of Korea

²Department of Pathology, The Catholic University of Korea

Few reports exists citing a case of a retropharyngeal bronchogenic cysts. In this study, we report a bronchogenic cyst with a cystic appearance observed in the retropharyngeal space.

Index words : Bronchogenic cyst
Pharyngeal diseases
Cysts
Tomography, X-Ray Computed

Address reprint requests to : Kook-jin Ahn, M.D., Department of Radiology, The Catholic University of Korea
505, Banpo-dong, Seocho-gu, Seoul 137-701, Korea.
Tel. 82-2-2142-7492 Fax. 82-2-599-6771 E-mail: ahn-kj@catholic.ac.kr