



Histoacryl

1

2

(1 - 5).

(Fig. 1A).

(Computed

Johnson (5)

tomography: CT)

가

10 cm

가

(Fig. 1B).

71

170/100 mmHg,
8.0 g/dL

90

가

Histoacryl

1

(Common Femoral Vein)
(Cook, Bloomington, U.S.A.)

5 - F

(Fig. 1C).

71

가

(PermCath Quinton, Mansfield, U.S.A.)

1

2

2007 10 4

2007 11 5

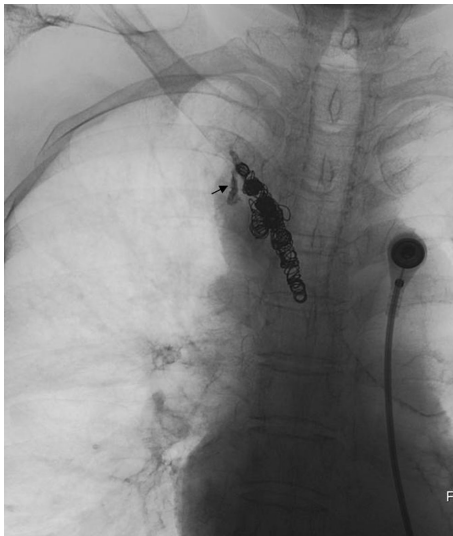
(Fig. 1D).
 2.7 - F (Progreat Terumo, Tokyo, Japan)
 10 mm 8 mm
 (Tornado, Cook, Bloomington, U.S.A.) 10
 0.5 ml N - butyl
 cyanoacrylate (Histoacryl, Braun, Melsungen, Germany) 2

가
 G). 2
 가 CT
 1H).

(Fig. 1E -
 9.5 g/dL
 (Fig.

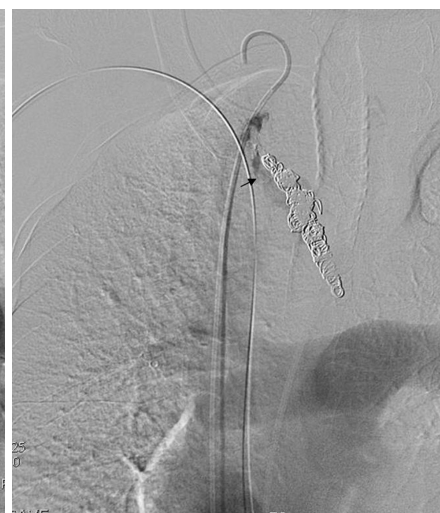
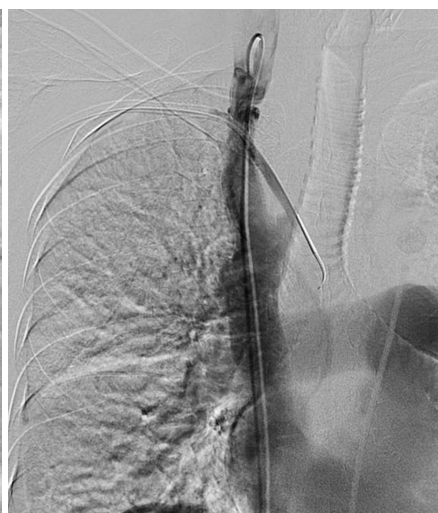
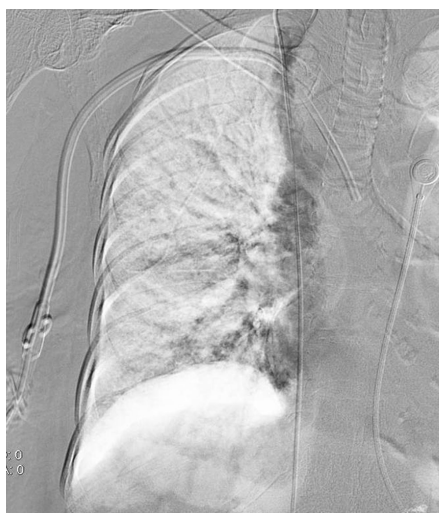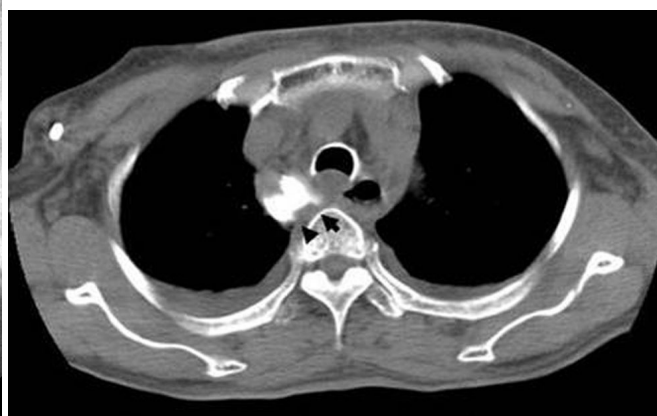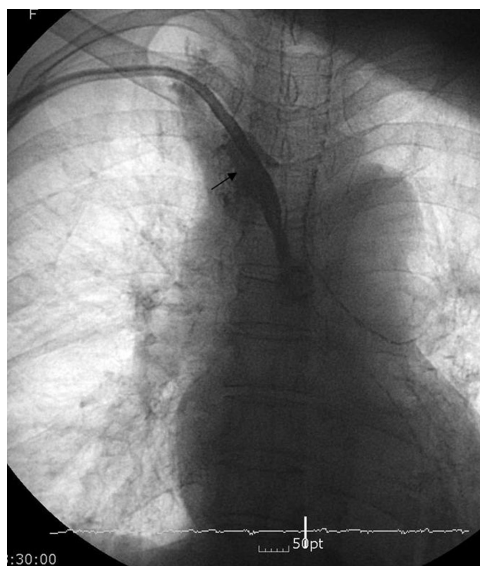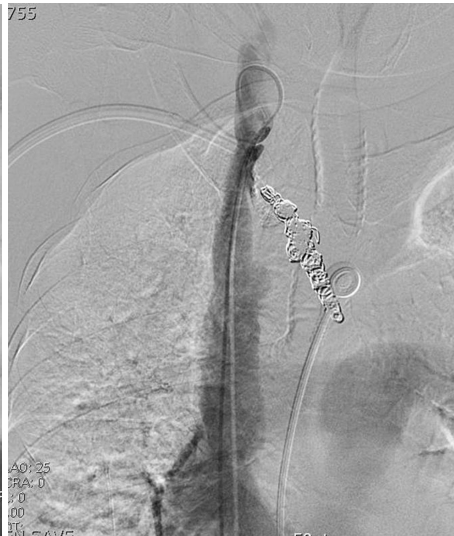Fig. 1. A 71-year-old female with epigastric pain.
A. Fistulography through the catheter shows contrast extravasation into the mediastinum (arrow).
B. Non-enhanced CT scan shows the hemodialysis catheter (arrow) outside the superior vena cava and extravasated contrast material in the mediastinum (arrow head) on approximately 10 cm above the right atrium. Right hemithorax and mediastinal hematoma are also noted.
C. Superior vena cavogram shows no demonstrable contrast extravasation.
D. After retraction of hemodialysis catheter into the SVC, Cavogram demonstrates that hemodialysis catheter perforates the superior vena cava and extravasation of contrast material along the catheter tract into the mediastinum.
E. The perforating tract of superior vena cava was embolized with microcoils. After microcoils embolization, extravasation of contrast material (arrow) was still seen.



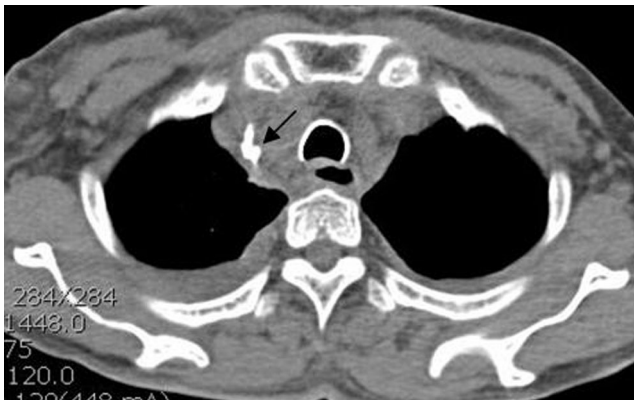F



G

Fig. 1. F and G. Additional embolization with N-butyl cyanoacrylate (arrow) was performed. Cavogram obtained after additional embolization reveals complete occlusion of perforated tract.

H. Non-enhanced CT scan obtained after post-operative 2 days shows accumulated N-butyl cyanoacrylate (arrow) and complete occlusion of perforated tract. A decreased amount of right hemothorax is noted.



H

1 가 , Morita (2) Florescu (1)
(Internal Jugular Vein)

1 .

Trapease (Cordis, Florida, U.S.A.)

1 ,

Wall Stent (Boston Scientifics, Calway,

Ireland)

1 ,

가

가

1 (3 - 5).

가 가

,

가

•

가

(6).

(Torque)

1

가

(1, 6 - 8).

가

가

가
가
(Peel - away) 가 ,

가

가

(Peel - away)

Peel - away

가

CT

가

, PermCath

N - butyl cyanoacrylate

, CT

N - butyl cyanoacrylate

가

:

naled by nonvisualization of catheter tip. *Hemodial Int* 2005;9:341-343

2. Morita Y, Sanuki M, Sera A, Kinoshita H. Perforation of the superior vena cava and hemothorax caused by insertion of a pulmonary artery catheter. *Masui* 2001;50:783-785

3. Hussain SD, McLafferty RB, Schmittling ZC, Zakaria AM, Ramsey DE, Larson JL, et al. Superior vena cava perforation and cardiac tamponade after filter placement in the superior vena cava: a case report. *Vasc Endovasc Surg* 2005;39:367-370

4. Smith SL, Manhire AR, Clark DM. Delayed spontaneous superior vena cava perforation associated with a SVC wallstent. *Cadiovasc Interv Radiol* 2001;24:286-287

5. Johnson LA, Alikan MA, Mehta P, Culp WC. Caval perforation with bronchial communication: a rare complication of long-term venous access. *J Vasc Interv Radiol* 2005;16:1149-1152

6. 2003;48:217-223

7. Lund GB, Trerotola SO, Scheel PF, Savader SJ, Mitchell SE, Venbrux AC, et al. Outcome of tunneled hemodialysis catheter placed by radiologist. *Radiology* 1996;198:467-472

8. Saliba WR, Goldstein LH, Nitzan O, Elias MS. Contralateral hemothorax: a late complication of subclavian vein catheterization. *Harefuah* 2004;143:97-98,168

1. Florescu MC, Moussa H, Salifu M, Friedman EA. Accidental extravascular insertion of a subclavian hemodialysis catheter is sig-

Endovascular Treatment of an Iatrogenic Superior Vena Cava Perforation Caused by the Placement of a Hemodialysis Catheter: A Case Report¹

See Hyung Kim, M.D., Young Hwan Kim, M.D., Dong Yoon Keum, M.D.²

¹*Department of Radiology, Dongsan Medical Center, Keimyung University College of Medicine*

²*Department of Thoracic and Cardiovascular Surgery, Dongsan Medical Center, Keimyung University College of Medicine*

The perforation of the superior vena cava during the placement of a tunneled hemodialysis catheter, via the subclavian vein, is a rare complication, and is manifested by hemothorax or hemopericardium. The treatment of this complication requires an early diagnosis and open thoracic surgery. Herein, we report a patient with hemothorax due to the perforation of the superior vena cava during the placement of a tunneled hemodialysis catheter via the right subclavian vein which was successfully treated by embolization by way of a coil and histoacryl.

Index words : Vena cava, superior
Catheterization
Embolization, therapeutic

Address reprint requests to : Young Hwan Kim, M.D., Department of Diagnostic Radiology, Dongsan Medical Center,
Keimyung University College of Medicine, 194 Dongsan-dong, Jung-gu, Taegu 700-712, Korea.
Tel. 82-53-250-7770 Fax. 82-53-250-7766 E-mail: yhkim68@dsmc.or.kr