

A Metastatic Adrenal Tumor from a Hepatocellular Carcinoma: Combination Therapy with Transarterial Chemoembolization and Radiofrequency Ablation¹

Hyun-Jin Lim, M.D., Yun Ku Cho, M.D., Yong-Sik Ahn, M.D., Mi-Young Kim, M.D.

The adrenal gland is the second most common site of metastasis from a hepatocellular carcinoma (HCC). Radiofrequency ablation (RFA) for these tumors has been reported to be a potentially effective alternative to an adrenalectomy, especially for inoperable patients. However, for intermediate or large adrenal tumors, combination therapy of transarterial chemoembolization (TACE) and RFA can be attempted as it may reduce the heat sink effect. A 74-year-old patient presented with abdominal discomfort. Abdominal CT images revealed a 5.0 cm sized right adrenal mass. A percutaneous biopsy of the adrenal mass revealed a metastatic hepatocellular carcinoma. TACE was performed on the adrenal mass. However, a one-month follow-up CT image revealed a residual viable tumor. RFA was performed for the adrenal tumor six weeks after the TACE. No procedure-related major complications were noted. The serum alpha-fetoprotein level had also been normalized after the treatment, and 10-month follow-up CT images showed no definite evidence of viable adrenal tumor.

Index words : Adrenal gland, neoplasms
Radiofrequency (RF), ablation

The Adrenal gland is the second most common site of metastasis from a hepatocellular carcinoma (HCC) (1). Surgical adrenalectomy has been reported to be an effective treatment for the metastatic tumors (2, 3). However, nonsurgical treatments such as transarterial chemoembolization (TACE) or percutaneous ethanol injection therapy (PEI) have also been reported as potentially equivalent alternatives for these tumors (4). Recently, radiofrequency ablation (RFA) for these tumors has also been reported with favorable clinical results, especially for inoperable patients (5, 6). For inter-

mediate or large adrenal tumors, however, complete necrosis of the adrenal tumors may not be achieved without difficulty. Combination therapy with transarterial chemoembolization (TACE) and RFA can be attempted for this situation. As with liver tumors, it can reduce the heat sink effect by the arterial feeders, and thus can increase the volume of the ablation. We report here a case of a 5.0 cm sized metastatic adrenal tumor from a HCC that was successfully treated with combination therapy of TACE and RFA.

Case Report

A 74-year-old man presented with abdominal discomfort and a palpable abdominal mass. An abdominal CT revealed a large liver mass with a measured diameter of 7 cm. The serum alpha-fetoprotein level (AFP) was mea-

¹Department of Radiology, Seoul Veterans Hospital
Received January 22, 2007 ; Accepted May 16, 2007
Address reprint requests to : Yun Ku Cho, M.D., Department of Radiology, Seoul Veterans Hospital
6-2 Dunchon-dong, Kangdong-gu, 134-060, Seoul, Korea
Tel. 82-2-2225-1426 Fax. 82-2-2225-1488
E-mail: yunkucho2004@yahoo.co.kr

sured as 138.3 ng/mL. A percutaneous liver biopsy revealed a histopathological diagnosis of HCC. As the patient did not want to undergo surgical treatment, TACE was performed for the liver mass. Follow-up CT images

obtained one month after the TACE demonstrated partial uptake of iodized oil (Lipiodol; Andre Guerbet, Aulnay-sous-Bois, France) for the mass, and no definite evidence of an abnormal nodular enhanced area.

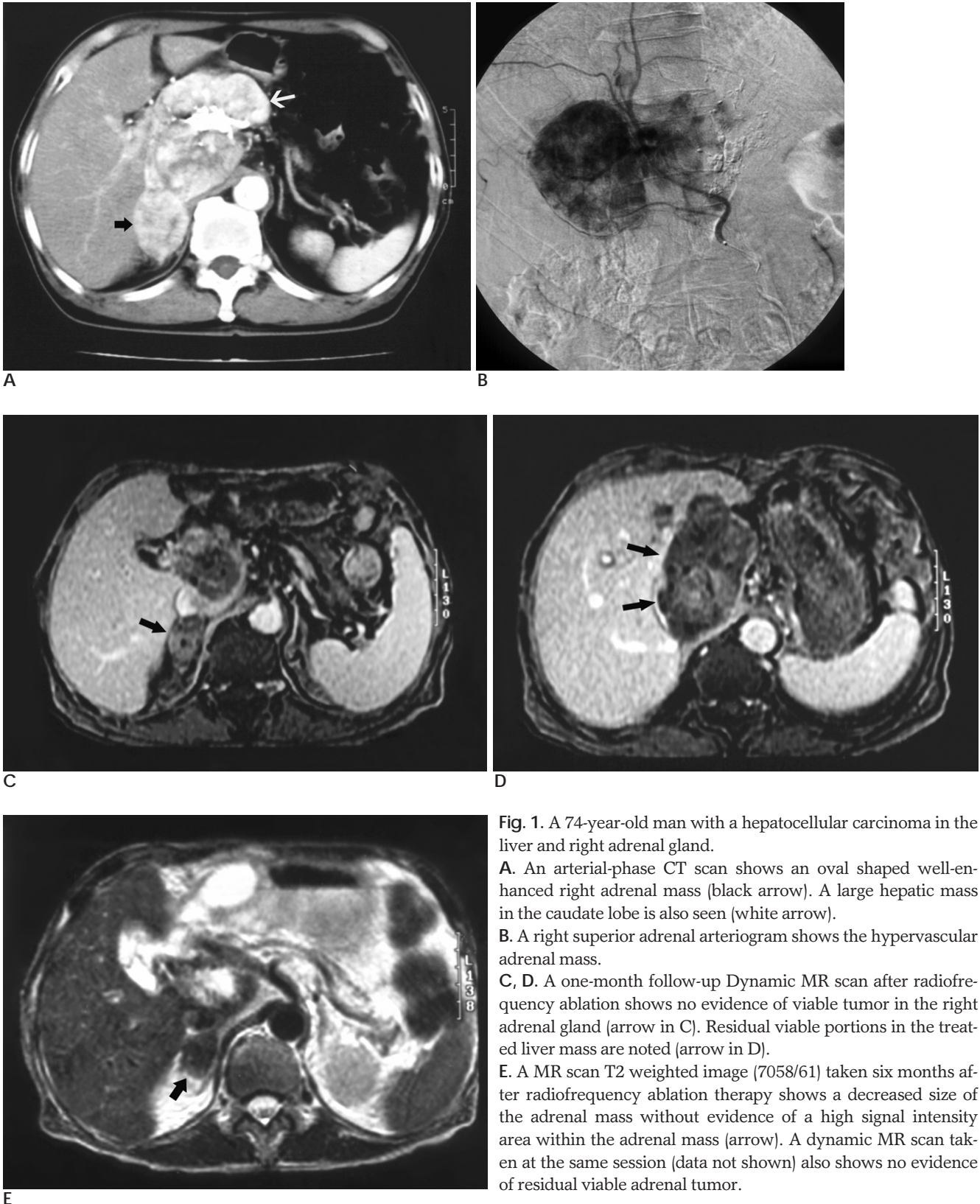


Fig. 1. A 74-year-old man with a hepatocellular carcinoma in the liver and right adrenal gland.

A. An arterial-phase CT scan shows an oval shaped well-enhanced right adrenal mass (black arrow). A large hepatic mass in the caudate lobe is also seen (white arrow).

B. A right superior adrenal arteriogram shows the hypervascular adrenal mass.

C, D. A one-month follow-up Dynamic MR scan after radiofrequency ablation shows no evidence of viable tumor in the right adrenal gland (arrow in C). Residual viable portions in the treated liver mass are noted (arrow in D).

E. A MR scan T2 weighted image (7058/61) taken six months after radiofrequency ablation therapy shows a decreased size of the adrenal mass without evidence of a high signal intensity area within the adrenal mass (arrow). A dynamic MR scan taken at the same session (data not shown) also shows no evidence of residual viable adrenal tumor.

After two years of follow-up loss for an unknown cause, the patient revisited our center. The patient did not undergo any other specific treatments for the liver tumor during this period. At this time, the serum AFP value was measured as 187.3 ng/mL. A contrast enhanced CT scan showed a large liver mass with interval growth with an approximate 9 cm diameter. In addition, a new right adrenal mass was found, contacting the large liver mass, with the maximal diameter measuring 5 cm (Fig. 1A). The adrenal mass showed prominent contrast enhancement on the arterial phase scan and washout of enhancement on the delayed phase scan, as did the large liver mass. A percutaneous biopsy for the adrenal mass revealed a metastatic HCC.

As the patient did not want to undergo surgical treatment, we planned to treat both the liver and adrenal mass with a nonsurgical interventional treatment. The tumor size seemed to be somewhat large for a single therapy of RFA. Therefore, TACE was planned first. After obtaining informed consent from the patient, we performed TACE. A right renal arteriography was performed to identify the arteries that fed the adrenal tumor. Hypervascular tumor staining was found, mainly fed by the right superior adrenal artery (Fig. 1B). Other feeding arteries were too fine to superselect.

Adrenal TACE was performed using a 13 mL suspension of iodized oil (Lipiodol; Andre Guerbet, Aulnay-sous-Bois, France) and 80 mL doxorubicin hydrochloride (Adriamycin. Sinpung, Seoul, Korea) via the right inferior adrenal artery. Then, gelatin sponge particles (Gelfoam; Upjohn, Kalamazoo, MI) mixed with 2 mg mitomycin-C (Kyowa; Kyowa Hakko Kogyo, Tokyo, Japan) were infused into the same arterial feeder. A post-embolization angiogram revealed no definite evidence of residual tumor staining in the right adrenal mass. No serious complications occurred during or after the procedure, except for transient abdominal pain and mild fever.

An abdominal CT scan obtained one month after the TACE demonstrated that the embolic material was partially distributed to the anteroinferior portion of the mass. However, the posteroinferior portion of the mass showed prominent early contrast enhancement, highly suggestive of a residual viable tumor. It was likely that the residual viable tumor was supplied by fine arterial branches as the main arterial feeder was completely occluded during the adrenal embolization. RFA was chosen as an additional treatment, because selective adrenal chemoembolization was very difficult to perform. The

right mid and superior adrenal artery were too fine to superselect.

Six weeks after the TACE, ultrasonography guided RFA was performed on the patient under conscious sedation, using a RF 2000 generator system (Radiotherapeutics, Mountain View, CA U.S.A.). A multitined expandable electrode (Leveen needle electrode; Radiotherapeutics) with an active zone of 3.5 cm was used. The output was initially adjusted to 50 watts, and was increased up to 80 watts by 10 watts every minute. Roll-off was obtained for two times. The total ablation time was about 9 minutes. The procedure was tolerable to the patient and no significant complications developed during and after the procedures, except for the transient high fever.

After RFA for the adrenal tumor, further treatment for the liver mass was performed with one session of TACE and four sessions of RFA.

Dynamic MR images one month after the adrenal RFA showed no definite evidence of viable adrenal tumor (Fig. 1C). However, residual viable portions were noted in the large liver mass (Fig. 1D), and an additional two sessions of RFA were performed for the enhancing lesions of the liver. A 6-month follow-up MR after the adrenal RFA revealed an adrenal mass without contrast enhancement (Fig. 1E). The diameter of the mass decreased from 5 cm to 3 cm, and the serum AFP level also had been normalized. MR images revealed no definite evidence of viable tumor in the liver or adrenal area. A ten-month follow-up CT also showed no definite evidence of recurred tumor in the liver or adrenal area. However, an incidental femur shaft fracture happened six months after the adrenal RFA. After surgery for the fracture, and a subsequent four-week administration of antibiotics, the liver function of the patient deteriorated. Thirteen months after the RFA for the adrenal mass, the patient died due to hepatorenal syndrome.

Discussion

Successful surgical treatment had been reported for the treatment of an adrenal metastasis from a HCC (2 - 4). There have been few reports in the literature that have examined combination therapy with TACE and RFA for metastatic adrenal HCC.

TACE of the metastatic adrenal tumor was reported by O'keeffe et al. (7). However, TACE may have only a very limited role in the treatment of an adrenal mass because of the complex arterial network of the adrenal

gland (7, 8). TACE can also cause potential complications such as marked hypertension or tachycardia by a massive release of catecholamines from the embolized normal part of the adrenal gland during the procedure (1). However, in this study, there was no significant hemodynamic change during and after the TACE. We think that this lack of a hemodynamic change resulted as most of the normal adrenal gland tissue was already replaced by the tumor.

RFA can also treat liver masses up to 4 - 5 cm in the maximal diameter. However, for intermediate or large tumors, the local tumor progression rate is relatively high, compared to a small sized tumor (<3 cm). For these tumors, combination treatment with TACE and RFA can be a more effective treatment modality for local tumor control.

RFA for adrenal tumors can be performed with a similar technique for liver masses. The indications can be also similar, that is, up to 4 - 5 cm in the maximal diameter. For a small tumor less than 3 cm, single RFA therapy would be sufficient. However, for intermediate sized adrenal masses, combination therapy of TACE and RFA would be more effective because of the following potential advantages. Pre-ablation TACE can accentuate the effect of RFA, because occlusion of the arterial feeder for the mass can lead to a wider area of ablation by reducing the heat sink effect. Pre-ablation TACE can also reduce the viable tumor volume before RFA (9). The same effect can also be applied for the treatment of an adrenal mass. In this study, sequential treatment with TACE and RFA resulted in complete remission of the adrenal tumor over a 6 month time period. This suggests that RFA, when combined with TACE, has the potential to be an effective alternative treatment to a surgical adrenalectomy. This study also suggests the possibility that primary or other secondary adrenal tumors may be treated effectively with the combination therapy of TACE and RFA.

In this study, the ablation time was relatively short (9 minutes). Roll-off was obtained relatively earlier than for usual liver masses. We think that fatty tissue around the adrenal gland may function as an insulator for heat conduction. This suggests that RFA can be an effective treatment modality for the treatment of an adrenal mass.

CT guided RFA also can be an effective treatment procedure for a metastatic adrenal HCC as the combination therapy with TACE and RFA (5). Further studies will be needed to evaluate these treatment modalities for

metastatic adrenal tumors. PEIT can be another effective nonsurgical treatment for adrenal masses. Shibata et al. reported effective adrenal tumor control with PEIT (10). However, PEIT is expected to be effective only for small unilateral metastatic nodules, and would have limited value for large or bilateral metastases (10).

There are several limitations in this study. First, the follow-up period was relatively short. A longer period of follow-up would be more helpful for the evaluation of the ultimate clinical usefulness of the combination treatment. Second, survival gain from this combined treatment was not definite. However, this study clearly showed that combination therapy with TACE and RFA could be an effective alternative treatment for a metastatic adrenal HCC.

In conclusion, sequential treatment with TACE and RFA may be an effective alternative treatment for a metastatic adrenal HCC, especially when surgery is not indicated. Further large scale studies may be needed to evaluate the safety and efficacy of this procedure.

References

1. Ha-Kawa SK, Harima K, Tanaka Y, Akashi Y, Koreeda C, Uchiyama S, et al. A clinical evaluation of distant metastases from a hepatocellular carcinoma with reference to location, frequency, symptoms, treatment & prognosis. *Gan No Rinsho* 1990;36:2012-2016
2. Rousselet JM, Sebbag H, Henry L, Paliard P, Partensky C. Adrenal metastases of hepatocellular carcinoma : therapeutic options. *Chirurgie* 1998;123:280-286
3. Kim SH, Brennan MF, Russo P, Burt ME, Coit DG. The role of surgery in the treatment of clinically isolated adrenal metastasis. *Cancer* 1998;82:389-394
4. Momoi H, Shimahara Y, Terajima H, Iimuro Y, Yamamoto N, Yamamoto Y, et al. Management of adrenal metastasis from hepatocellular carcinoma. *Surg Today* 2002;32:1035-1041
5. Mayo-Smith WW, Dupuy D. Adrenal Neoplasms: CT-guided Radiofrequency ablation-preliminary results. *Radiology* 2004;231:225-230
6. Haga H, Saito T, Okumoto K, Sugahara K, Takeda T, Saito K, et al. Successful percutaneous radiofrequency ablation of adrenal metastasis from hepatocellular carcinoma. *J Gastroenterol* 2005;40:1075-1076
7. O'Keefe FN, Carrasco CH, Charnsangavej C, Richli WR, Wallace S. Arterial embolization of adrenal tumors: results in nine cases. *AJR Am J Roentgenol* 1988;151:819-822
8. Dyson M. *Endocrine system*. In Williams PL. *Gray's Anatomy*. 38th ed. New York: Churchill Livingstone, 1995;1900-1905
9. Lu DS, Raman SS, Vodopich DJ, Wang M, Sayre J, Lassman C. Effect of vessel size on creation of hepatic radiofrequency lesions in pigs: assessment of the "heat sink" effect. *AJR Am J Roentgenol* 2002;178:47-51
10. Shibata T, Maetani Y, Ametani F, Itoh K, Konishi J. Percutaneous ethanol injection for treatment of adrenal metastasis from hepatocellular carcinoma. *AJR Am J Roentgenol* 2000;174:333-335

