

Naviculo-Medial Cuneiform Coalition: Radiological Features¹

Yun Sun Choi, M.D., Sung Moon Kim, M.D.², Kyung Tae Lee, M.D.³, Ki Won Young, M.D.³,
Sang Jin Bae, M.D.², Joong Mo Ahn, M.D.⁴, Myung Jin Shin, M.D.²

Purpose: To define the radiological features of the naviculo-medial cuneiform coalition.

Materials and Methods: This study examined 35 feet from 25 patients (mean age 26 years) with a naviculo-medial cuneiform coalition. The images were analyzed retrospectively with regard to irregular articular surface, subchondral sclerosis, subchondral cyst, beak-like spur, the change in joint space, bony fusion seen on plain radiographs ($n=35$) and CT ($n=14$), and the histological type of coalition on MRI ($n=3$). The extent of joint involvement was also evaluated.

Results: Of the 35 feet, plain radiographs and/or CT showed an irregular articular surface in 34 (97.1%), subchondral sclerosis in 30 (85.7%), a subchondral cyst in 29 (82.9%), a beak-like spur in 23 (65.7%), a narrowing of the joint space in 24 (68.6%) and no bony fusions (0%). The T1-weighted images revealed low signal intensity, and the T2-weighted fast spin-echo and gradient images revealed high signal intensity in the three feet with a cartilaginous coalition. The coalition involved the plantar part of the joint in all 35 feet.

Conclusion: The characteristic radiological features of a naviculo-medial cuneiform coalition include an irregular articular surface with possible secondary degenerative changes in the plantar margin of the joint, non-osseous type.

Index words : Foot, abnormalities
Foot, radiography
Foot, CT
Foot, MR

A tarsal coalition is an abnormal fusion of fibrous (syn-
desmosis), cartilaginous (synchondrosis), or osseous

(synostosis) tissues between the tarsal bones in the hind
and midfoot. This union can be either congenital or ac-
quired (1 - 4). The most commonly reported tarsal coali-
tions are the calcaneonavicular and talocalcaneal. Other
coalitions including the talonavicular, calcaneocuboid,
and cubonavicular have also been reported, but with
much lower frequency (1 - 3). In addition, there have
been few cases of a naviculocuneiform coalition be-
tween the navicular and one or more of the cuneiform
bones (5 - 12). Miki et al first reported an isolated nav-
iculo-medial cuneiform coalition in 1979, which was
then believed to be an extremely rare condition (7).
However, in 1996, Kumai et al reported an isolated nav-

¹Department of Radiology, Eulji Hospital, Eulji University School of Medicine

²Department of Radiology, Asan Medical Center, University of Ulsan College of Medicine

³Department of Orthopedic Surgery, Eulji Hospital, Eulji University School of Medicine

⁴Department of Radiology, Samsung Medical Center, Sungkyunkwan University

This article was supported by 2002 Eulji research grant (EJRG-02-013-12E25).

Received June 14, 2005 ; Accepted August 3, 2005

Address reprint requests to : Yun Sun Choi, M.D., Department of Radiology, Eulji Hospital, 280-1, Hagye 1-dong, Nowon-gu, Seoul 139-711, Korea.

Tel. 82-2-970-8290 Fax. 82-2-970-8346 E-mail: cys0128@eulji.or.kr

iculo-medial cuneiform coalition in 60 feet from 40 patients, which showed that its incidence was much greater than previously reported (13). Nevertheless, to our knowledge, the radiological findings of a naviculo-medial cuneiform coalition have not been reported in radiology literature. A lack of knowledge and understanding of the radiological findings of this condition may result in it being overlooked in many patients.

The aim of this study was to define the plain radiographic, computed tomography (CT) and magnetic resonance (MR) imaging findings of a naviculo-medial cuneiform coalition.

Materials and Methods

Clinical data

Thirty-five feet from 25 patients (10 bilateral, 10 male, 15 female; mean age 26 years; range 10-43 years) with a naviculo-cuneiform coalition, which was clinically and radiographically confirmed between March 1997 and September 2003, were included. The cases were collected from three centers and were identified by reviewing various orthopedic databases. In all cases, experienced orthopedic foot surgeons performed the physical examinations. There was no history of inflammatory arthritis nor was there any swelling at the medial midfoot area in any of the cases examined. Twenty-two of the 35 feet (62.9%) were symptomatic (mean age 24 years; range 10 - 43 years) and 13 (37.1%) reported no pain (mean age 28 years; range 14 - 42 years). The most common symptom was pain on the plantar side of the midfoot. The pain was aggravated by standing or walking for lengthy periods of time and by physical activity such as soccer or judo in 11 out of 22 feet. The 22 symptomatic feet received non-steroid anti-inflammatory medication for 6 months and four of them were given additional arch supports. The symptoms were relieved by conserv-

ative treatment in 19 out of 22 feet, while the other three had persistent pain and received a fusion of the naviculo-medial cuneiform joint after resecting the coalition. The 13 asymptomatic feet were found incidentally on plain radiographs performed during an evaluation of a calcaneal or navicular fracture ($n=5$), osteoarthritis of the first metatarsophalangeal joint ($n=4$), hallux valgus ($n=3$) and an instability of the intertarsal joints ($n=1$).

Radiological assessment

The radiological methods used in this study were plain radiographs ($n=35$), CT ($n=14$), and MR imaging ($n=3$). The plain radiographs of the foot were anteroposterior, lateral and oblique. CT was performed using either spiral CT or a 16 channel multi-detector CT machine. The CT images were as follows: an axial or reconstructed axial parallel to the naviculo-cuneiform joint, a reconstructed sagittal and a coronal perpendicular to the naviculo-cuneiform joint with a slice thickness ranging from 1.25 to 1.5 mm. MR imaging was performed using various 1.5-T systems. T1-weighted spin-echo (TR/TE, 500 - 550/12 - 20 msec), T2-weighted fast spin-echo (TR/TE, 3000 - 4000/96 msec) and gradient echo (608/18 msec, flip angle; 20 degree) images were obtained. The field of view ranged from 12 to 18 cm, slice thickness ranged from 3 to 4 mm with a 0 - 0.8 mm inter-slice gap, and the matrix was 256 by 256. All of the imaging methods were reviewed retrospectively by a reviewer with no knowledge of the patients' clinical information. In all cases the findings were obtained by consensus of two musculoskeletal radiologists. The images were analyzed with regard to irregular articular surface, subchondral sclerosis, subchondral cyst, beak-like spur, change of the joint space (narrow or wide), bony fusion and the extent of joint involvement on plain radiographs and/ or CT. The extent of joint involvement was evaluated on the lateral plain radiograph and/ or the reconstructed

Table 1. Plain Radiographic and/ or CT Findings of the Naviculo-Medial Cuneiform Coalition

	Symptomatic feet ($n=22$)	Asymptomatic feet ($n=13$)	Total ($n=35$)
Cortical irregularity	22 (100%)	12 (92.3%)	34 (97.1%)
Subchondral sclerosis	18 (81.8%)	12 (92.3%)	30 (85.7%)
Subchondral cyst	19 (86.4%)	10 (76.9%)	29 (82.9%)
Beak-like spur	15 (68.2%)	8 (66.7%)	23 (65.7%)
Change of joint space	16 (72.7%)	9 (69.2%)	25 (71.4%)
Narrowing	15 (68.2%)	9 (69.2%)	24 (68.6%)
Widening	1 (4.5%)		1 (2.9%)
Intraarticular loose body	2 (9.1%)	1 (7.7%)	3 (8.6%)
Dorsal spur at navicular	0 (0%)	1 (7.7%)	1 (2.9%)
Bony fusion	0 (0%)	0 (0%)	0 (0%)

sagittal CT images. Irregular articular surfaces were defined as irregular deformities of the opposing surfaces of the abnormal articulation; subchondral sclerosis was defined as an increased density of the subchondral bone; subchondral cysts were defined as subchondral lucences with a cavity; and beak-like spurs were defined as bony excrescences at the articular margin. MR imaging was also used to analyze the signal intensity on the articular side of the lesion which suggests the histologic type of coalition.

Associated abnormalities such as a peroneal spastic foot or a flat foot, a talar neck deformity, osteonecrosis of the navicular bone were also evaluated by reviewing the clinical data and examining the radiological results.

Results

Plain radiographs ($n=35$) and/ or CT ($n=14$) showed an irregular articular surface in 34 out of 35 feet (97.1%), subchondral sclerosis in 30 feet (85.7%), a subchondral cyst in 29 feet (82.9%), a change in the joint space in 25 feet (narrowing; $n=24$, widening; $n=1$) (71.4%), and a

beak-like spur at the medial articular margin of the medial cuneiform and navicular bone in 23 feet (65.7%) (Fig. 1 - 3). No bony fusions were found in any of the 35 feet. Plain radiographs and/or CT also showed an intraarticular loose body in three feet. Two of them had a navicular fracture and one foot had a dorsal spur on the navicular bone. Table 1 shows the radiological findings in the symptomatic and asymptomatic feet. The plantar part of the naviculo-medial cuneiform joint was involved in all 35 feet (100%), and the dorsal half of the joint was involved in one. MR showed a low signal intensity on T1-weighted, a high signal intensity on T2-weighted fast spin-echo and a high signal intensity lesion on gradient (T2*) image with an irregular articular surface in the plantar margin of the joint, suggesting a partial cartilaginous coalition in all three symptomatic feet that had been examined by MRI. One of those was confirmed during surgery as being a cartilaginous union (Fig. 3).

There were no associated abnormalities such as a peroneal spastic foot or a flat foot, a talar neck deformity, or osteonecrosis of the navicular bone in the tarsal bones and joints.

Discussion

The tarsal coalition has been reported in Western countries as being predominantly calcaneonavicular and talocalcaneal coalitions. There were only 10 cases of isolated naviculo-medial cuneiform coalitions reported before Kumai et al reported 60 cases. The reported cases were Japanese, Hispanics and people from African descent (7 - 13). Kumai et al classified the morphology of this coalition into three patterns, an irregular type, a cystic type and a combined type using CT with clinical analysis (13). Sato et al described this coalition as being an irregular osteolytic and peripheral sclerotic change in the joint surface and an osseous fusion of the joint (11). Green et al reported an irregularity between the navicular bone and the medial cuneiform bone, as well as an erosive change and a bony coalition (synostosis) (12).

In this study, plain radiographic and CT findings of most cases revealed an irregular articular surface, subchondral sclerosis and a subchondral cyst. Narrowing of the naviculo-medial cuneiform joint space and a beak-like spur at the medial margin of the naviculo-medial cuneiform joint was also seen in several cases. Histopathological analysis was performed in three cases and these findings indicated fibrocartilaginous coali-

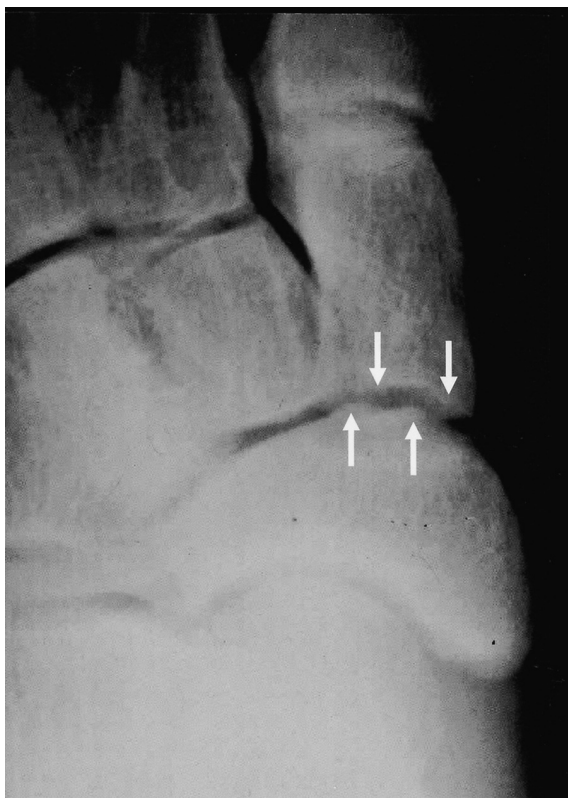


Fig. 1. 17-year-old female judo player with a painful naviculo-medial cuneiform coalition in her right foot. Anteroposterior radiograph shows an irregular articular surface of the naviculocuneiform joint (arrows). The joint space appears to be maintained.

tions. None of the cases showed an osseous coalition. Miki *et al* reported that most naviculo-cuneiform coalitions consist histologically of fibrous connective tissue containing islands of scattered chondroid tissue (8). Subchondral sclerosis, subchondral cysts, beak-like spurs and a marked narrowing of the joint space, were believed to be a reactive bone change in fibrocartilaginous naviculo-medial cuneiform coalition. Intra-articular loose bodies were seen in three cases, and were considered to be osteocartilaginous fragments. It is believed that in the isolated naviculo-medial cuneiform coalition, a fibrocartilaginous coalition may cause microfractures and remodeling on the borders between the underlying bone and the coalition, which can then lead to secondary degenerative changes. These changes may resemble osteoarthritis.

In all cases, the plantar site of the naviculo-medial cuneiform joint had continuous fibrocartilaginous tissue, and the dorsal site was a normal joint surface with the exception of one case. These changes are believed to be characteristic of this condition because they are

rarely observed in other types of coalitions. Many cases of naviculo-medial cuneiform coalition have either been overlooked or diagnosed as osteoarthritis, bony cysts or inflammatory synovitis (6, 13). In osteoarthritis, the dorsal portion of the joint is obliterated with large dorsal spurs and the articular surface is not irregular, which is different from those observed in a naviculo-medial cuneiform coalition. Subchondral sclerosis and beak-like spurs are usually not detected in inflammatory synovitis such as in a rheumatological process.

An association between a naviculocuneiform coalition and Kohler's disease of the tarsal navicular bone has been suggested, but this association was not seen in this study (6). There was no evidence of a peroneal spastic foot, which has been observed in other tarsal coalitions.

In this study, 22 out of 35 feet (62.9%) were symptomatic. Sato *et al* reported that the pain was the result of a weakness in the cartilagenous bridges relative to the weight-bearing force over the naviculo-medial cuneiform joint (11). Naviculo-medial cuneiform coalitions may also be discovered incidentally in asymptomatic feet (12, 13).

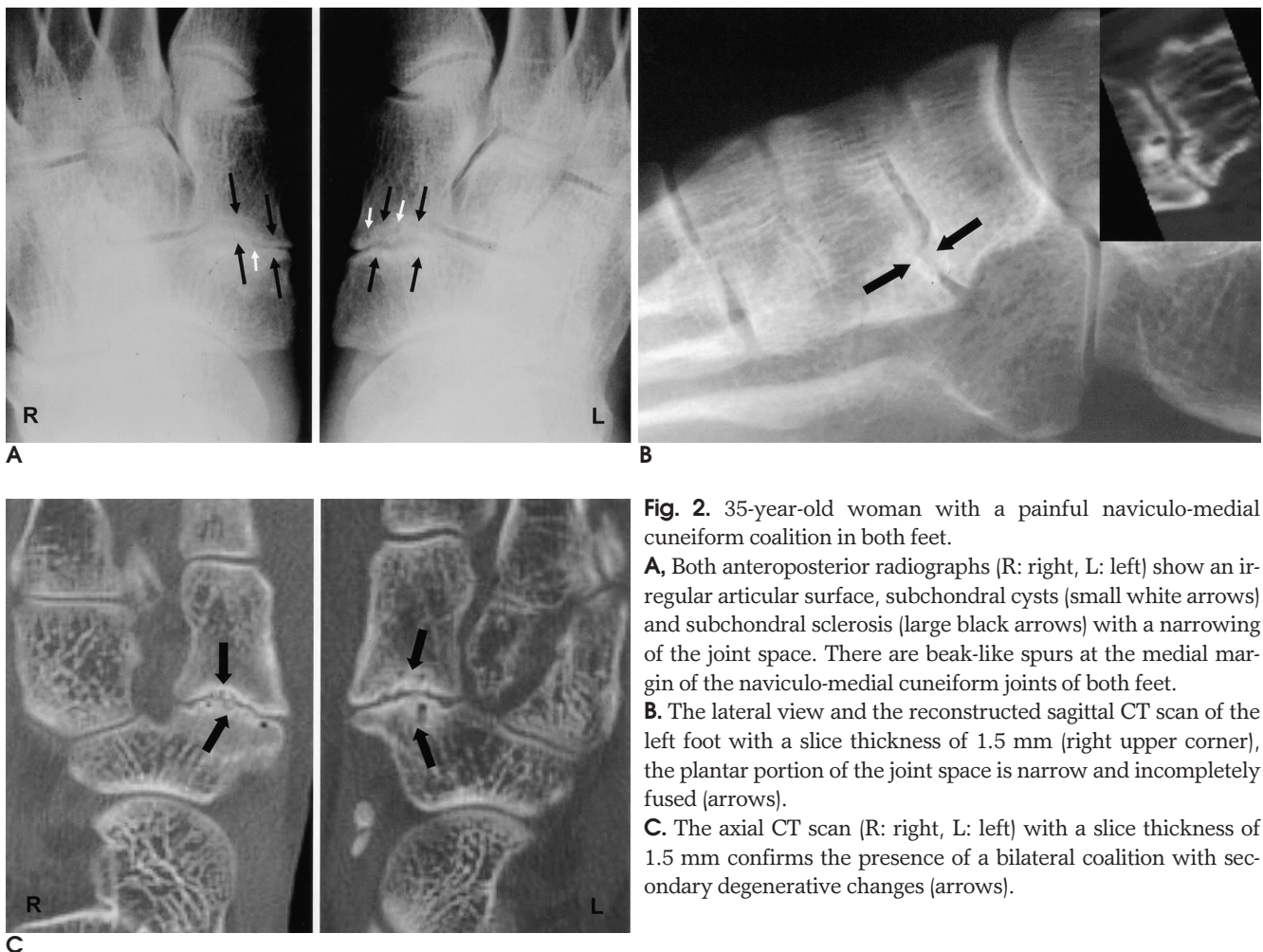


Fig. 2. 35-year-old woman with a painful naviculo-medial cuneiform coalition in both feet.

A. Both anteroposterior radiographs (R: right, L: left) show an irregular articular surface, subchondral cysts (small white arrows) and subchondral sclerosis (large black arrows) with a narrowing of the joint space. There are beak-like spurs at the medial margin of the naviculo-medial cuneiform joints of both feet.

B. The lateral view and the reconstructed sagittal CT scan of the left foot with a slice thickness of 1.5 mm (right upper corner), the plantar portion of the joint space is narrow and incompletely fused (arrows).

C. The axial CT scan (R: right, L: left) with a slice thickness of 1.5 mm confirms the presence of a bilateral coalition with secondary degenerative changes (arrows).

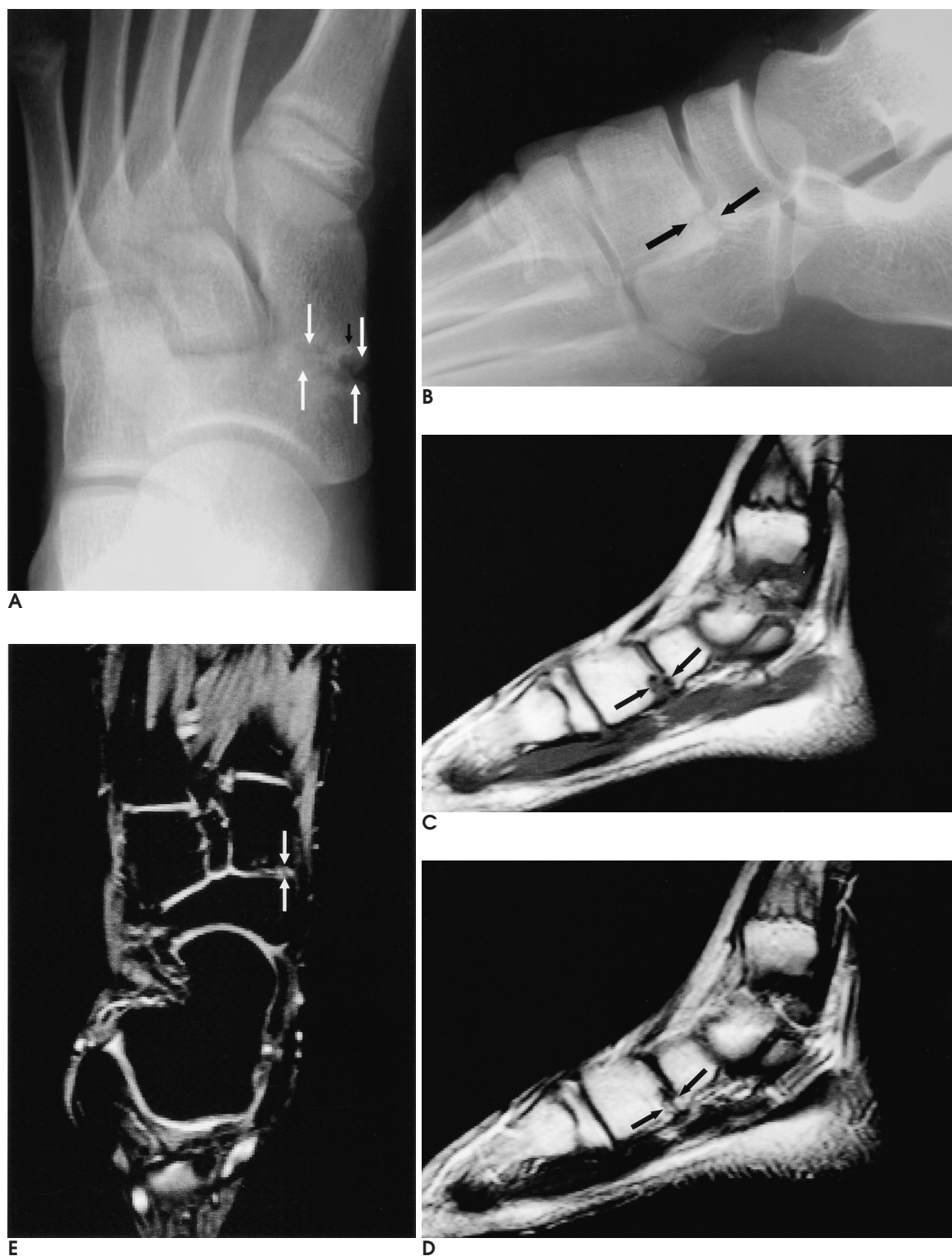

Fig. 3. 11-year-old boy with a surgically confirmed naviculo-medial cuneiform coalition in his right foot.
A, B. Anteroposterior (**A**) and lateral (**B**) radiographs show a cortical irregularity (large arrows) and a subchondral cyst (small arrow) with reactive sclerosis on the medioplantar side of the naviculo-medial cuneiform joint.
C. Sagittal T1-weighted spin echo image (TR/TE, 500/12) shows a low signal-intensity fusion on the plantar side of the naviculo-medial cuneiform joint (arrows).
D, E. Sagittal T2-weighted (**D**) fast spin-echo (TR/TE, 3000/96) and axial T2* (**E**) (TR/TE, 608/18, flip angle 20 degree) images show high signal intensity of this lesion with an irregular articular surface (arrows). This was confirmed at surgery as being a cartilaginous coalition.

In this study, 13 of the 35 feet (37.1%) were discovered incidentally on plain radiographs. In Kumai's report, 15 of 60 cases (25%) were asymptomatic (13), which raises the question as to the overall incidence of this type of coalition. It is possible that more cases exist, but they have gone undetected because of their asymptomatic nature. Symptoms may not appear in the early stages because the naviculo-medial cuneiform coalition occurs in a joint with a small range of motion (14).

A radiological diagnosis of this entity can be made using plain radiographs. CT confirmed the presence of a coalition along with its precise extent, and MR imaging helped determine the histological type of the naviculo-medial cuneiform coalition.

In conclusion, the characteristic radiological features of the naviculo-medial cuneiform coalition include an irregular articular surface with possible secondary degenerative changes in the plantar margin of the joint, non-ossseous type.

References

1. Varner KE, Michelson JD. Tarsal coalition in adults. *Foot Ankle Int* 2000;21:669-672
2. Newman JS, Newberg AH. Congenital tarsal coalition: multimodality evaluation with emphasis on CT and MR imaging. *Radiographics* 2000;20:321-332
3. Stormont DM, Peterson HA. The relative incidence of tarsal coalition. *Clin Orthop Relat Res* 1983;181:28-36
4. Leonard MA. The inheritance of tarsal coalition and its relationship to spastic flatfoot. *J Bone Joint Surg Br* 1974;56-B:520-526.
5. Lusby HL. Naviculo-cuneiform synostosis. *J Bone Joint Surg Br* 1959;41-B:150
6. Gregersen HN. Naviculocuneiform coalition *J Bone Joint Surg Am* 1977;59-A:128-130
7. Miki T, Oka M, Shima M and Tanaka S. Naviculocuneiform coalition: a case report. *J Foot Surg* 1979;18:81-82
8. Miki T, Yamamuro T, Iida H, Ohta S and Oka M. Naviculocuneiform coalition. A report of two cases. *Clin Orthop Relat Res* 1985;196:256-259
9. Hynes RA, Romash MM. Bilateral symmetrical synchondrosis of navicular first cuneiform joint presenting as a lytic lesion. *Foot Ankle* 1987;8:164-168
10. Wiles S, Palladino SJ and Stavosky JW. Naviculocuneiform coalition *J Am Podiatr Assoc* 1988;78:355-360
11. Sato K, Sugiura S. Naviculo-cuneiform coalition-report of three cases. *Nippon Seikeigeka Gakkai Zasshi* 1990;64:1-6
12. Green MR, Yanklowitz B. Asymptomatic naviculocuneiform synostosis with a ganglion cyst. *J Foot Surg* 1992;31:272-275
13. Kumai T, Tanaka Y, Takakura Y and Tamai S. Isolated first naviculocuneiform joint coalition. *Foot Ankle Int* 1996;17:635-640
14. Jack EA. Naviculo-cuneiform fusion in the treatment of flat foot. *J Bone Joint Surg Br* 1953 ;35-B:75-82

2005;53:381 - 386

가 25 (26), 35 (35
(14)
(85.7%), 29 (82.9%), 23 (65.7%), 24 (68.6%)
(0%). (T2*)
T1 , T2
35