

(anterior cerebral artery)

(carotid - ACA anastomosis)

(infraoptic course of ACA)

30 가 (1, 2).

(internal carotid artery)

(infraoptic ACA)

가

A1

가

A1

80%

(3).

Robinson

30

1959

가 (2).

(ophthalmic artery)

47

가 20

5

가

3 - D time of flight

(ophthalmic artery)

(source image)

(optic nerve)

(optic chiasm)

(anterior communicating artery)

(persistent trigeminal artery)

(basilar artery)

A1

A1

(Figs. 1A - 1D).

(Figs. 1A - 1D).

(early bifurcation of

(enlargement of prechi -

ICA) (4),

asml anastomosis) (5, 6),

:

(persistence in uterocommunication between the primitive dorsal and ventral ophthalmic artery) (5, 7),
 (anastomosis between branches of primitive olfactory and primitive maxillary arteries) (5, 6)
 가 , (superior hypophyseal artery) , 가

A1 가 (2).
 가 가 가 (2, 7).
 가 가 -
 (ACA - AcomA complex) ,
 (1). - (carotid - basilar artery anastomosis) (8), (9),
 A1 (7),
 (fused pericallosal artery) (10), (flex -

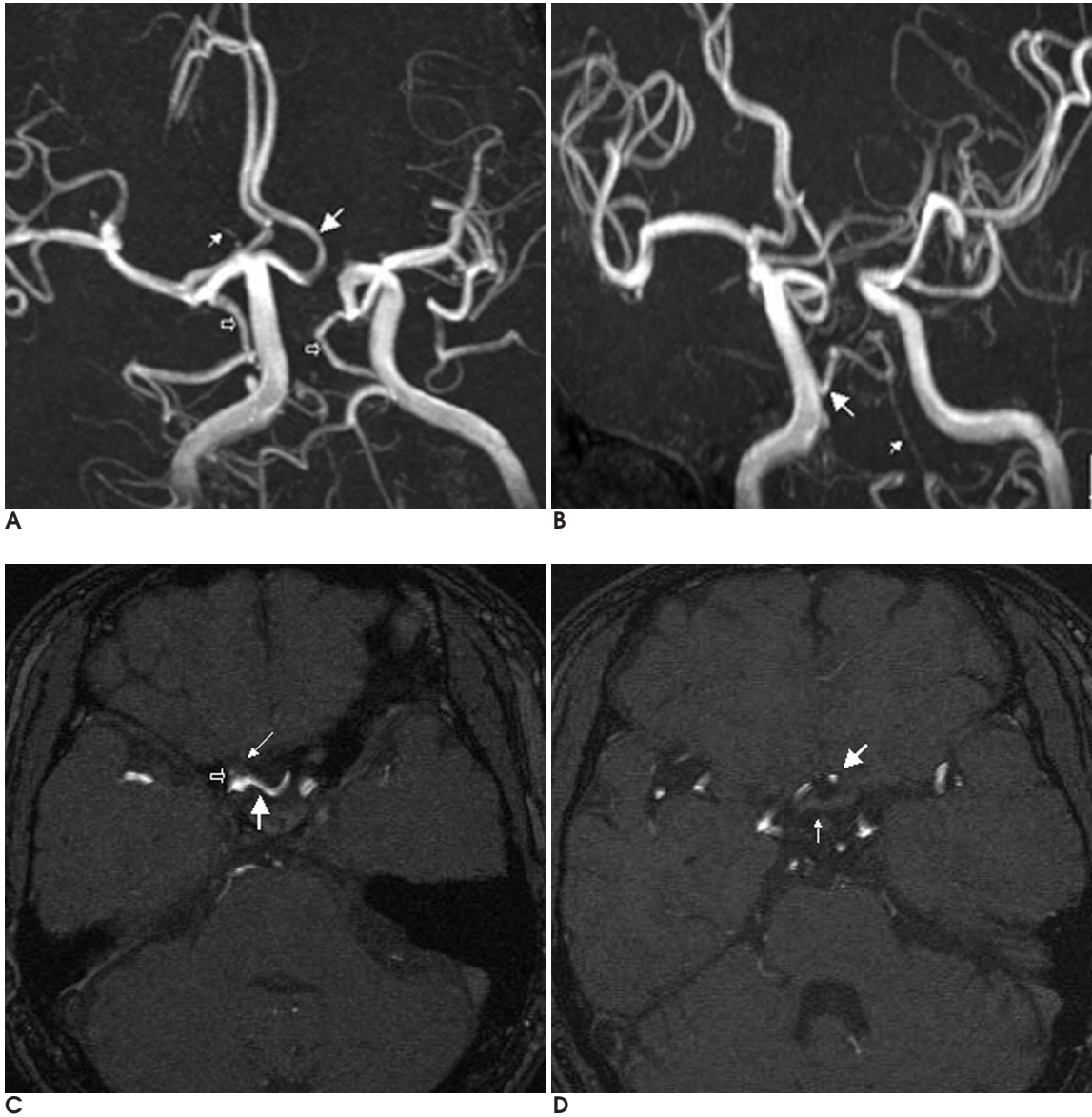


Fig. 1. A-D. Angiographic (**A, B**) and source images of a 3D TOF MR angiography (**C, D**). The left anterior cerebral artery (large arrow, **A**) is arising from the right ICA at the origin of the ophthalmic artery (small arrow, **A**). Both posterior communicating arteries (open arrows, **A**) are directly connected to both posterior cerebral arteries. The right persistent trigeminal artery (large arrow, **B**) is arising from right internal carotid artery and anastomosing with hypoplastic basilar artery (small arrow, **B**). Note left A1 segment agenesis. The infraoptic anterior cerebral artery (large arrow, **C** and **D**) arising contralateral ICA at the level of ophthalmic artery origin (open arrow, **C**) passes under the right optic nerve (small arrow, **C**), and then ascends anterior to the optic chiasm (small arrow, **D**) to join the normal positioned anterior communicating artery (large arrow, **D**).

iform AcomA) (10)

tent trigeminal artery)

A1

가

가

가

가

1

Neuroradiol 2002;23:452-454

2. Spinnato S, Pasqualin A, Chioffi F, Da Pian R. Infraoptic course of the anterior cerebral artery associated with an anterior communicating artery aneurysm: anatomic case report and embryological considerations. *Neurosurgery* 1999;44:1315-1319
3. Maurer J, Maurer E, Perneczky A. Surgically verified variations in the A1 segment of the anterior cerebral artery: report of two cases. *J Neurosurg* 1991;75:950-953
4. Rosenorn J, Ahlgren P, Ronde F. Preoptic origin of the anterior cerebral artery. *Neuroradiology* 1985;27:275-277
5. Nutik S, Dilenge D. Carotid-anterior cerebral artery anastomosis: case report. *J Neurosurg* 1976;44:378-382
6. Padget DH. The development of the cranial arteries in the human embryo. *Contrib Embryol* 1948;32:207-262
7. Otake G. Carotid-anterior cerebral artery anastomosis with aneurysm: case report and review of the literature. *Neurosurgery* 1988;23:654-658
8. Teal JS, Rumbaugh CL, Segall HD, Bergeron RT. Anomalous branches of the internal carotid artery. *Radiology* 1973;106:567-573
9. Turnbull I. Agenesis of the internal carotid artery. *Neurology* 1975;12:588-590
10. McCormick W. A unique anomaly of the intracranial arteries of man. *Neurology* 1969;19:77-80

1. Curtis A Given II, P Pearse Morris. Recognition and importance of an infraoptic anterior cerebral artery: case report. *AJNR Am J*

J Korean Radiol Soc 2005;53:165 - 167

Infraoptic Anterior Cerebral Artery Arising from Contralateral Internal Carotid Artery: Case Report¹

Myong-Jin Kang, M.D.

¹Department of Diagnostic Radiology, College of Medicine Dong-A University

We report an unusual case of an anomalous origin of the anterior cerebral artery from the contralateral internal carotid artery at the level of the origin of the ophthalmic artery, which was discovered incidentally by MRI and MR angiography.

Index words : Cerebral blood vessel, MR Angiography

Address reprint requests to : Myong-Jin Kang, M.D., Department of Diagnostic Radiology, Dong-A University College of Medicine, 1, 3-Ga Dongdaeshin-dong, Seo-gu, 602-715 Pusan, Korea.
Tel. 82-51-240-5354 Fax. 82-51-253-4931 E-mail: myong69@dreamwiz.com