

# Treatment of Pulmonary Arteriovenous Malformation Using Platinum Coils: Case Report<sup>1</sup>

Man Deuk Kim, M.D., Jeung Sook Kim, M.D., Chang Young Lim, M.D.<sup>2</sup>

Pulmonary arteriovenous malformation (PAVM) is an abnormal direct communication between the pulmonary arteries and veins without any capillary network. The patients may be completely asymptomatic or may they develop serious complications including hemoptysis and brain abscess. We present here a case of incidentally found PAVM in a 33-year-old male who underwent embolization using platinum coils. Coil embolization is a safe, highly effective procedure that should be considered more often for the treatment of PAVM.

**Index words :** Embolization

Lungs, arteriovenous malformation

Platinum coils

Pulmonary arteriovenous malformation (PAVM) causes right-to-left blood shunting and if it is not treated, it may lead to chronic hypoxemia and other serious clinical manifestations (1 - 3). Detachable balloons and metallic coils are the embolotherapy devices that have been most commonly used to treat PAVM (4, 5). Platinum coils have recently become available as embolotherapy devices (6, 7). To the best of our knowledge, treatments for PAVM using platinum coils have never been reported in the Korean literature. Therefore, we describe a case of PAVM and its endovascular treatment using platinum coils, and we include a review of the relevant literature.

## Case Report

A 33-year-old male was admitted to the hospital due to

an abnormal mass on the left lower lobe of the lung. Plain chest radiograph and Computed Tomography (CT) revealed a 4.2 × 3.2 cm sized, ovoid shaped and well demarcated vascular mass with a feeding artery that measured 5 mm and a draining vein, and these findings were compatible with a PAVM (Fig. 1A). The patient had no specific symptoms such as dyspnea or exercise intolerance. Specifically, there was no cutaneous telangiectasia suggestive of hereditary hemorrhagic telangiectasia (HHT). The hemoglobin level determined at the time of catheterization was within the normal range, 16.3 g/dL, with a hematocrit of 48.5%. Endovascular treatment was planned to prevent such serious complications as brain abscess in spite of the absence of clinical symptoms.

The right femoral vein was used to access the pulmonary artery. Left pulmonary arteriography was ob-

<sup>1</sup>Department of Diagnostic Radiology, Bundang CHA General Hospital, College of Medicine, Pochon CHA University

<sup>2</sup>Department of Thoracic & Cardiovascular Surgery, Bundang CHA General Hospital, College of Medicine, Pochon CHA University

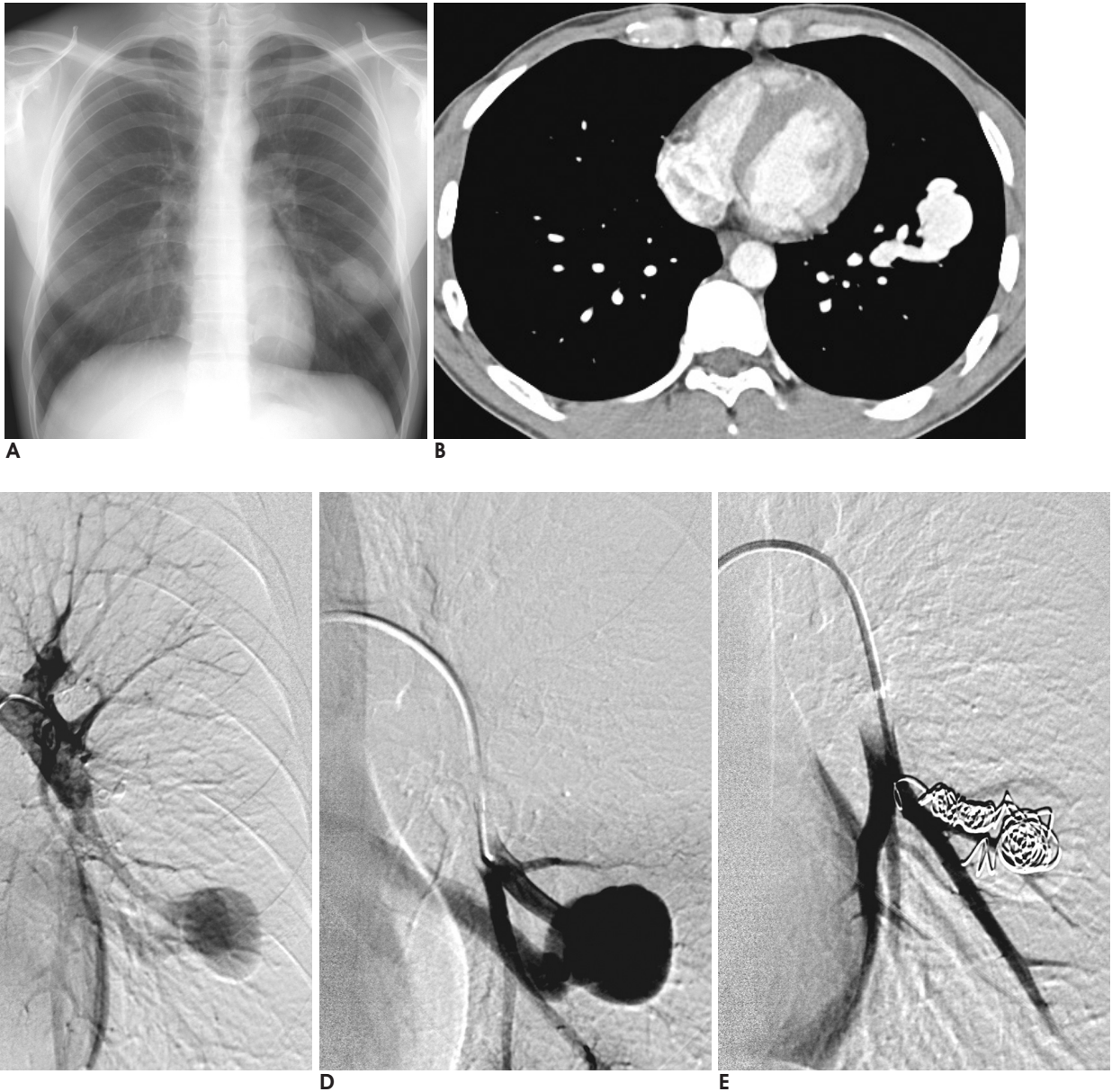
Received June 24, 2003 ; Accepted November 17, 2003

Address reprint requests to : Man Deuk Kim, M.D., Department of Diagnostic Radiology, Bundang CHA General Hospital, College of Medicine, Pochon CHA University, 351 Yatap-dong, Bundang-gu, Sungnam-si, Kyunggi-do 463-070, South Korea.

Tel. 82-31-780-5382 Fax. 82-31-780-5381 E-mail: mdkim@cha.ac.kr

tained with the use of a pigtail catheter (PIG; Cook, Bloomington, IN); it demonstrated the PAVM on the left lower lobe of the lung (Fig. 1C). A 9 French introducer catheter (Vistabritetip, 90 cm in length; Cordis) was advanced into the left anteromedial branch of the pulmonary artery, and the feeding artery was then subselected with use of the inner 5-French catheter (DAV, 100 cm in length; Cook, Bloomington, IN) with the coaxial system (Fig. 1D); embolization of the feeding artery

and the aneurysmal sac was then performed using eight platinum coils (12 mm  $\times$  14 cm, Nester, Cook, Bloomington, IN) until there was complete cessation of blood flow through the PAVM (Fig. 1E). There were no immediate complications from the procedure, and the patient was discharged the next day. On the follow up CT scan one month later, the PAVM was decreased in diameter from 4.2  $\times$  3.2 cm to 3.2  $\times$  2.6 cm without contrast enhancement.



**Fig. 1.** 33-year-old male with a pulmonary arteriovenous malformation (PAVM).

**A.** Chest radiography demonstrates an ovoid, well-defined mass on the left lower lobe.

**B.** CT scan with a mediastinal setting reveals the vascular mass and the draining vein on the anteromedial segment of the left lower lobe.

**C.** Left pulmonary arteriography shows the PAVM on the left lower lobe.

**D.** On selective pulmonary angiography, the PAVM with a large feeding artery and draining vein are shown.

**E.** Immediate postembolization angiogram demonstrates complete occlusion of the PAVM.

## Discussion

The PAVM is an abnormal direct communication between the pulmonary arteries and veins that results in an intrapulmonary right-to-left shunt.

PAVM appears most frequently as a part of HHT (79% to 90%), but it often occurs as an isolated anomaly (5). The patients may be completely asymptomatic or they may manifest progressive hypoxemia that is accompanied by fatigue, dyspnea and cyanosis. Serious complications including hemoptysis and paradoxical embolization leading to stroke and brain abscess account for a 10% mortality rate during the course of the disease (2, 3). The risk of cerebral complication is greater if the PAVM feeding branch is greater than 3 mm in diameter. PAVM might contribute to the development of brain abscess by allowing bacteria easier access to the systemic circulation through a right to left pulmonary vascular shunt, which allow blood to bypass the filtering action of the pulmonary capillaries. It is possible that a thrombus may also form in-situ within a PAVM, and this can dislodge and embolize into the cerebral circulation. The radiological literature currently advocates the occlusion of all such malformations having feeding vessels of 3 mm or greater (5).

PAVMs have been classified as being simple or complex structures. The former consists of a single pulmonary artery with a single draining pulmonary vein communication that is usually bulbous, aneurysmal and non-septated. Complex lesions have multiple feeding arteries and draining veins with a septated aneurysmal sac. Approximately, 80% of PAVMs are found to be of the simple type. CT allows for the accurate measurement of the feeding arteries to the PAVM, and so CT can be useful when planning treatment.

Detachable balloons and metallic coils are the embolotherapy devices that have been most commonly used to treat PAVM. The disadvantages of balloons include the usual need for multiple catheter exchanges, the complexity of their use and the potential risk of an early balloon deflation. An absolute indication for coils has been reported as the presence of feeding arteries greater than 9 mm in diameter. More recently, platinum Nester coils have become available. Platinum coils have several advantages compared with stainless-steel coils (8). The platinum coils are softer and more flexible, which allows tight packing into the feeding artery to form a dense coil "plug". The greater opacity of plat-

inum improved the visualization during fluoroscopy. Platinum coils are also longer than most stainless-steel coils, and this allows more embolic material to be delivered during a single deployment. However, stainless-steel coils are particularly preferred for a short feeding artery or for a feeding artery larger than 12 mm because platinum coils are all 14 cm in length and their maximum diameter is 12 mm.

Complications arising from embolization include self-limited pleuritic chest pain, pulmonary infarction, air embolism and PAVM perforation or dissection. In one study (8), there were no significant differences for complications between patients treated with the stainless steel coil and the platinum coil, except for the self-limited pleuritic chest pain that was more common in the platinum coil group. However, platinum coils make it possible to deliver more embolic material at a single deployment, and this results in shorter procedure times and theoretically decreases the risk of air embolism. Serious complications related to embolization procedures are rare. The coil may pass through the malformation into systemic circulation with potentially disastrous consequences. Several reports have described transient ischemic attacks and strokes occurring during embolization, and the possible reasons for these include the dislodgement of a pre-existing thrombus within the malformation by the catheter tip, migration of a thrombus from the coils during embolization or an inadvertent injection of air through the catheter. Some investigators have experienced persistence of the PAVM following embolization, and this was caused by either recanalization or bronchial artery growth (9, 10). Therefore, long term follow up is mandatory to detect recanalization of an embolized PAVM. We recommend that embolization of a PAVM by using platinum coils is a highly efficacious procedure with a low complication rate.

## References

1. Hewes RC, Auster M, White RI Jr. Cerebral embolism--first manifestation of pulmonary arteriovenous malformation in patients with hereditary hemorrhagic telangiectasia. *Cardiovasc Intervent Radiol* 1985;8:151-155
2. Brydon HL, Akinwunmi J, Selway R, Ul-Haq I. Brain abscesses associated with pulmonary arteriovenous malformations. *Br J Neurosurg* 1999;13:265-269
3. Ference BA, Shannon TM, White RI Jr, Zawin M, Burdge CM. Life-threatening pulmonary hemorrhage with pulmonary arteriovenous malformations and hereditary hemorrhagic telangiectasia. *Chest* 1994;106:1387-1390
4. Remy-Jardin M, Wattinne L, Remy J. Transcatheter occlusion of pulmonary arterial circulation and collateral supply: failures, inci-

dents, and complications. *Radiology* 1991;180:699-705

5. White RI Jr, Lynch-Nyhan A, Terry P, Buescher PC, Farmlett EJ, Charnas L, et al. Pulmonary arteriovenous malformations: techniques and long-term outcome of embolotherapy. *Radiology* 1988;169:663-669

6. Saluja S, Henderson KJ, White RI Jr. Embolotherapy in the bronchial and pulmonary circulations. *Radiol Clin North Am* 2000; 38:425-448

7. Saluja S, Sitko I, Lee DW, Pollak J, White RI Jr. Embolotherapy of pulmonary arteriovenous malformations with detachable balloons: long-term durability and efficacy. *J Vasc Interv Radiol* 1999; 10:883-889

8. Prasad V, Chan RP, Faughnan ME. Embolotherapy of pulmonary arteriovenous malformations: efficacy of platinum versus stainless steel coils. *J Vasc Interv Radiol* 2004;15:153-160

9. Lee DW, White RI Jr, Egglin TK, Pollak JS, Fayad PB, Wirth JA, et al. Embolotherapy of large pulmonary arteriovenous malformations: long-term results. *Ann Thorac Surg* 1997;64:930-939

10. Sagara K, Miyazono N, Inoue H, Ueno K, Nishida H, Nakajo M. Recanalization after coil embolotherapy of pulmonary arteriovenous malformations: study of long-term outcome and mechanism for recanalization. *AJR Am J Roentgenol* 1998;170:727-30

