

Acute Tracheal Obstruction due to Endotracheal Tuberculosis

Division of Pulmonary, Allergy and Critical Care Medicine, Department of Internal Medicine, Kyung Hee University College of Medicine, Seoul, Korea

Ju Woong Son, M.D., Myung Jae Park, M.D.

기관결핵에 의한 급성 기관폐쇄

손주웅, 박명재

경희대학교 의과대학 내과학교실

기관지결핵에 의한 기도폐쇄, 협착은 기관지결핵 치료 초기보다는 치료 도중 또는 치료 후기에 주로 발생하는 합병증이다. 23세 여자환자가 기관지결핵을 진단받고 항결핵제 치료 시작 2주 후 급성으로 악화된 심한 기침, 호흡곤란으로 병원에 왔다. 시행한 기관지내시경에서 용종과 같은 기관지종괴가 기관 내에서 호흡에 따라 상, 하 운동을 하면서 호기 시에 기도폐쇄를 일으켰고 이 종괴는 기관지 내시경을 통해 성공적으로 제거되었다. 기관지결핵의 치료경과 중 발생한 드물게 보이는 형태의 급성 기도폐쇄로 사료되어 문헌고찰과 함께 보고한다. (*Tuberc Respir Dis* 2008;64:206-209)

Key Words: Bronchoscopy, Endotracheal tuberculosis, Tracheal obstruction

Introduction

Endobronchial tuberculosis (EBTB) is a tuberculous infection of the tracheobronchial tree and can be diagnosed by microbial and histopathological examination¹. Endotracheal tuberculosis is a relatively uncommon (about 4%), localized form of EBTB which may cause acute respiratory failure². Early diagnosis and prompt treatment, before the development of fibrotic scarring, is important to prevent tracheobronchial stenosis. But the clinical, radiologic presentation of EBTB is not specific, and early diagnosis of EBTB depends on a high index of physician's suspicion³. We report a case of endotracheal tuberculosis who presented with acute tracheal obstruction early in the course of the disease; this was resolved by bronchoscopic intervention without tracheal stricture.

Case Report

A 23-year-old married woman presented with a two month history of cough, sputum and voice change. She was relatively healthy and had no past medical history of note or drug history. She had never been a smoker. Laboratory findings were normal except the sputum smear was positive for acid-fast bacilli (AFB). A chest radiograph showed no abnormality. She was referred to us because her symptoms continued despite treatment with an anti-tuberculosis drug for two weeks. On physical examination, breathing sound was clear, without wheezing. To rule out the possibility of EBTB, we performed a fiberoptic bronchoscopy. A large caseous mass was found on the right lateral wall of the distal trachea (Figure 1A). A bronchial biopsy revealed caseous necrosis with epithelioid granuloma; a bronchial washing sample showed culture positive for AFB. Prednisolon was additionally prescribed in a dose of 40 mg daily with an anti-tuberculosis drug. Two weeks later, the patient revisited the office with a severe cough and dyspnea which had developed acutely. She complained that something was moving up and down inside her neck but she could not expectorate it. On physical examination, expiratory wheezing was heard on her neck. A pulmonary-function test (PFT) demonstrated that forced

Address for correspondence: **Myung Jae Park, M.D.**
Department of Internal Medicine, Kyung Hee University Hospital, 1, Hoegi-dong, Dongdaemun-gu, Seoul 130-702, Korea
Phone: 82-2-958-8197, Fax: 82-2-968-1848
E-mail: mjpwis@chol.com
Received: Jan, 29, 2008
Accepted: Feb, 11, 2008

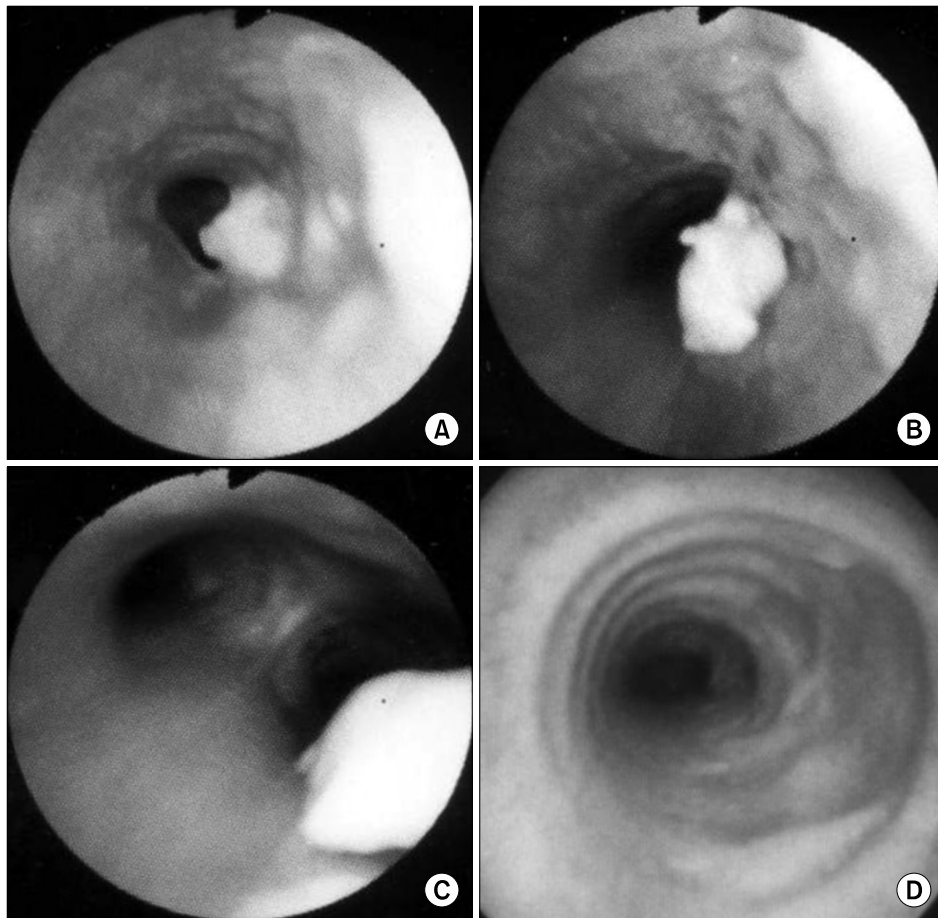


Figure 1. Serial findings of bronchoscopy. The first bronchoscopy (A) shows a caseous protruding mass-like lesion on the right lateral wall of the distal trachea, and the tracheal lumen is narrowed by severe mucosal swelling. Two weeks later, a second bronchoscopy shows up (B) and down (C) movement of a polyplike mass during expiration and inspiration, respectively. Nine months later, a third bronchoscopy (D) shows a crater-like depression on the distal trachea. Several lateral parts of the tracheal cartilage rings have disappeared and the tracheal cartilage rings are clearly visible due to improvement of the mucosal swelling.

expiratory volume in one second (FEV_1) was 0.62 L (predicted 3.44 L) and forced vital capacity (FVC) was 1.75 L (predicted 3.76 L). The flow-volume curve showed the typical pattern of a variable intrathoracic airway obstruction (Figure 2A). A second bronchoscopy showed that the mass was flopping up and down with expiration and inspiration, respectively. During expiration, the mass moved up to mid-trachea level and obstructed the tracheal lumen. Moreover, the mid-tracheal lumen was narrowed with mucosal swelling and positive pleural pressure during expiration (Figure 1B). The mass moved down to the distal trachea (Figure 1C). Mass was re-

moved by biopsy forceps without significant bleeding. Immediately after the removal, the cough and dyspnea dramatically improved. PFT improved remarkably as follows; FEV_1 ; 2.32 L (predicted 3.44 L), FVC; 2.83 L (predicted 3.76 L). The flat expiratory limb of flow volume curve changed to the normal pattern (Figure 2B). The removed mass was round, smooth and had a fibrous tag (Figure 2C). Most portions of the tissue were necrotic, and numerous AFB were noted on microscopic examination (Figure 2D). On the superficial portion of the mass, microscopy revealed septate hyphae with acute angle branching (Figure 2E). The patient was

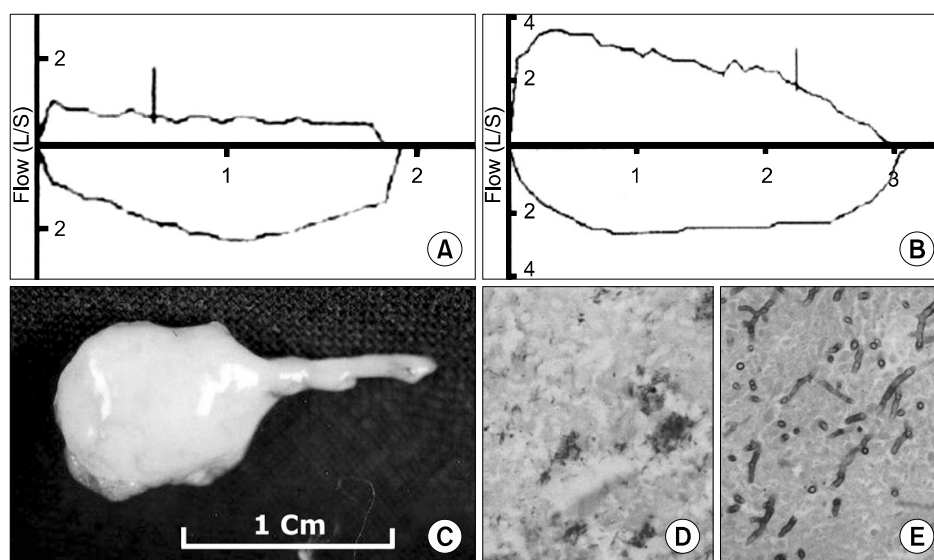


Figure 2. Findings of flow volume curve before (A) and after (B) mass removal. Typical variable intrathoracic airway obstruction is observed (A). After mass removal, a flat expiratory limb of flow volume curve is changed to the normal pattern (B). Gross specimens (C) of removed polypoid mass show AFB (D) in the central portion of the mass and branching hyphae in the surface of the mass (E) (AFB stain, $\times 400$, H&E stain, $\times 400$).

treated with antituberculosis chemotherapy for nine months. Nine months after the treatment, a third bronchoscopy was performed. Symptoms of active EBTB had completely disappeared, but a round crater like depression with the loss of several tracheal cartilage rings was observed on the distal of the trachea (Figure 1D). Two years later, a follow up bronchoscopy revealed no evidence of recurrence or tracheal stricture.

Discussion

EBTB has been reported to develop in 10~40% of patients with active pulmonary TB³. It is a disease of young patients, with more than 50% of cases being observed at less than 35 years of age. Peak incidence of EBTB occurs in the third decade, with a female preponderance⁴. In spite of advances in the diagnosis and management of endobronchial tuberculosis, bronchial stricture still remains a considerable clinical problem^{5,6}. Bronchial stricture can be associated with 60~95% of EBTB patients² but is usually a late and severe complication of EBTB⁴. However, our patient, presented acute upper airway obstruction early in the clinical course,

which is different from the usual clinical course of EBTB. It is difficult to explain how an initial caseous endotracheal mass changed into a polyp-like lesion. One of the possible explanations is that an enlarged tracheal lymph node eroded into the trachea, and fibrous tissue, attached to the mass, acted like a stalk. But the removed polyp-like mass showed necrotic change and did not reveal features of a lymph node. Moreover, the initial chest CT did not show significant enlargement of the paratracheal lymph nodes around the trachea. Even though the mucosal swelling of the trachea was severe on the first two bronchoscopies, tracheal stenosis did not occur. In this case, the tuberculosis infection involved several tracheal cartilages but, fortunately destruction was limited to the lateral part of the tracheal cartilage rings. The bronchoscopy at the ninth month and two years after the treatment showed a crater like depression on the distal trachea with loss of the lateral part of several tracheal cartilages. If the tuberculosis had involved all the tracheal cartilage rings, it would have been problematic due to tracheal stricture. In our previous case report⁷, we observed that even though one-third of several tracheal cartilages had been lost in the endo-

tracheal tuberculosis, significant tracheal stricture did not occur. The remaining two-thirds of the tracheal cartilage rings seemed to be strong enough to support the tracheal lumen opening during the respiratory cycle. The degree of tracheal cartilage involvement would be an important factor in the development of tracheal stricture in patients with endotracheal tuberculosis. Also, we cannot explain why aspergillosis hypae was observed incidentally in the superficial portion of the mass. It may be possible that saprophytic colonization occurred on the surface. The patient showed excellent clinical results without any specific treatment for aspergillosis.

Clinical manifestations of endobronchial tuberculosis include a chronic productive cough, barking cough, hemoptysis, chest pain, general weakness, fever, dyspnea⁴, and expectoration of bronchial cartilage⁷. EBTB can mimic bronchogenic carcinoma⁸, polypoid mass⁹, asthma¹⁰, foreign body aspiration, pneumonia and atelectasis⁴. Such various clinical features are a frequent cause of diagnostic delay. Therefore, a high index of physician's suspicion is important for early diagnosis and effective treatment³. Diagnosis and follow up of EBTB mainly depends on bronchoscopy^{2,8,11}. It has been reported that during the initial three months, the therapeutic outcome of EBTB can be predicted. But it is difficult to predict the outcome of a tumorous type of EBTB because the evolution of lesions during treatment is complicated, and bronchial stenosis develops frequently¹². Our patient, who had tumorous type of EBTB, showed severe symptomatic changes during the first two weeks of treatment. Therefore, it is important to monitor the therapeutic response carefully by observing symptomatic changes and prescribing a follow-up bronchoscopy especially during initial treatment periods.

Summary

Tracheal tuberculosis is a relatively uncommon form

of tuberculosis and can result in acute tracheal obstruction early in the disease course. This is a report of a case of tracheal tuberculosis with unusual clinical presentation.

References

1. Hoheisel G, Chan BK, Chan CH, Chan KS, Teschler H, Costabel U. Endobronchial tuberculosis: diagnostic features and therapeutic outcome. *Respir Med* 1994;88: 593-7.
2. Morrone N, Abe N. Bronchoscopic findings in patients with pulmonary tuberculosis. *J Bronchol* 2007;14:15-8.
3. Ip MS, So SY, Lam WK, Mok CK. Endobronchial tuberculosis revisited. *Chest* 1986;89:727-30.
4. Lee JH, Park SS, Lee DH, Shin DH, Yang SC, Yoo BM. Endobronchial tuberculosis. Clinical and bronchoscopic features in 121 cases. *Chest* 1992;102:990-4.
5. Watanabe Y, Murakami S, Iwa T. Bronchial stricture due to endobronchial tuberculosis. *Thorac Cardiovasc Surg* 1988;36:27-32.
6. Han JK, Im JG, Park JH, Han MC, Kim YW, Shim YS. Bronchial stenosis due to endobronchial tuberculosis: successful treatment with self-expanding metallic stent. *AJR Am J Roentgenol* 1992;159:971-2.
7. Park MJ, Woo IS, Son JW, Lee SJ, Kim DG, Mo EK, et al. Endobronchial tuberculosis with expectoration of tracheal cartilages. *Eur Respir J* 2000;15:800-2.
8. Smith LS, Schillaci RF, Sarlin RF. Endobronchial tuberculosis. Serial fiberoptic bronchoscopy and natural history. *Chest* 1987;91:644-7.
9. Ohno S, Matsuoka R, Mieno T. A case of tracheal tuberculosis showing polypoid proliferation in the trachea (Japanese). *J Jpn Soc Bronchol* 1987;9:254-8.
10. Park CS, Kim KU, Lee SM, Jeong SW, Uh S, Kim HT, et al. Bronchial hyperreactivity in patients with endobronchial tuberculosis. *Respir Med* 1995;89:419-22.
11. Chung HS, Lee JH. Bronchoscopic assessment of the evolution of endobronchial tuberculosis. *Chest* 2000; 117:385-92.
12. Lee JH, Chung HS. Bronchoscopic, radiologic and pulmonary function evaluation of endobronchial tuberculosis. *Respirology* 2000;5:411-7.