

## Operative Treatment for Isolated Distal Ulnar Shaft Fracture

Ho-Jung Kang, Dong-Joon Shim, Seok-Won Yong, Gyu-Hyun Yang, Soo-Bong Hahn,  
and Eung-Shick Kang

*Department of Orthopaedic Surgery, Yonsei University College of Medicine, Seoul, Korea.*

This study retrospectively evaluated the effectiveness of an open reduction and internal fixation of a tension band wiring technique for treating displaced or unstable comminuted distal ulnar shaft fractures without a radial fracture. Ten patients were treated for an isolated distal ulnar shaft fracture. There were 6 cases of a fracture 2.5 cm below the lower end of the ulna, and 4 cases with the fracture being 2.5 cm to 5 cm away from the lower end of the ulna. The authors classified the fractures of the distal ulnar into 3 types: a type I-simple fracture, a type II-comminuted fracture without a distal radioulnar joint (DRUJ) involvement, and a type III-comminuted fracture with DRUJ involvement. There were 3 cases of a type I fracture, 4 of type II and 3 of type III. The open reduction and internal fixation using tension band wiring were performed in 10 of these cases. After the operation, the wrist was placed in a cast for six weeks before active movement was allowed. The clinical results were excellent in 7 cases, good in 2 and poor in 1. In conclusion, tension band wiring surgery is recommended for treating an isolated distal ulnar with unreduced displaced fractures, in a comminuted fracture that cannot be maintained by a closed reduction and when there is the potential encroachment of fracture fragments in the DRUJ.

**Key Words:** Isolated distal ulnar shaft fracture, tension band wiring

### INTRODUCTION

An isolated fracture of the ulnar shaft is a

common injury, which is usually caused by direct trauma. Ulnar shaft fractures have been extensively studied and various treatments such as an open reduction and internal fixation, plaster cast immobilization and a functional brace have been recommended.<sup>1-7</sup> However, there are few reports on fractures within 5 cm of the lower end of the ulna without concomitant fractures of the radius.<sup>8,9</sup> The distal ulna is an important structure in the rotational movement of the wrist, combining its function with the distal radioulnar joint (DRUJ). Displaced or comminuted distal ulnar shaft fractures disrupt the normal anatomy of the DRUJ, interosseous membrane and the triangular fibrocartilage complex. Unless these fractures are managed properly, the functional deformity becomes severe than that observed with ulnar mid-shaft fractures. An isolated distal ulnar shaft fracture should be managed more aggressively and precisely in order to achieve a substantial improvement in the anatomical structures and functional results. However, accurate reduction and maintenance of the fracture in the distal ulnar is difficult because the fracture has a tendency to be comminuted, dorsal ulnar becomes grooved and the distal ulna adopts a curved ridged shape so that anatomically, firm fixation is tricky. The authors newly classified the distal ulnar fracture without a radial fracture, and evaluated the effectiveness of an open reduction and internal fixation with a tension band wiring technique for treating a displaced or comminuted isolated distal ulnar shaft fracture.

Received June 3, 2002

Accepted July 31, 2002

Reprint address: requests to Dr. Ho-Jung Kang, Department of Orthopaedic Surgery, Youngdong Severance Hospital, Yonsei University College of Medicine, P.O. Box 1217, Seoul 135-720, Korea. Tel: 82-2-3497-3412, Fax: 82-2-573-5393, E-Mail: kangho56@yumc.yonsei.ac.kr

## MATERIALS AND METHODS

From May 1991 to April 1997,<sup>10</sup> patients were treated for an isolated distal ulnar shaft fracture without a radius fracture. The patient's age, sex, duration of symptoms and injury mechanism were reviewed from their medical records. All patients with fractures of both bones of the forearm and Galeazzi's or Monteggia's fracture-dislocations were excluded. Moreover, in the distal ulna, only ulnar styloid fractures, and fractures more than 5 cm from the lower end of the ulna were excluded in this study. There were 6 males and 4 females (Table 1). The average age at the time of surgery was 42.4 years (range, 17 to 70 years). The average age of the female patients (59 years) was older than that of the male patients (32 years). The dominant arm was involved in 5 patients. The fractures were the result of a motor vehicle accident in 5 cases, a fall in 3 cases and a direct blow during a fight in 2 cases. The interval from injury to surgery ranged from 6 to 21 days (average 10.8 days).

The location of the fracture, displacement of the bone ends and the comminution were evaluated by the initial X-Ray. The authors classified the

isolated fractures of the distal ulnar into three types: type I- a simple fracture; type II- a comminuted fracture without DRUJ involvement; and type III- a comminuted fracture with DRUJ involvement (Fig. 1). There were 6 fractures < 2.5 cm from the lower end of the ulna and 4 fractures ranging from 2.5 to 5 cm of the lower end of the ulna. Three cases had fractures with more than 15 degrees of angulation and 7 cases had fractures displaced by more than 50%. All cases were included in the new classification. There were 3 cases of a type I, 4 cases with a type II, and 3 with a type III fracture. A closed reduction was initially attempted in all cases, but the results were less

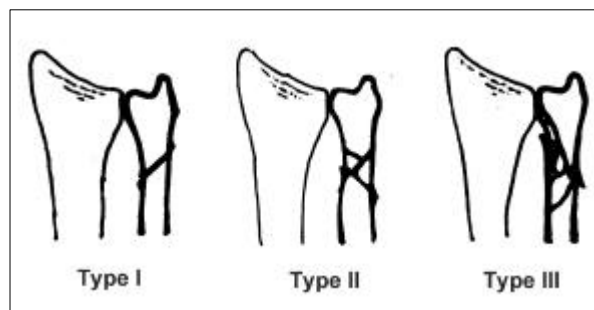


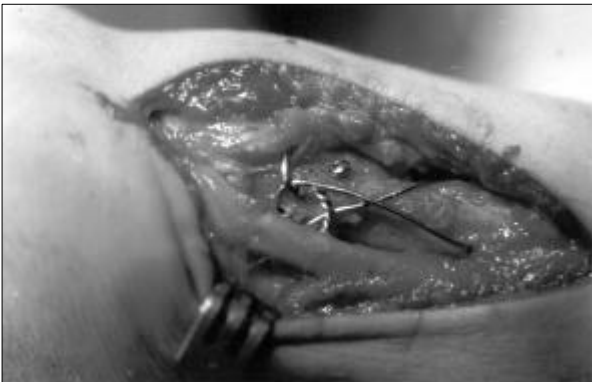Fig 1. Classification of an isolated distal ulnar shaft fracture.

Table 1. Clinical Characteristics of Patients

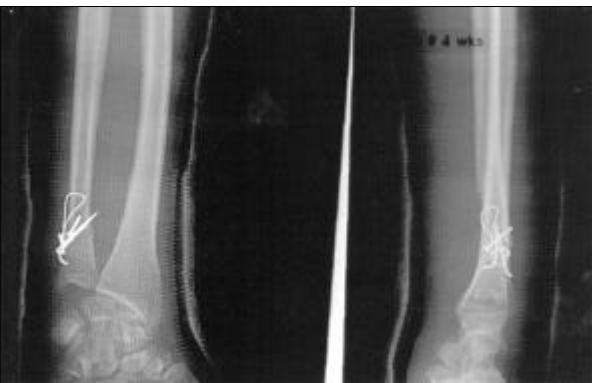Case	Sex / Age	Side	Location (cm)	Type	Injury	Op. Time (Days)	Treatment	Union time (weeks)	Result & Complication
1	F/66	Rt.	4.5	I	Fight	7	T-wire	8	Excellent
2	M/28	Lt.	2.5	I	FI	7	T-wire	8	Excellent
3	M/55	Rt.	2.5	I	MA	21	T-wire	8	Excellent
4	F/70	Lt.	3.5	II	MA	8	T-wire & miniscrew	9	Excellent
5	M/40	Rt.	3	II	MA	13	Double T-wire & T-DRUJ fixation	9	Good & Pinsite irritation
6	F/50	Rt.	1.5	II	MA	7	T-wire & H-screw	11	Excellent
7	M/17	Rt.	3	II	MA	8	Double T-wire	9	Excellent
8	M/18	Lt.	2.5	III	FI	21	T-wire & Circumferential wiring	12	Good & Delayed Union
9	M/31	Rt.	2.5	III	Fight	10	Double T-wire	10	Excellent
10	F/49	Lt.	1.5	III	FI	6	T-wire & T-DRUJ fixation	11	Poor

MA, Motor vehicle accident; FI, Falling injury; T-wire, Tension band wire; H-screw, Herbert's screw; T-DRUJ fixation, Transverse distal radioulnar joint fixation.

than satisfactory. The method of fixation was selected according to the displacement and comminution of the fracture. The tension band wire technique applied to avoid damage to the interosseous membrane, extensive periosteal stripping and DRUJ injury (Fig. 2). The open reduction and internal fixation were performed with the tension band wiring technique with an additional miniscrew or Herbert's screw fixation in 10 cases (Fig. 3). Two cases with a severe comminuted displacement of a type III fracture were treated by additional transverse percutaneous 0.045-inch Kirschner wire pinning in the DRUJ. Three cases were fixed with double tension band wiring. The transverse percutaneous K-wire of the DRUJ was removed 4 weeks after surgery. Cast immobilization of the wrist was done for 6 weeks after surgery before active movement of the wrist was allowed. The clinical and radiological evidence was used to determine whether or not the union



**Fig 2.** Intraoperative finding of minimal periosteal stripping in a distal ulna fracture.



**Fig 3.** Type I distal ulnar fracture treated with tension band wiring.

was successful. A clinical union was defined as a non-tender, non-mobile fracture site to palpation with set range of motion. Radiological union was defined as a bridging of the fracture line by the callus and a progressive obliteration of the fracture line by bony trabeculae. The clinical results were classified as modified from Altner and Hartman<sup>10</sup> including residual pain, bony union and the range of motion of the forearm and wrist. Complete bony union without residual pain and 90% or more of the normal forearm rotation and wrist motion was considered to be excellent. Complete bony union with mild pain and 70-90% of normal forearm rotation and wrist motion was considered good. Incomplete bony union with severe pain and < 70% of normal forearm rotation and wrist motion was considered to be a poor result.

Six weeks of the above-elbow cast immobilization preceded active movement after surgery. After removing the cast, a gentle progressive range of motion exercises were initiated.

All the procedures were performed by the senior author (H-J K). A clinical follow-up was regularly carried out at 2 weeks, 3 months, 6 months, 1 year and every 6 months thereafter. The ability of their handgrip strength and pinch power was assessed using a dynamometer whenever they visited the hospital. The average follow-up interval was 43 months (range, 24 to 82 months). All patients answered a questionnaire about their subjective satisfaction with the surgery, and the clinical outcomes were examined regularly in the outpatient department during the follow-up period. The range of wrist motion and forearm rotation was evaluated.

## RESULTS

The clinical results were excellent in 7 cases, good in 2 and poor in 1. All cases with a type I fracture showed excellent results (Fig. 4). Seventy-five percent of type II fracture cases showed excellent results, and only 33% of type III fracture showed excellent results. All cases except one had a satisfactory union at an average 9.5 weeks (range, 8 to 12 weeks) after surgery. There were no differences between the severity of the com-

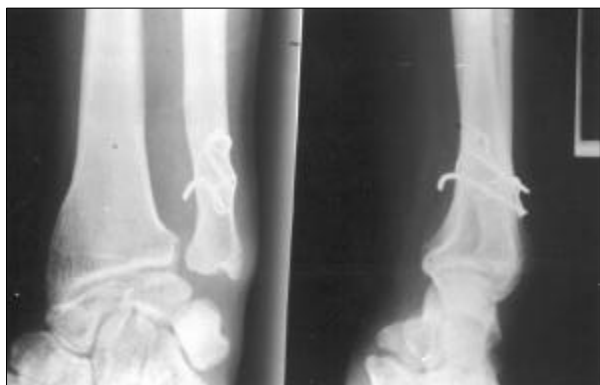

Fig 4. Union state of a Type II isolated distal ulnar shaft fracture 12 months after surgery.

minution and the time to union. Two cases underwent delayed surgery because of concomitant vital injuries such as a hemopneumothorax and a subdural hematoma. However, the delayed procedures had no effect on the union.

The wrist, abduction, adduction, dorsiflexion and plamar flexion were measured. At the forearm, the ranges of supination and pronation were measured. Upon follow up, the average range of motion of the wrist was 60 degrees of extension (range, 30 to 70 degrees) and 67 degrees of flexion (range, 45 to 80 degrees). There were no weaknesses in the grip strength or the pinch power. Two type III patients lost up to 40 degrees of pronation and 25 degrees of supination with an impaired function. There were two complications after surgery. One patient complained of irritating pain at the tension band wiring site during forearm rotation. The pain disappeared after removing the implant at 1 year postoperatively. The other patient showed a delayed union. This patient was treated with double tension band wire fixation. Four months after surgery, there was a hypertrophied delayed union at the fracture site (Fig. 5). However, the fracture was united without any additional immobilization or additional surgery after 12 months.

## DISCUSSION

A fracture of the ulnar shaft is referred to as a nightstick fracture, and usually results from a low-energy injury. Therefore, a displacement of

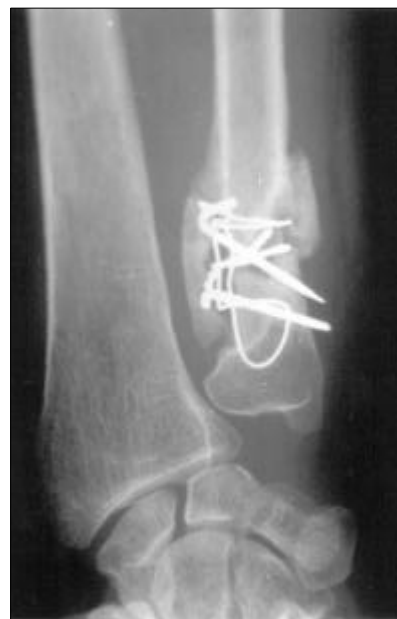

Fig 5. Hypertrophic delayed union noted at a postoperative 4 months X-ray of a type III isolated distal ulnar shaft fracture.

the ulnar shaft is unlikely to be severe because of the intact radius and intrinsic strength of the interosseous membrane. There have been many reports of excellent results with the conservative treatment of isolated ulnar shaft fractures with minimal or no displacement. The majority of isolated fractures of the ulnar shaft can be treated adequately by closed means such as functional braces or above or below the elbow casts.<sup>3,5-7,11,12</sup> However, fractures of the distal ulna shaft are caused by much higher forces such as motor vehicle accidents and falls rather than by fractures of the ulnar shaft. Szabo and Skinner<sup>13</sup> reported that the degree of fracture displacement indicated the level of energy causing the fracture. In this study, 70% of fractures showed severe comminution and more than 50% displacement. Brakenbury et al.<sup>14</sup> reported nonunion in 1.4% of undisplaced isolated ulnar shaft fractures and 20% of fractures were displaced by more than one half the shaft width.

Dymond<sup>4</sup> suggested that the stability of isolated fractures of the distal ulna is dependent on the integrity of the periosteum and the interosseous membrane. The interosseous membrane plays an important role at times when the radius rotates around the distal ulna. The

interosseous membrane not only unites the two forearm bones, but also acts as a restraint to the rotational movement of the DRUJ. The interosseous membrane obliquely attaches the distal ulna to the proximal radius. Fractures with < 50% displacement as assessed by the initial X-ray are considered to have an intact interosseous membrane.<sup>15</sup> If this type fracture is displaced by > 50% of their diameter in any plane, they become unstable with the interosseous membrane and periosteum disruption. Experimental studies by Hotchkiss et al.<sup>16</sup> revealed that an incision of the central interosseous band reduced the stability by 71% of the longitudinal stiffness of the interosseous membrane after a radial head excision. The contribution of the triangular fibrocartilage complex was 8%. In this study, no special study on a triangular fibrocartilage complex injury was done. There is the possibility of a combined injury to the central interosseous membrane and triangular fibrocartilage complex, even in displaced or comminuted distal ulnar shaft fractures. To achieve a satisfactory result, a distal ulna fracture needs an anatomical reduction, as well as a correction of the displacement, and the restoration of the normal length, axial alignment and rotational alignment.

To treat an ulnar shaft fracture, Corea et al.<sup>2</sup> recommended an open reduction and internal fixation for proximal third ulnar shaft fractures, fractures displaced by more than one-quarter of the ulnar shaft diameter and fractures angulated by more than 15°. Sarmiento et al.<sup>17</sup> experienced a median loss of pronation-supination after treating fractures in the distal third of the ulna, which was more than in the middle third of the ulna, with a functional brace. Brakenbury et al.<sup>14</sup> noted an increased nonunion rate in the fractures located at the distal third of the ulna, where the circulation may be compromised due to the lack of muscle coverage and termination of the nutrient artery proximal to this site. However, the distal ulna is an important component in the forearm and wrist motion. Pronation-supination is a complex movement, combining the rotation of the radius around the ulna with a horizontal and axial translation. If the distal ulna fails to heal in the proper anatomical position maintaining its

original length with significant residual angulation at the fracture site, and separation of the DRUJ in a transverse axis, then a more severe limitation of forearm motion than that experienced with shaft fractures may result. Although other techniques have been advocated, obtaining and maintaining an accurate reduction usually necessitates an open reduction and internal fixation. In ulnar shaft fractures, plates are preferred to intramedullary rods because they provide more secure fixation. A plate controls the rotation of the fracture site better and leads to a lower nonunion rate than most intramedullary devices. However, plate fixation requires some degree of soft-tissue dissection at the fracture site. In addition, there is insufficient space to place the plate, particularly around the narrow and curved shape of the distal ulnar area. In particular, in the dorsum of the ulnar, the ulnar groove for the extensor carpi ulnaris and the protruded ulnar styloid process are the main obstacles in plating. The authors either used a tension band and miniscrews or Herbert's screw fixation technique with satisfactory results. Less surgical injury to the periosteum and surrounding tendons can be achieved with a tension band and transverse DRUJ pinning technique.

In this study, a gentle progressive range of motion exercises was initiated after 6 weeks of cast immobilization. Several reports in the length of immobilization in conservative treatment of ulnar shaft fractures have ranged from 1 week to 8 weeks.<sup>5,7,11</sup> Many authors have reported good results with various treatments, with an average healing time from 7 to 9.9 weeks.<sup>1,5,10,17</sup> In this study, all cases obtained union at an average of 9.5 weeks (range, 8 to 12 weeks) after surgery.

We classified the isolated distal ulnar fracture and recommend surgery in unreduced fractures with a > 50% displacement, a > 15 degrees of angulation in any plane and in a comminuted fracture, which could not be maintained by a closed reduction. In conclusion, the authors recommend tension band wiring surgery for the isolated distal ulnar in an unreduced displaced fracture and in a comminuted fracture that cannot be maintained by a closed reduction and there is the potential encroachment of fracture fragments in the DRUJ.

## REFERENCES

1. Anderson LD, Sisk TD, Tooms RE, Park III WI. Compression plate fixation in acute diaphyseal fractures of the radius and ulna. *J Bone Joint Surg Am* 1975;57A:287-96.
2. Corea JR, Brakenbury PH, Blakemore ME. The treatment of isolated fractures of the ulnar shaft in adults. *Injury* 1981;12:365-70.
3. De Boeck H, Haentjens P, Handelberg F, Casteleyn PP, Opdecam P. Treatment of isolated distal ulna shaft fractures with below-elbow plaster cast. A prospective study. *Acta Orthop Trauma Surg* 1996;115:316-20.
4. Dymond IW. The treatment of isolated fracture of the distal ulna. *J Bone Joint Surg Br* 1984;66B:408-10.
5. Ekelund AL, Nilsson OS. Early mobilization of isolated ulnar-shaft fractures. *Acta Orthop Scand* 1989;60:261-2.
6. Gebuhr P, Holmich P, Orsnes T, Soelberg M, Krashennikoff M, Kjersgaard AG. Isolated ulnar shaft fractures. Comparison of treatment by a functional brace and long-arm cast. *J Bone Joint Surg Br* 1992;74B:757-9.
7. Goel SC, Raj KB, Srivastava TP. Isolated fractures of the ulnar shaft. *Injury* 1991;22:212-4.
8. Biyani A, Simison AJM, Klenerman L. Fractures of the distal radius and ulna. *J Hand Surg Br* 1995;20B:357-64.
9. Du Toit FP, Grabe RP. Isolated fractures of the shaft of the ulna. *S Afr Med J* 1979;56:21-5.
10. Altner PC, Hartman JT. Isolated fractures of the ulnar shaft in adult. *Surg Clin North Am* 1972;52:155-70.
11. Pollock FH, Pankovich AM, Prieto JJ, Lorenz M. The isolated fracture of the ulnar shaft. *J Bone Joint Surg Am* 1983;65A:339-42.
12. Zych GA, Latta LL, Zagorski JB. Treatment of isolated ulna shaft fractures with prefabricated functional fracture braces. *Clin Orthop* 1987;219:194-200.
13. Szabo RM, Skinner M. Isolated ulnar shaft fractures. Retrospective study of 46 cases. *Acta Orthop Scand* 1990;61:350-2.
14. Brakenbury PH, Corea JR, Blakemore ME. Non-union of the isolated fracture of the ulnar shaft in adults. *Injury* 1981;12:371-5.
15. Muellner T, Fuchs M, Kwasny O. Rational instability and integrity of the interosseous membrane in cadaveric ulnar shaft fractures. *Acta Orthop Trauma Surg* 1998;118:53-6.
16. Hotchkiss RH, An K, Sowa DT, Basta S, Weiland AJ. An anatomic and mechanical study of the interosseous membrane of the forearm: Pathomechanics of proximal migration of the radius. *J Hand Surg Am* 1989;14A:256-61.
17. Sarmiento A, Kinman PB, Murphy RB, Phillips JG. Treatment of ulnar fractures by functional bracing. *J Bone Joint Surg Am* 1976;58A:1104-7.