

Anatomic Motor Point Localization for the Treatment of Gastrocnemius Muscle Spasticity

Woo Kyoung Yoo¹, In Hyuk Chung², and Chang Il Park³

¹Department of Physical Medicine & Rehabilitation, Hallym University College of Medicine, Anyang, Korea;

²Department of Anatomy and Brain Korea 21 Project for Medical Science, Yonsei University College of Medicine, Seoul, Korea;

³Department of Physical Medicine & Rehabilitation, Yonsei University College of Medicine, Seoul, Korea.

The location of the motor point of the gastrocnemius muscle was accurately defined relative to surrounding bony landmarks to facilitate the approach to the nerve of the gastrocnemius muscle during treatment for gastrocnemius muscle spasticity. Anatomic dissection of 40 cadaver knees was undertaken for morphometric measurement. The distances from the epicondyle of the femur to the motor branch, and from the motor branch to the motor point of the nerve to the medial head of the gastrocnemius muscle were 3.68 ± 11.44 mm, and 37.79 ± 7.80 mm, respectively; while those of the nerve to lateral head of the gastrocnemius muscle were 4.45 ± 11.96 mm, and 32.16 ± 4.64 mm, respectively. The tibial nerve lay $44.57 \pm 5.45\%$ and $56.30 \pm 4.73\%$ from the lateral margins of the epicondyle and the fibular head, respectively. Careful consideration of the morphometry of the motor point of the gastrocnemius muscle may provide accurate anatomical guidance, and hence reduce complications during the chemical blockage of these nerves.

Key Words: Motor point, motor branch, gastrocnemius muscle, morphometry

INTRODUCTION

Spasticity is a manifestation in many central nervous system disorders, including cerebral palsy. Such spasticity requires adequate treatment because the increased muscle tone inhibits vertical growth of muscle leading to permanent contraction and disability.¹ Spasticity of the ankle plantar

flexor and of the foot invertor are frequently seen in patient with central nervous system disorders and are often disabling.² In neurotomy, which is one of the different treatment methods available for spasticity, it is important to know the exact location and locational variations of the tibial nerve. Another treatment method involves chemical neurolysis of the tibial nerve in the popliteal fossa, which is filled with fat that blocks the diffusion of analgesic agents; moreover, precise insertion of the needle into the tibial nerve leads to better results.³ Therefore, the precise localization of the tibial nerve is an important aspect of making an effective injection into the popliteal fossa. Recently, the injection of botulinum toxin, or phenol have been used to reduce spasticity. The effectiveness of this method depends on the location of the injection, in this case with respect to the motor point.⁴ Therefore, the precise anatomical localization of the motor point in the surface may be of significant clinical importance.

Previous anatomic investigations have not provided a description of the motor branch or of the motor point distribution to the gastrocnemius muscle.^{5,6} Therefore, there are relatively few descriptions concerning the motor point location before it enters the gastrocnemius muscle.⁷ To our knowledge, no detailed description is available in the literature of the locations of the motor branch and motor point to the gastrocnemius muscle, and correlations with tibial nerve localizations with respect to surface anatomy are rare. Here, we describe the morphometry of the nerve up to the gastrocnemius muscle and of the surface landmarks of the motor point of the gastrocnemius

Received November 21, 2001

Accepted July 27, 2002

Reprint address: requests to Dr. Woo Kyoung Yoo, Department of Physical Medicine & Rehabilitation, Hallym University College of Medicine, 896, Pyungchon-Dong, Dongahn-Gu, Anyang 431-070, Korea. Tel: 82-31-380-3860, Fax: 82-31-380-3864, E-mail: mdwooky@nate.com

muscle to facilitate the approach to the nerve of the gastrocnemius muscle during treatment for gastrocnemius muscle spasticity.

MATERIALS AND METHODS

Forty knee specimens were dissected for morphometric measurements. The popliteal fossa was exposed in the prone position with the hip, femur, and knee in the anatomic position, and the fat was carefully removed. The tibial nerve was identified and the branch to the gastrocnemius muscle dissected. The fixed point for measurement was the medial and lateral epicondyle of the femur. The motor branch of the gastrocnemius muscle was defined as the point where the branching nerve left the perineurium of the tibial nerve⁵ and the motor point was defined as the point where the motor branch entered the muscle belly.⁵

We measured the vertical distances from the line connecting the two epicondyles (medial and lateral) of the femur to the motor branch and the motor point. The angle of the tibial nerve was measured with reference to the vertical line connecting both epicondyles of the femur, and the angle of the motor branch was measured with reference to the tibial nerve. For describing the medio-lateral spatial relationship of the tibial nerve, the distance between the tibial nerve and the lateral epicondyle at the level of the epicondyle and the fibular head was measured and

described as a percentage fraction of the total medio-lateral distance.

RESULTS

The nerve to the medial head of the gastrocnemius muscle in the popliteal fossa was measured initially. The distances from the epicondyle of the femur to the motor branch and from the motor branch to the motor point were 3.68 ± 11.44 mm, and 37.79 ± 7.80 mm, respectively. In 9 of the 40 cases, the nerves to the medial head of the gastrocnemius muscle were divided from the tibial nerve proximal to the epicondyle of the femur. As for the nerve to the lateral head of the gastrocnemius muscle, distances from the epicondyle of the femur to the motor branch and from the motor branch to the motor point were 4.45 ± 11.96 mm, and 32.16 ± 4.64 mm, respectively. In 7 of the 40 cases, the nerves to the lateral head of the gastrocnemius muscle were divided from the tibial nerve proximal to the epicondyle of the femur. The points of division of the medial sural cutaneous nerve and of the nerve to the soleus muscle were measured from the epicondyle of the femur. The medial sural cutaneous nerve divided 1.99 ± 11.92 mm superiorly to the epicondyle of the femur while the nerve to the soleus muscle divided 24.22 ± 14.41 mm inferiorly to the epicondyle of the femur (Fig. 1).

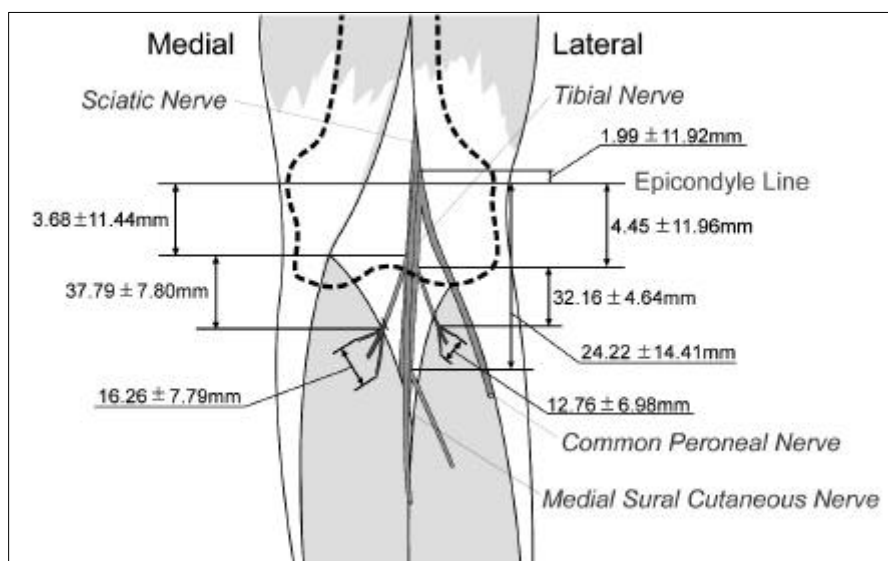


Fig. 1. The distances from the epicondyle of the femur to the motor branch and from the motor branch to the motor point of the nerve to the gastrocnemius muscle.

The average number of small branches to the medial head of the gastrocnemius muscle was 2.51 ± 0.77 at the motor point, and for the lateral head this was 2.39 ± 0.75 . The distances between the proximal and distal motor points in the medial head and in the lateral head were 16.26 ± 7.79 mm, and 12.76 ± 6.98 mm, respectively (Fig. 1).

We measured the angle between the tibial nerve to the vertical line connecting the bilateral epicondyle of the femur, to identify the course of the tibial nerve. The caudal direction of the tibial nerve coursed $8.59 \pm 3.58^\circ$ medially. Angles made by the tibial nerve and the nerves to the each of medial and lateral heads of the gastrocnemius muscles were $8.85 \pm 3.15^\circ$, and $9.58 \pm 2.55^\circ$, respectively (Fig. 2).

The location of the tibial nerve at the level of the epicondyle and the fibular head was described as a percentage fraction of the total medio-lateral distance. The tibial nerve laid $44.57 \pm 5.45\%$ and $56.30 \pm 4.73\%$ from the lateral margin at the epicondyle and the fibular head, respectively.

DISCUSSION

The tibial nerve courses the medial to the lateral margin behind the popliteal artery in the same direction as the sciatic nerve.^{3,6} The branches of the tibial nerve at the popliteal fossa are:- the medial sural cutaneous nerve,⁸ the nerve to the medial head of the gastrocnemius muscle, the nerve to the lateral head of the gastrocnemius muscle, and the nerve to the soleus muscle. Few published descriptions are available about the

morphometry of motor points, although each nerves has been mentioned individually in many articles.

The course of the tibial nerve has been frequently described.⁹ However, in contrast to the quantity of research on the intramuscular distribution of the nerve to the muscle,^{7,10,11} only a few descriptions have been published on its location before entering the gastrocnemius muscle. In addition, reports of its relationship with surrounding anatomical landmarks are scarce. In the present study, we determined the surface landmarks that may be used to localize the tibial nerve in the popliteal fossa. The tibial nerve lay $44.57 \pm 5.45\%$ and $56.30 \pm 4.73\%$ of the way between the lateral margin of the epicondyle and the fibular head, respectively. Rorie et al.³ described the tibial nerve as coursing 0.5-1.0 cm medial to the center of the popliteal fossa, but only indicated the point where the tibial nerve traverses at the popliteal fossa and provided a limited description of the general course of the nerve. In the present study, a line drawn according to percentage fraction between the tibial nerves at the epicondyle of the femur and the fibular head was used to provide a general description of the course of the tibial nerve.

We measured the distance from the epicondyle of the femur to localize precisely the motor point of the gastrocnemius muscle and the motor branches of the tibial nerve. As described previously, the results showed that the nerve to the gastrocnemius muscle divided 4mm distally from the epicondyle of the femur with a radius of 1cm. Schultz et al.⁷ reported that the nerve to the medial head of the gastrocnemius muscle was 5-7 cm in length and that the nerve to the lateral head of the gastrocnemius muscle divided 2-4 cm from the motor point, and was then further divided into nerves to the lateral head of the gastrocnemius muscle and the soleus muscle. In the study of Schultz et al. the nerve to the lateral head of the gastrocnemius muscle divided from the tibial nerve 1-2 cm distal to the nerve to the medial head of the gastrocnemius muscle, whereas in the present study, the medial and lateral branches were found to originate closely. They pierce the gastrocnemius muscle within 3 or 4 cm of the motor branch (Fig. 1). At the motor point,

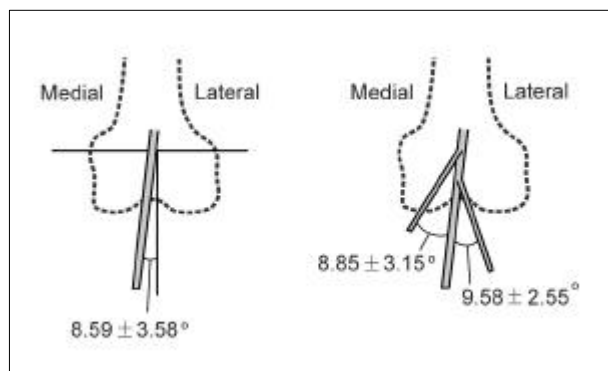


Fig. 2. The angles related to the course of the tibial nerve and its branches.

the average distances between the proximal and distal portions of the medial and lateral sides of motor points were 16 mm, and 13 mm, respectively. Therefore, the motor point was localized within a radius of 2 cm. Segal et al.¹⁰ described two main trunks of the nerve to the lateral head of the gastrocnemius muscle, these trunks were found to innervate three portions of the muscle. However, these workers did not describe the exact location of the motor point.

We conclude that, careful consideration should be paid to the morphometry of the motor point of the gastrocnemius muscle, which may provide accurate anatomical guidance, and hence reduce complications during the chemical blockage of these nerves.

REFERENCES

1. Ziv I, Blackburn N, Rang M, Koreska J. Muscle growth in normal and spastic mice. *Dev Med Child Neurol* 1984;26:94-99.
2. Doute DA, Sponseller PD, Tolo VT, Atkins E, Silberstein CE. Soleus neurectomy for dynamic ankle equinus in children with cerebral palsy. *Am J Orthop* 1997;26:613-6.
3. Rorie DK, Byer DE, Nelson DO, Sittipong R, Johnson KA. Assessment of block of the sciatic nerve in the popliteal foss. *Anesth Analg* 1980;59:371-6.
4. Shaari CM, Sanders I. Quantifying how location and dose of botulinum toxin injections affect muscle paralysis. *Muscle Nerve* 1993;16:964-9.
5. Seidel PM, Seidel GK, Gans BM, Dijkers M. Precise Localization of the Motor Nerve Branches to the Hamstring Muscles: An Aid to the Conduct of Neurolytic Procedures. *Arch Phys Med Rehabil* 1996;77:1157-60.
6. Albert T, Yelnik A, Colle F, Bonan I, Lassau JP. Anatomic Motor Point Localization for Partial Quadriceps Block in Spasticity. *Arch Phys Med Rehabil* 2000;81:285-7.
7. Schultz Von M, Schumacher GH, Ehler E, Himstedt HW, Menning A. Zur Topographie der muskulaeren Nervenausbreitungen. *Anat Anz* 1973;133:248-57.
8. Ortiguera ME, Wood MB, Cahill DR. Anatomy of the sural nerve complex. *J Hand Surg* 1987;12A:1119-23.
9. Podore PC. Popliteal entrapment syndrome: a report of tibial nerve entrapment. *J Vasc Surg* 1985;2:335-6.
10. Segal RL, Wolf SL, DeCamp MJ, Chopp MT, English AW. Anatomical partitioning of three multiarticular human muscles. *Acta Anat* 1991;142:261-6.
11. Sekiya S. Muscle architecture and intramuscular distribution of nerves in the human soleus muscle. *Acta Anat* 1991;140:213-23.