

Tc-99m-ECD SPECT Brain Imaging in Children with Tourette's Syndrome

Rasim Somer Diler¹, Mehmet Reyhanli², Fevziye Toros³, Mustafa Kibar⁴, and Ayse Avci⁵

^{1,3,5}*Dr.s at Child and Adolescent Psychiatry Department, Cukurova University Faculty of Medicine, Adana, Turkey;*

^{2,4}*Dr.s at Nuclear Medicine Department, Cukurova University Faculty of Medicine, Adana, Turkey.*

We undertook this study to assess the patterns of regional cerebral perfusion (RCP) with SPECT using Technetium-99m-ethyl cysteinate dimer (Tc-99m-ECD) in children with Tourette's Syndrome (TS), and to compare these with the patterns in a group of normal controls. The study sample consisted of 38 children (7 to 14 years) who met the ICD-10 and DSM/IV criteria for Tourette's Syndrome, and a control group of 18 children (9 to 14 years). The Children's Depression Inventory and Maudsley Obsessional-Compulsive Questionnaire were used for assessment, and the severity of motor and vocal tics were assessed using the Goetz Rating Scale. The RCP values were significantly lower in the TS group in left caudate, cingulum, right cerebellum, left dorsolateral prefrontal, and the left orbital frontal region. A positive correlation was found between the severity of vocal tics and blood flow of mid-cerebellum, right dorsolateral prefrontal and left dorsolateral prefrontal regions. Although no depressive or obsessive patients were included in the study, the depression and obsession scores were found to be negatively correlated with all RCP values, especially in the temporal regions. Further studies are needed to explore the relationship between the hypoperfusion of certain brain areas and the underlying neurophysiology and neurobiology of patients with TS. Additional disturbances such as obsessive-compulsive symptoms and depressive symptoms should also be assessed.

Key Words: Tourette's syndrome, SPECT, Tc-99m-ECD

INTRODUCTION

Tourette's syndrome (TS) is a common hereditary neuropsychiatric disorder consisting of motor

and vocal tics.^{1,2} The age of onset ranges from 2 to 15 years, with a mean of 7 years. The most frequent symptoms initially involve the eyes (e.g. eye-blinking), but patients usually demonstrate various complicated motor movements including touching, licking, jumping, smelling, spitting, squatting, hitting, abnormalities of gait, and forced touching.³ The onset of vocal tics usually occurs later than that of motor tics, with a mean age of onset of 11 years.⁴ While some clinical features such as coprophenomena, echophenomena and palilali are not essential for diagnosis, the presence of any of these behaviours increases diagnostic confidence.^{3,5}

The prevalence of TS is about 0.5 per 1000.⁶ Although the basal ganglia and possibly the limbic areas are considered to be important in the pathophysiology of TS, structural imaging studies did not reveal significant differences between patients and the general population in these areas.⁷ Therefore, functional imaging studies such as positron emission tomography (PET) and single photon emission tomography (SPECT) may provide more useful information. In PET and SPECT studies, decreased metabolic activity and perfusion have been observed in the basal ganglia in TS.^{8,9} Given that pharmacotherapy with small dosages of neuroleptics successfully improve symptoms in many TS patients, it would appear that the dopaminergic system may be involved in its pathogenesis.¹⁰ PET studies of the dopamine receptor in TS indicates that D2 dopamine receptor density may be elevated in some patients.¹¹

Technetium-99m-hexamethylpropyleneamineoxime (Tc-99m-HMPAO), which has been used as a pharmacologic agent in SPECT, has some impor-

Received October 31, 2001

Accepted March 14, 2002

Reprint address: requests to Dr. Rasim Somer Diler, Child Psychiatry Department, Cukurova University Faculty of Medicine, Balcali, Adana, Turkey. Tel: 90-322-3386875, Fax: 90-322-3386875, E-mail: dilerr@s@yahoo.com

tant properties such as a very rapid brain uptake, and high *in vivo* stability in brain tissue, with no major redistribution. However, Tc-99m-HMPAO has low *in vitro* stability (ca. 30 min).^{12,13} Technetium-99m-ethyl cysteinate dimer (Tc-99m-ECD) is a new cerebral blood flow imaging agent.¹⁴ ECD has some advantages, which include high radiochemical stability (approximately 8 hours), low brain washout, and rapid washout from extra cerebral tissue.^{15,16} Some studies have also suggested that Tc-99m-ECD images are of better quality than Tc-99m-HMPAO images.^{15,17} To our knowledge, the quantitation of brain perfusion using Tc-99m-ECD SPECT in children with TS has not yet been performed. In current study, we wished to determine if there were any significant differences in the patterns of regional cerebral perfusion in patients with TS using Tc-99m-ECD SPECT versus normal controls.

MATERIALS AND METHODS

Patients

The study sample consisted of 38 right-handed children (8 girls and 30 boys) who met both ICD-10 and DSM/IV criteria for Tourette's Syndrome.^{18,19} Their ages ranged from 7 to 14 years (mean \pm standard deviation age; 10.9 ± 2.4 years). All were outpatients at the Child and Adolescent Psychiatry Department, Cukurova University Faculty of Medicine (CUTF), Turkey. Mental retardation developmental impairment, mood disorders (depression and mania), and anxiety disorders were excluded. Eighteen right-handed children (4 girls and 14 boys), with ages ranging from 9 to 14 years (mean \pm standard deviation age; 11.5 ± 1.6 years) were chosen as a control group, from the outpatients of the Child Nephrology Department, CUTF. The absence of psychiatric and systemic illness in the controls was determined by psychiatric interviews and laboratory studies. No control subjects had a family history of psychiatric illness. Approval for the study was received from the ethical committee of the CUTF and informed consents were received from the families of patients and the controls individually.

Measurements

Tic severity at the time of the SPECT was rated using a scale described by Goetz et al.²⁰ Briefly, the involvement of each of the following 11 body areas was monitored to assess motor tic distribution: eyes, nose, mouth, neck, shoulders, arms, hands, trunk, pelvis, legs, and feet. The frequency score consisted of the number of discrete motor tics or vocalizations counted during each segment. Severity was determined on a 0 to 5 scale for motor tics and vocalizations, and the most severe tic was also noted.

A physical examination, urine analysis, and blood chemistry were performed on each subject. All patients were drug free for at least 4 weeks before the study.

Children's Depression Inventory (CDI)

The CDI is a self report depression scale modeled after the Adult Beck Depression Inventory. 27 multiple choice items assess the severity of depressive symptoms over the previous 2 weeks. The scale is widely used, and it has demonstrated good concurrent validity and reliability in Turkey.²¹

Maudsley Obsessional-Compulsive Questionnaire (MOCQ)

The Turkish version of the Maudsley Obsessional-Compulsive Questionnaire is widely used and has been shown to have good concurrent validity and reliability in Turkey.²²

Demographic Questionnaire

67 demographic questions were used routinely to assess for all outpatients of the child psychiatry department, CUTF.

Imaging protocol and evaluation

Technetium-99m-ECD (Neurolite, Du Pont Pharma) was prepared according to the manufacturer's instructions. Briefly, 2 ml of TcO_4^- (3.7 GBq) were added to the buffer vial and then 1 ml of reconstituted lyophilized ligand was added and the mixture allowed to stand for 30 min. The radiopharmaceutical injection was performed 0.5-3 hours after preparation. Thin-layer chroma-

tography was used to control the radiochemical purity, and the radiopharmaceutical was used if its purity was $\geq 95\%$.

The average intravenously administered dose used was 370 - 550 MBq. Patients were rested, and had their eyes open and ears unplugged. All patients were able to tolerate the time of image acquisition without disruptive tics. Acquisition was started 30-60 min after tracer injection. Tomographic planar data was collected on a large field-of-view gamma camera (Starcam 4000i, GE Medical Systems) fitted with a low energy, high-resolution parallel-hole collimator. A circular orbit was employed to acquire 64 planar images over 360° at 30 sec per frame on a 64×64 matrix. Scatter correction and back projection were performed using a Butterworth and Ramp filter. The patient's heads were aligned parallel to the orbitomeatal (OM) line using a head holder. Coronal, sagittal and transaxial slices parallel to the orbitomeatal line were generated. All slices were two pixels thick, and each slice was on average 12.6 mm thick.

All images were reconstructed and analysed by the same physician on the Starcam 4000i computer system. The images of fifteen brain regions were analysed using a region of interest (ROI) method, which was similarly to a described previously method (Fig. 1).⁵ Regular box ROIs (4×4 pixels) were placed manually in 15 regions. Because of the reliability of the measurements, we chose the visual cortex as a reference region. Because the absolute uptake of Tc-99m-ECD images varied among the subjects, each subject's uptake value was normalized to the area of maximal visual cortex uptake prior to performing intersubject

comparisons. This region is also unlikely to be involved in the pathophysiology of TS.⁵

Excluding the visual cortex region, all of the 14 ROIs were expressed as intra-subject ratios relative to the visual cortex (Table 1). The physician responsible for analyzing the images was unaware of any specific clinical details about the patients.

In addition, a set of ROIs was used to define the right and left head of the caudate nucleus, the putamen, and the thalamus in the slices in which they were best visualized. Pixel values in each region were averaged to yield a single uptake value.

Data were analyzed using the Statistical Package for the Social Sciences for Windows 9.0 (SPSS). The 2-tailed t-test was used to determine differences between the TS patients and the controls. Pearson's correlation coefficients (r values) were calculated for each region and tic severity, tic frequency, and CDI and MOCQ scores. Finally, we examined the TS patient group for any differences with respect to coprolalia.

RESULTS

No statistical demographic differences were found between the TS group and the control group, and no children were diagnosed with obsessive-compulsive disorder or depressive disorder. The CDI (depression) and MOCQ (obsession) scores showed no statistical differences between the two groups, and no regional cerebral perfusion (RCP) differences were found in the TS or control group between males and females.

Regional blood flow in all 14 areas in patients

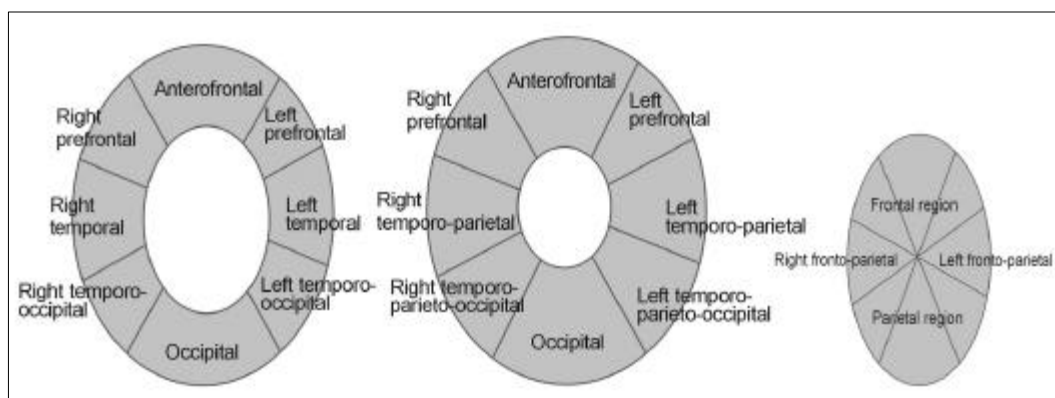


Fig. 1. The cerebral regions of interest drawn on the transaxial slices.

Table 1. Comparison of Mean Values and Standard Deviations between the TS Group and the Control Group in Each of the 14 Regions Expressed as Ratios of the Visual Cortex

Regions	TS	sd	Controls	Sd	t-value	p ^a
Right caudate	0.75	0.06	0.78	0.01	-1.84	0.08
Left caudate	0.73	0.05	0.78	0.01	-4.26	0.000 [†]
Cingulum	0.74	0.05	0.8	0.01	-5.16	0.000 [†]
Right cerebellum	0.85	0.1	0.91	0.01	-2.38	0.03*
Left cerebellum	0.87	0.09	0.9	0.01	-1.58	0.131
Midline cerebellum	0.88	0.1	0.89	0.01	-0.45	0.657
Right dorsolateral prefrontal	0.74	0.08	0.75	0.02	-0.71	0.487
Left dorsolateral prefrontal	0.72	0.06	0.78	0.01	-4.2	0.000 [†]
Right orbital frontal	0.73	0.06	0.74	0	-1.02	0.322
Left orbital frontal	0.74	0.05	0.79	0	-4.05	0.001 [†]
Right anterior medial temporal	0.73	0.01	0.73	0	0.2	0.84
Left anterior medial temporal	0.73	0.07	0.72	0.01	0.37	0.718
Right posterior medial temporal	0.74	0.07	0.73	0	1	0.332
Left posterior medial temporal	0.74	0.06	0.74	0	0.41	0.684

^atwo tailed t-test; TS, Patient group with Tourette's; Controls, Control group; sd, standard deviation.

*= $p < 0.05$, [†]= $p \leq 0.001$, [‡]= $p < 0.0001$.

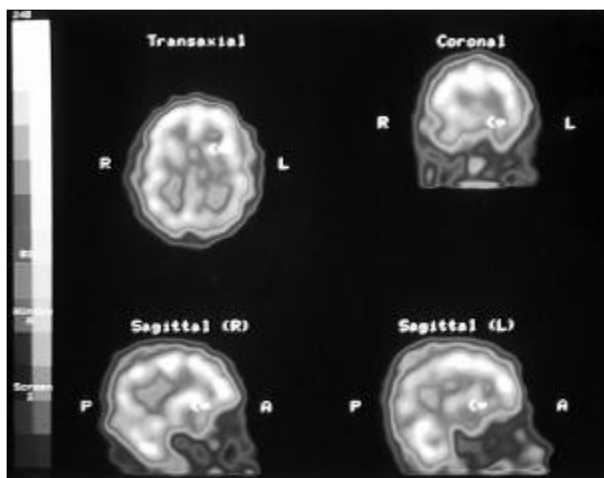


Fig. 2. Abnormal left caudate findings in a 9-year-old boy with Tourette's Syndrome, as shown by transaxial, sagittal, and coronal images. R, right; L, left; A, anterior; P, posterior.

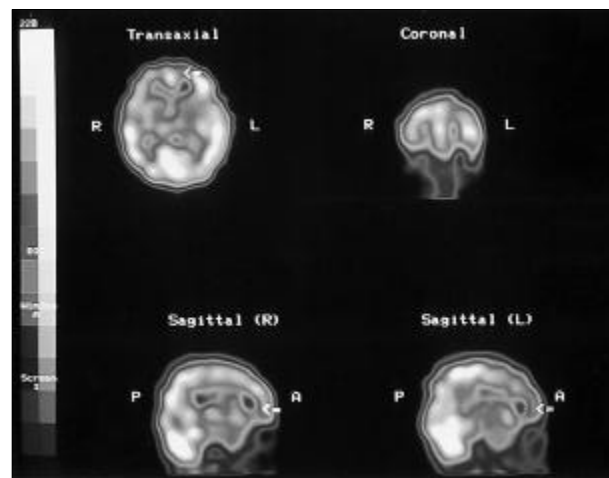


Fig. 3. Abnormal left frontal region findings in a 10-year-old girl with Tourette's Syndrome, as shown by transaxial, sagittal, and coronal images. R, right; L, left; A, anterior; P, posterior.

and controls are provided in Table 1. RCP values were significantly lower in the patient group in left caudate, cingulum, right cerebellum, left dorsolateral prefrontal, and left orbital frontal regions than in the control group.

Fig. 2 shows left caudate hypoperfusion in the transaxial, coronal, and sagittal images of a

9-year-old boy with TS. In Fig. 3 global frontal hypoperfusion is clearly observed in left sagittal image in contrast with the right sagittal image in a 10-year-old girl with TS. Although the position of the head may mislead the reader with respect to the global significance of the right and left frontal regions in transaxial and coronal images,

Table 2. Correlation between Brain Regions and Measures of Severity of tics, Frequency of Tics, CDI, and MOCQ scores (r values)

	S. Motor tic	S. Vocal Tic	Frequency	CDI	MOCQ
r.caudate				-0.4237	-0.3513
l.caudate				-0.4305	-0.3438
Cingulum				-0.4373	
r.cerebellum					
l.cerebellum				-0.2751	
m.cerebellum	0.2889	0.4973		-0.3337	
r.dorsolateral prefrontal		0.3992		-0.4806	
l.dorsolateral prefrontal		0.3992	-0.3209	-0.4807	-0.3034
r.orbitofrontal			-0.3862	-0.4024	-0.2653
l.orbitofrontal					-0.3353
r.anteromedial temporal				-0.5675	-0.4187
l.anteromedial temporal				-0.4442	-0.4981
r.posteromedial temporal				-0.481	-0.4874
l.posteromedial temporal				-0.5406	-0.4227

r values: Pearson's correlation.

r, right; l, left; S. motor/vocal tics, Severity of motor/vocal tics with Goetz Rating Scale; CDI, Children Depression Inventory; MOCQ, Maudsley Obsessional-Compulsive Questionnaire.

in Fig. 3 we try to illustrate focal hypoperfusion in the left frontal region in transaxial and coronal images of the same patient.

The Pearson's correlations in the TS group are shown in Table 2. The mean value of vocal tics were determined to be 3.05 ± 1.03 (minimum: 1, maximum: 5) and the mean value of motor tics to be 3.74 ± 0.81 (minimum: 2, maximum: 5). No significant correlations were found between the severity of motor tics and regional blood flow in any region. The severity of vocal tics was related to regional blood flows in the mid-cerebellum, the right dorsolateral prefrontal, and in the left dorsolateral prefrontal regions. The strongest positive correlation was between the severity of vocal tics and blood flow in the mid-cerebellum region.

The significant correlations between regional blood flow and depression scores were negative, and the strongest negative correlations with the CDI (depression) scores were found in the right anteromedial temporal, and the left posteromedial temporal regions.

The MOCQ (obsession) scores were negatively

correlated with all regional blood flow values especially with the left anteromedial temporal and right posteromedial temporal regions, but these correlations were not as high as for the CDI scores. Eighteen children with TS had coprolalia (%47.4). Patients with coprolalia had significantly lower blood flow in the right dorsolateral prefrontal region ($t=2.17$, $p=0.04$). No significant difference was found between other regions in those with coprolalia.

DISCUSSION

In this study both control and study groups were chosen from children, unfortunately the sample size, was restricted by ethical considerations associated with the administration of radiotracers to the normal population, and this is a limitation of our study.

TS has been recognized for over 150 years.¹ Recently, many studies have focused on the genetic, neuroimaging, and biochemical aspects of

this disorder.¹ TS is defined as a complex neuropsychiatric syndrome with additional disturbances, such as, attention deficit, learning disorders, and obsessive compulsive, and depressive symptoms.^{1,23,24}

Structural imaging studies of TS by for example computerized tomography (CT) and magnetic resonance imaging (MRI) have been disappointing,⁷ and have revealed no consistent abnormalities in patients with TS. Functional imaging studies suggest that regional cerebral physiologic aberrations can be identified in TS.^{25,26}

Although structural imaging studies have yielded inconsistent findings regarding basal ganglia involvement in TS,^{27,28} basal ganglia metabolism has been reported to be correlated with whole brain blood flow in patients with TS.^{25,26} Tc-99m HMPAO SPECT studies in patients with TS have revealed decreased relative blood flow in the left caudate, anterior cingulate cortex, left dorsolateral prefrontal cortex,⁵ left striatal hypoperfusion,⁸ orbito-frontal/basal ganglia,²⁹ left basal ganglia,³⁰ and in the non-dominant basal ganglia.³¹ Our findings of decreased blood flow in the left caudate and cingulum are consistent with previous SPECT studies. The basal ganglia are an accessory motor system that always functions in close association with the cerebral cortex and the corticospinal system. In fact, the basal ganglia receive almost all of their input signals from the cortex itself and in turn return almost all of their output signals to the cortex. They are located mainly lateral to the thalamus, and occupy a large portion of the deeper regions of both cerebral hemispheres. Moreover, almost all of the motor and sensory nerve fibers connecting the cerebral cortex and the spinal cords pass between the two major masses of the basal ganglia, the caudate nucleus and the putamen.^{32,33} The striatum is involved in the initiation and execution of movement,³³ and it has been reported that the medial temporal structures, and the amygdala complex in particular, may play a key role in the neuropathology of TS.³⁴ The present study found no significance between the two groups in terms of the temporal regions.

The cerebellum is especially vital for the control of rapid muscular activities,³³ but has been reported to be uninvolved in TS.⁵ The cerebellum

aids the cerebral cortex in the planning of the next movement a fraction of a second in advance, while the present movement is being executed. It has been reported that the cerebellum is implicated in a range of cognitive processes, and it has been found to be involved in the imagining of movement, and not just in the movement itself.³⁵ In the present study, the right cerebellum blood flow showed moderate hypoperfusion in TS patients. The strongest positive correlation was found between the severity of vocal tics and the mid-cerebellum. Further controlled studies in larger samples are needed to clarify the involvement of the cerebellum in TS.

The cingulum, the orbitofrontal cortex and the left dorsolateral prefrontal regions are the cortical areas in which the prefrontal-subcortical circuits originate.³³ In agreement with previous studies,^{5,9,29,30} we found significant hypoperfusion in the TS group in the cingulum, the left dorsolateral prefrontal region, and the left orbital frontal region compared to the control group. The dorsolateral prefrontal cortex projects primarily to the dorsolateral head of the caudate nucleus, and projections from here are to the dorsomedial globus pallidus interna and rostral substantia nigra. Pallidal and nigral neurons then project to the ventral anterior and medial dorsal thalamic nuclei, which in turn connect back to the dorsolateral prefrontal cortex. Deficits in motor programming, as evidenced by impaired performance on alternating and reciprocal motor tasks, characterize lesions in this circuit.³⁶

We found a positive correlation between the severity of vocal tics and the mid-cerebellum, the right dorsolateral prefrontal and the left dorsolateral prefrontal regions, whereas severity of motor tics was reported to be correlated with hypoperfusion of the left caudate and cingulate, and the left medial temporal region.⁵ Glucose metabolism in the frontal regions was also reported to be negatively correlated with the severity of vocal tics.²⁵ Coprolalia was reported to be negatively correlated with hypometabolism in the left parasylvian region.²⁵ However, in the present study patients with coprolalia were found to have significantly lower blood flow in the right dorsolateral prefrontal region. This result warrants further study.

In the present study, negative correlations were found between the blood flows in all regions and the CDI scores. The strongest correlations were in the both dorsolateral prefrontal, both anteromedial temporal, and both posteromedial temporal regions. In a similar Tc-99m-HMPAO study, decreases in CBF in the left prefrontal and both temporal regions were found in major depression versus healthy controls.³⁷ Hypoperfusion in the left dorsolateral prefrontal region was also found to be related to mood.⁵

In the recent literature, patients with obsessive-compulsive syndrome were found to show hyperperfusion in the frontal brain areas. In contrast, our patients MOCQ scores were negatively correlated with all blood flow values, and the strongest correlated regions were the left anteromedial temporal and right posteromedial temporal regions. The hypoperfusion of the present study is comparable to the findings of George et al.²⁹ These works also found no significant difference in regional blood flow between TS and TS with comorbid obsessive compulsive syndrome.²⁹ In the present study, no comorbid state was found in patients with TS.

Tc-99m-ECD is a new cerebral blood flow imaging agent and has been suggested to have better image quality than Tc-99m-HMPAO images, given its higher radiochemical stability, lower brain washout, and more rapid washout from cerebral tissue. The present study is the first to quantify brain perfusion using Tc-99m-ECD SPECT in children with TS. The regional cerebral blood flows were significantly lower in the TS group in the left caudate, cingulum, right cerebellum left dorsolateral prefrontal, and in the left orbital frontal regions. While no strong correlation between the severity of motor tics and blood flow, a positive correlation were found between the severity of vocal tics and the midcerebellum, right dorsolateral prefrontal, and the left dorsolateral prefrontal regions. In the present study CDI and MOCQ scores were negatively correlated with all blood flow values, especially in the temporal regions. Further well-designed controlled studies in larger samples are needed in patients with TS to explore the perfusion abnormalities of certain brain areas, and the underlying neurophysiology and neurobiology. The effects of additional dis-

turbances, such as, obsessive-compulsive symptoms, and depressive symptoms should also be assessed by SPECT.

REFERENCES

1. Eldridge R, Sweet R, Lake R, Ziegler M, Shapiro AK. Gilles de la Tourette's syndrome: clinical, genetic, psychologic, and biochemical aspects in 21 selected families. *Neurology* 1977;27:115-24.
2. Friedhoff AJ, Chase TN. Gilles de la Tourette Syndrome. New York: Raven Press; 1982. p.454.
3. Robertson MM. Annotation: Gilles de la Tourette Syndrome- An update. *J Child Psychol Psychiatry* 1994; 35:597-611.
4. Robertson MM. The Gilles de la Tourette Syndrome: the current status. *Br J Psychiatry* 1989;154:147-69.
5. Moriarty J, Costa DC, Schmitz B, Trimble MR, Ell PJ, Robertson MM. Brain perfusion abnormalities in Gilles de la Tourette's syndrome. *Br J Psychiatry* 1995;167: 249-54.
6. Jankovic J. The neurology of tics. In: Marsden CD, Fahn S, editors. *Movement disorders 2*. London: Butterworths; 1987. p.383-405.
7. Demeter S. Structural imaging in Tourette syndrome. *Adv Neurol* 1992;58:201-6.
8. Riddle MA, Rasmussen AM, Woods SW, Hoffer PB. SPECT imaging of cerebral blood flow in Tourette Syndrome. *Adv Neurol* 1992;58:207-11.
9. Stoetter B, Braun AR, Randolph C. Functional neuroanatomy of Tourette syndrome. Limbic-motor interactions studied with FDG PET. *Adv Neurol* 1992;58: 213-26.
10. Wong DF, Resnick SM. Neurotransmission. In: Wagner HN, Szabo Z, and Buchanan JW, editors. *Principles of Nuclear Medicine*. Philadelphia: WB Saunders Company; 1995. p.590-4.
11. Wong DF, Singer H, Shaya E, Brandt J, Chen C, Brown J, et al. D2 dopamine receptor densities measured by C-11 NMSP PET in Tourette Syndrome. *J Nucl Med* 1992;33:848-55.
12. Neirinckx R, Canning L, Piper I. Technetium-99m d,l-HMPAO: a new radiopharmaceutical for SPECT imaging of regional cerebral blood perfusion. *J Nucl Med* 1987;28:191-202.
13. Newton MR, Austin MC, Chan G. Ictal SPECT using technetium-99m-HMPAO: methods for rapid preparation and optimal deployment of tracer during spontaneous seizures. *J Nucl Med* 1993;34:666-70.
14. Leveille J, Demonceau G, De Roo M. Characterization of Tc-99m-L,L-ECD for brain perfusion imaging. Part 2. Biodistribution and brain imaging in humans. *J Nucl Med* 1989;30:1902-10.
15. Leveille J, Demonceau G, Walovitch RC. Intrasubject comparison between Technetium-99m-ECD and Technetium-99m-HMPAO in healthy human subjects. *J Nucl*

- Med 1992;33:480-4.
16. Walovitch RC, Hill TC, Garrity ST. Characterization of technetium-99m-L,L-ECD for brain perfusion imaging, part 1: pharmacology of technetium-99m ECD in non-human primates. *J Nucl Med* 1989;30:1892-901.
 17. Moretti JL, Defer G, Cinotti L. Comparative tomoscintigraphic study of strokes using ECD Tc-99m, HMPAO Tc-99m and IMP I-123, preliminary results [abstract]. *Eur J Nucl Med* 1988;14:311-1.
 18. World Health Organization. ICD-10, draft of chapter V, mental, behavioral and developmental disorders. Clinical Descriptions and Diagnostic Guidelines. World Health Organization, Geneva, 1988.
 19. American Psychiatric Association. Diagnostic and Statistical Manual of Mental Disorders, 4th edition (DSM-IV). Washington, DC: American Psychiatric Association; 1994.
 20. Goetz CG, Tanner CM, Wilson RS, Shannon KM. A rating scale for Gilles de la Tourette's syndrome: Description, reliability, and validity data. *Neurology* 1987;37:1542-4.
 21. Oy B. Children Depression Inventory: Validity and Reliability Study. *Turk J Psychiatry* 1991;2:132-6.
 22. Erol N, Savasir I. The Turkish version of the Maudsley Obsessional-Compulsive Questionnaire. Presented in the 2nd Regional Conference of the International Association of Cross-cultural Psychology, Amsterdam, 1989.
 23. Comings DE, Comings BG. Tourette syndrome: clinical and psychological aspects of 250 cases. *Am J Hum Genet* 1985;37:435-50.
 24. George MS, Trimble MR, Ring HA, Sallee FR, Robertson MM. Obsessions in obsessive-compulsive disorder (OCD) with and without Gilles de la Tourette Syndrome. *Am J Psychiatry* 1993;150:93-7.
 25. Chase TN, Foster N, Fedio P. Gilles de la Tourette syndrome: Studies with the fluorine-18-labeled fluorodeoxyglucose positron emission tomographic method. *Ann Neurol* 1984; 15 Suppl:175-80.
 26. Chase TN, Geoffrey V, Gillespie M. Structural and functional studies of Gilles de la Tourette syndrome. *Rev Neurol* 1986;142:851-6.
 27. Kjaer M, Boris P, Hansen LG. Abnormal CT scan in a patient with Gilles de la Tourette syndrome. *Neuroradiology* 1986;28:362-3.
 28. Harcherik DF, Cohen DJ, Ort S. Computed tomographic brain scanning in four neuropsychiatric disorders of childhood. *Am J Psychiatry* 1985;142:731-4.
 29. George MS, Trimble MR, Costa DC, Robertson MM, Ring HA, Ell PJ. Elevated frontal cerebral blood flow in Gilles de la Tourette syndrome: a Tc-99m HMPAO SPECT study. *Psychiatry Res* 1992;45:143-51.
 30. Sieg KG, Buckingham D, Gaffney GR, Preston DF, Sieg G. Tc-99m HMPAO SPECT brain imaging of Gilles de la Tourette's syndrome. *Clin Nucl Med* 1993;18:255-61.
 31. Dimitropoulos T, Klieger P, Kurlan R. Asymmetry of basal ganglia perfusion in Tourette's syndrome shown by Single Photon Emission Tomography [abstract]. *Mov Disord* 1993;8:415-6.
 32. Alexander GE, DeLong MR, Strick PL. Parallel organization of functionally segregated circuits linking basal ganglia and cortex. *Annu Rev Neurosci* 1986;9:357-81.
 33. Guyton AC. Textbook of medical physiology. Philadelphia: WB Saunders Company; 1991. p.626-7.
 34. Jadresic D. The role of the amygdaloid complex in Gilles de la Tourette's syndrome. *Br J Psychiatry* 1992; 161:532-4.
 35. Decety J, Sjöholm H, Ryding E. The cerebellum participates in mental activity: tomographic measurements of regional cerebral blood flow. *Brain Res* 1990; 535:313-7.
 36. Cummings JL. Frontal-subcortical circuits and human behaviour. *Arch Neurol* 1993;50:873-80.
 37. Yazici KM, Kapucu O, Erbas B, Varoglu E, Gulec C, Bekdik DF. Assessment of changes in regional cerebral blood flow in patients with major depression using the 99mTc-HMPAO single photon emission tomography method. *Eur J Nucl Med* 1992;19:1038-43.