

Laser Photocoagulation Repair of Recurrent Macula-Sparing Retinal Detachments

Eun Suk Lee, Hyung Jun Koh, Oh Woong Kwon, and Sung Chul Lee

The Institute of Vision Research, Department of Ophthalmology, Yonsei University College of Medicine, Seoul, Korea.

Laser photocoagulation was performed around a detached retina in 4 patients who developed localized retinal detachment after successful scleral buckling. The range of retinal redetachment in all 4 patients was no larger than that of the initial retinal detachment and did not go over the vascular arcade. No evidence of vitreous traction or proliferative vitreoretinopathy was observed in these cases. Laser photocoagulation was performed in 3 lines of gray-white burn around the detached retina. Retinal attachment occurred between 4 and 14 days of laser treatment in all cases. No procedure related complications were seen. Laser photocoagulation may be an alternative procedure for the treatment of redetached retina with little and shallow detachment, before considering resurgery.

Key Words: Laser photocoagulation, recurrent retinal detachment, scleral buckling

INTRODUCTION

Although most rhegmatogenous retinal detachments can be cured with scleral buckling, a finite number of retinas remain detached or become detached after successful attachment.¹ After attaching 1088 consecutive cases of retinal detachment by scleral buckling, Rachal and Burton² reported a final success rate of 89%.

The reasons for failure after scleral buckling include proliferative vitreoretinopathy (PVR),

unsupported retinal breaks, which were either new or not recognized at the time of the initial surgery, and inadequate buckling of a recognized break.^{1,3}

Despite accurate buckle placement, with recognition of all retinal breaks, the detached retina may not be attached or maybe detached after successful attachment. If there is a correctable reason for this retinal detachment, such as PVR, unsupported retinal breaks or previously unrecognized breaks, resurgical correction would be inevitable. However, when there is no obvious reason for the detachment after the successful closure of all primary breaks, some surgeons may decide to perform additional surgery, such as the repositioning of the buckle or vitrectomy, while others would decide to wait for news of any further changes, hoping that the detached retina does not progress, and possibly that it regresses spontaneously.

In the present study, we report the results of laser photocoagulation performed in patients with recurrent macular-sparing retinal detachment after successful buckling, uncomplicated by proliferative vitreoretinopathy.

MATERIALS AND METHODS

We reviewed the medical records of 4 consecutive patients who underwent laser photocoagulation due to retinal redetachments. All of these 4 patients had localized recurrent retinal detachment after successful scleral buckling with no accompanying macula invasion, vitreal traction, additional retinal breaks, or PVR. The retinal breaks, which had caused the initial detachments,

Received February 8, 2002

Accepted May 28, 2002

This paper was presented at the 85th Korean Ophthalmological Society Meeting, Busan, Korea, April, 2001.

Reprint address: requests to Dr. Sung Chul Lee, Department of Ophthalmology, Yonsei University College of Medicine, C.P.O. Box 8044, Seoul 120-752, Korea. Tel: 82-2-361-8450, Fax: 82-2-312-0541, E-mail: sclee@yumc.yonsei.ac.kr

were all closed at the time of redetachments.

We considered laser treatment in cases with extensive retinal detachment that approached the optic disc or macula, and in cases when the retina was difficult to observe due to vitreous hemorrhage.

Information on gender, age, corrected visual acuity, records of the initial retinal reattachment, number and shape of retinal tears, range of retinal detachment, degree of refractive error, presence of lattice degeneration, and follow-up period were obtained from the patient's medical records. We explained to each patient on treatment options including observation, adjustment of scleral buckling, surgery such as vitreous surgery, and laser photocoagulation, and the need for additional surgery with failed laser photocoagulation was explained to each patient. Three lines of gray-white burns were made with the laser in the area surrounding the retinal detachment, i.e., from the back of the detached retina to the ora serrata.

Case report

Case 1

A 43-year-old man noticed a visual defect in his right eye 3 days before he visited our clinic. Corrected visual acuity in right eye was 1.0 with an axial length of more than 27.0 mm. The patient had received scleral buckling in his left eye 5 years previously. Ophthalmologic examination revealed retinal detachment from 4 to 7.30 o'clock and a horseshoe-shape tear between 4 and 5 o'clock. Scleral encircling was performed using a 4.0 mm sponge, trans pars plana vitrectomy (TPPV), and laser photocoagulation around the hole at the same time. TPPV was chosen because the break could not be well supported by scleral buckling alone with remaining traction at the tear flap. The retina was well attached on the 4th postoperative day, resulting in an uncorrected visual acuity of 0.4. On postoperative 11th day, retinal detachment was observed between 3.30 and 5.30 o'clock. Laser photocoagulation was performed around the retinal detachment, and the patient was treated with 1000 mg of acetazolamide/day for a week. The examination performed one week after laser photocoagulation revealed absorbed subretinal fluid and an uncorrected

visual acuity of 0.6. The retina remained attached during the post-procedural 5-month follow-up period (Fig. 1A).

Case 2

A 20-year-old man was referred to our department due to an asymptomatic retinal detachment in his right eye. His right eye was highly myopic at -7.00 diopter with a corrected visual acuity of 0.8. Shallow retinal detachment between 4.30 and 9 o'clock with an atrophic hole at 8 o'clock was discovered during a routine ophthalmologic examination prior to refractive surgery. We performed segmental scleral buckling with a 3.0 mm sponge and cryotherapy around the hole. The retina attached on the 4th postoperative day and his corrected visual acuity was 1.0. Ophthalmologic examination showed retinal detachment between 6.30 and 9 o'clock on the 9th postoperative day and laser photocoagulation was done. When the patient returned to the clinic 4 days after the laser treatment, complete retinal reattachment was observed with a corrected vision of 1.0. The retina was stably attached throughout the 6-month follow-up period (Fig. 1B and 2).

Case 3

A 44-year-old man visited our department due to a sensation of blocked vision of 2 days duration in his right eye, which was myopic at -7.00 diopter and had a corrected visual acuity of 1.0. The patient had shallow retinal detachment, which was accompanied by 3 atrophic holes between 9 and 12.30 o'clock. Scleral encircling was performed using a 3.0 mm sponge and cryotherapy around the hole. The retina was well attached and remained stable from 18 days after the operation. Asymptomatic shallow retinal detachment was detected between 9 and 10.30 o'clock on the 35th postoperative day, and laser photocoagulation was performed. When he was re-examined 2 weeks after the laser treatment, the retina was well attached, and it maintained this condition through the 6-month follow-up (Fig. 1C).

Case 4

A 57-year-old woman visited our clinic due to deteriorating eyesight over the previous 3 months. The corrected visual acuity of the right eye was

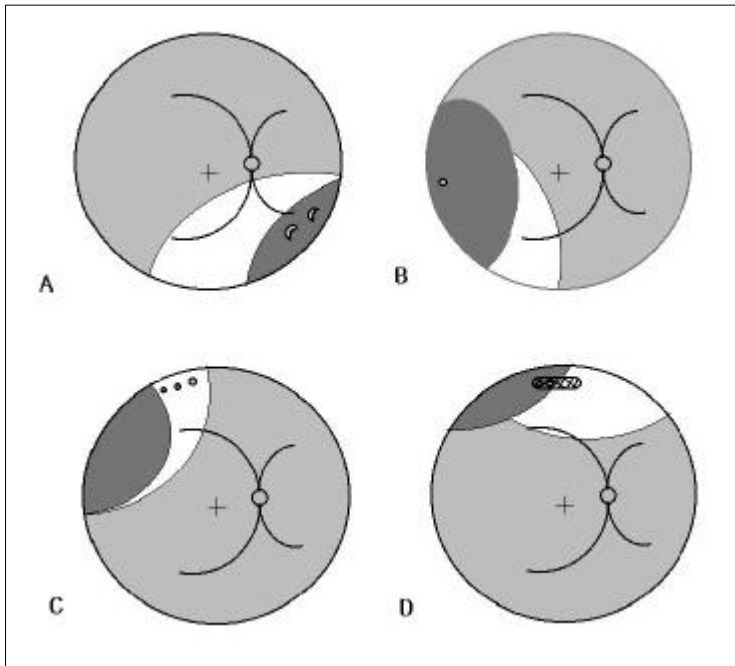


Fig. 1. Schematic retinal drawing showing the area of primary retinal detachments (colored white) and redetached retina, which was initially successfully reattached (colored dark gray) in each case.

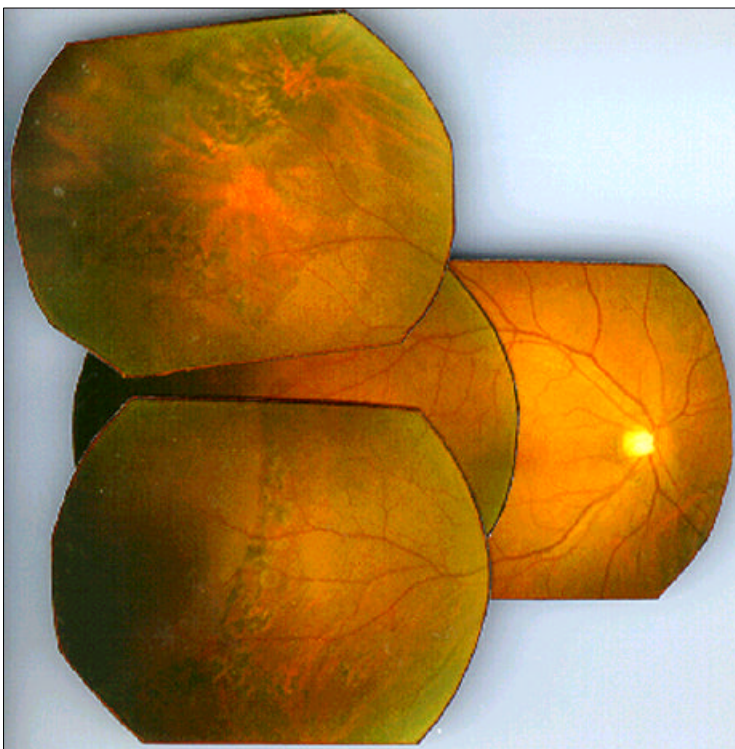

Fig. 2. Fundus panoramic photograph taken 3 months after laser treatment. The retina is well attached with visible laser scars (dark gray dots) along the margin of the previously redetached area (6.30 to 9 o'clock).

0.7, and the retinal detachment was accompanied by lattice degeneration and atrophic holes between 11 and 2 o'clock. Retinal attachment was performed by segmental buckling using a 3.0 mm

sponge, but subretinal fluid was observed between 10 and 12 o'clock on the 18th postoperative day. Laser photocoagulation was then performed to reattach the retina. When the patient

returned to the clinic 7 days after the photocoagulation, complete retinal attachment was observed with a corrected vision of 0.7. The retina remained stable during the 10-month follow-up period (Fig. 1D).

RESULTS

Initial retinal detachments in all 4 cases were approximately one quadrant in size with no macula invasion. Despite retinal detachment, visual acuities were relatively good between 0.7 and 1.0 since maculas were not invaded. Three of these patients were highly myopic. As for the shape of retinal tear, round holes were present in 3 cases, lattice degeneration was associated in 1 case, and retinal detachment due to a horseshoe-shaped tear was present in 1 case.

The surgery for initial retinal detachment was scleral encircling buckle with TPPV in 1 cases, scleral encircling buckle only in 1 case, and segmental buckling in 2 cases. The period between initial surgery and detachment was between 4 and 35 days. The size of redetachments was smaller than the range of initial detachments, and redetachments did not exceed one quadrant and were slightly beyond the equator in the back. Redetachment included the retinal tears present at the time of the initial detachment in 3 out of 4 cases and did not include the retinal tears in the remaining case, in which no further retinal holes were detected.

The retina reattached in all 4 cases after laser photocoagulation, and reattachment occurred between 4 and 14 days post-operatively. Since all patients were reexamined on an out-patient basis, neither the exact time of the retinal redetachment nor the period between photocoagulation and retinal reattachment was known. Retinal attachment with vision improvement occurred in 1 patient. The follow-up period was between 4 and 10 months, with an average of 7 months. Outpatient visits were made at 1, 3, and 6 weeks and at 3 months after laser photocoagulation except when patients refused to attend the clinic on a particular day for personal reason. During this follow-up period, no complication related to laser treatment, such as glaucoma, preretinal membrane

or macular edema was observed.

DISCUSSION

Vitroretinal surgery is indispensable for the management of macula-off rhegmatogenous retinal detachments. However, the optimal management strategy for certain macula-sparing rhegmatogenous retinal detachments, including those called *limited*, *subclinical*, on *asymptomatic*, is ambiguous since not only is the natural history of localized retinal detachment lacking but its treatment basis is unclear.⁴⁻⁶

In cases of *recurrent* retinal detachment, the cause must be determined and treatments are focused on addressing such cause, such as, PVR, unsupported retinal breaks, either new or unrecognized previously, and inadequate buckling. The choice becomes more complex when recurrent retinal detachments have no obvious reason. *Unfortunately, there is a sparsity of reported statistics on the course and the treatment of these detachments.* One such report suggests vitreous surgery with a fiberoptic probe and a vitroretinal pick to identify a possible slit-like hidden retinal break when no retinal break is visible in a recurrent detachment after successful scleral buckling.⁷ Others also support early reoperation by explaining that *recurrent* retinal detachment especially within 1 week of initial surgery strongly suggests inadequate relief of traction at the time of initial surgery.⁸ However, other surgeons suggest observing such changes with the expectation that the detached retina does not progress and possibly regresses spontaneously with or without supplemental photocoagulation even though the courses of these recurrent redetachments are not clear, because their causes are unknown. We reported these 4 cases of recurrent retinal detachments to reassure those who prefer not to rush into a reoperation, which can cause unnecessary complications.

Laser photocoagulation could be said to be somewhere between active surgical treatment and passive observation.⁹⁻¹² According to Vrabec and Bauma,⁴ the treatment results of demarcation laser photocoagulation in 34 cases of macula-sparing retinal detachment with no PVR showed

that 33 eyes were stable, 1 eye needed scleral buckling, and 3 eyes showed spontaneous flattening. Chan et al.⁹ performed laser photocoagulation on top of the buckle and around tears in persistent retinal detachment after scleral buckling and reported that additional surgery was not required in 71 (63%) of 113 eyes.

The potential advantages of laser photocoagulation over surgery are the limited possibility of complications and a reduction in surgical complication that could affect vision, such as infection and hemorrhage.^{4,13,14}

It is not clear whether retinal redetachment developing after scleral buckling also falls into the range of treatment of localized retinal detachment, since the reason of the detachment is not clear, as it is only assumed that vitreous gel contraction or traction participate in the redetachment, and the possibility of progression of detachment also is not clear. However, if a hole has not been opened, one could expect that the scleral buckling already performed would act as the force that reattaches the retina and the laser photocoagulation around the detached retina, strengthens the choroids-retina attachment, and promotes the natural absorption of subretinal fluid.

The retina reattached in all 4 cases after laser photocoagulation in the present study, even if the reason for redetachment cannot be simply explained. Laser treatment can be considered in those retinal redetachment cases with a shallow smooth detachment without corrugation.

REFERENCES

1. Williams GA, Aaberg TM Sr. Techniques of scleral buckling. In: Ryan SJ, Wilkinson CP, editors. *Retina*. 3rd ed. St Louis: Mosby, Inc; 2001. p.2010-45.
2. Rachal WF, Burton TC. Changing concepts of failures after retinal detachment surgery. *Arch Ophthalmol* 1979;97:480-3.
3. Lincoff HA, Kreissig I. Extraocular repeat surgery of retinal detachment; a minimal approach. *Ophthalmology* 1996;103:1586-92.
4. Vrabec TR, Bauman CR. Demarcation laser photocoagulation of selected macula-sparing rhegmatogenous retinal detachments. *Ophthalmology* 2000;107:1063-7.
5. Schepens CL. Subclinical retinal detachments. *Arch Ophthalmol* 1952;47:593-606.
6. Benson WE, Nantawan P, Morse PH. Characteristics and prognosis of retinal detachment with demarcation lines. *Am J Ophthalmol* 1977;64:1-4.
7. Wilkinson CP, Rice TA. Complicated types of retinal detachment. In: Wilkinson CP, Rice TA, editors. *Michels retinal detachment*. 2nd ed. St Louis: Mosby, Inc; 1997. p.641-771.
8. Thompson JT. Complicated forms of retinal detachment. In: Ryan SJ, Wilkinson CP, editors. *Retina*. 3rd ed. St Louis: Mosby, Inc; 2001. p.2287-316.
9. Chan CK, Olk RJ, Arribas NP, Escoffery RF, Grand MG, Schoch LH. Supplemental photocoagulation on the buckle for prevention of surgical revision after scleral buckling procedure. *Arch Ophthalmol* 1987;105:490-6.
10. Curtin VT, Norton EWD, Gass JDM. Photocoagulation: Its use in the prevention of reoperation after scleral buckling operations. *Trans Am Acad Ophthalmol Otol* 1967;71:432-41.
11. Freyler H, Gnad HD. Photokoagulation zur unterstützung eindellender operationverfahren bei amotio retinae. *Klin Monatsbl Augenheilkd* 1982;181:315-9.
12. Urrets-Zavalía A Jr. Late postoperative photocoagulation in the treatment of retinal detachment. In: Girard L, editor. *9th Pan American Congress of Ophthalmology*, Houston: Pan American Congress of Ophthalmology; 1972.
13. Vrabec TR. Laser photocoagulation repair of macula-sparing cytomegalovirus-related retinal detachment. *Ophthalmology* 1997;104:2062-7.
14. Davis JL, Hummer J, Feuer WJ. Laser photocoagulation for retinal detachment and retinal tears in cytomegalovirus retinitis. *Ophthalmology* 1997;104:2053-61.