

Incidentally Found Pharyngoesophageal Diverticulum on Ultrasonography

Jinna Kim¹, Young Jin Kim¹, Eun-Kyung Kim¹, and Cheong Soo Park²

Departments of ¹Diagnostic Radiology and ²General Surgery, Yonsei University College of Medicine, Seoul, Korea.

The pharyngoesophageal diverticulum in the lower part of the neck can be detected using neck ultrasonography. We present a case of pharyngoesophageal diverticulum mimicking a thyroid nodule, which was found incidentally by ultrasonography, and discuss its peculiar findings, which might be useful to diagnose pharyngoesophageal diverticulum and to prevent invasive procedures such as needle aspiration biopsy.

Key Words: Pharyngoesophageal diverticulum, ultrasonography, thyroid nodule

INTRODUCTION

The pharyngoesophageal, or Zenker's diverticulum, is the most common diverticulum of the esophagus.¹ It is usually found incidentally, using esophagography. It can, however, also be detected by neck ultrasonography, a technique frequently used for examining the thyroid in recent years.² We report a case in which the pharyngoesophageal diverticulum mimicked a thyroid nodule using ultrasonography, and using ultrasonographic images, we discuss the implications of their findings, with particular reference to avoiding unnecessary invasive procedures.

CASE REPORT

A 65-year-old man presented with a lump in the throat for the past four years. Results obtained

from physical and laboratory examinations of the patient were normal.

Ultrasonography was performed using a real-time linear array unit with a 5-10 MHz transducer. The ultrasonography demonstrated a $1.0 \times 0.7 \times 1.0$ cm-sized, poorly defined, hypoechoic lesion in the posterolateral aspect of the right lobe of the thyroid (Fig. 1A). The hypoechoic lesion had multiple echogenic foci within it. The remaining tissue of the thyroid was normal-sized and echotextured. No pathologic lymphadenopathy was noted along either of the internal jugular chains. Given that we suspected a thyroid malignancy, such as papillary carcinoma containing internal calcification, fine needle aspiration was planned.

When a second ultrasonography was performed for needle aspiration three weeks later, the shape of the lesion was observed to change intermittently whenever the patient swallowed. In addition, the lesion appeared to be connected to the cervical esophagus in the longitudinal plane (Fig. 1B). Consequently, esophagography was performed that revealed an approximately 1.0 cm-sized diverticulum in the right side of the cervical esophagus (Fig. 1C).

DISCUSSION

The pharyngoesophageal, or Zenker's diverticulum, is the most common diverticulum of the esophagus. Pathologically, it is lined by esophageal mucosa and submucosa. It is an acquired pulsion diverticulum, situated posteriorly, in the lower part of the neck. Larger diverticula tend to flop to the left side, and may compress and obstruct the esophagus.¹ There have been five

Received June 18, 2001

Accepted October 15, 2001

Reprint address: requests to Dr. Eun-Kyung Kim, Department of Diagnostic Radiology, Yonsei University College of Medicine, C.P.O. Box 8044, Seoul 120-752, Korea. Tel: 82-2-361-5837, Fax: 82-2-393-3035, E-mail: ekkim@yumc.yonsei.ac.kr

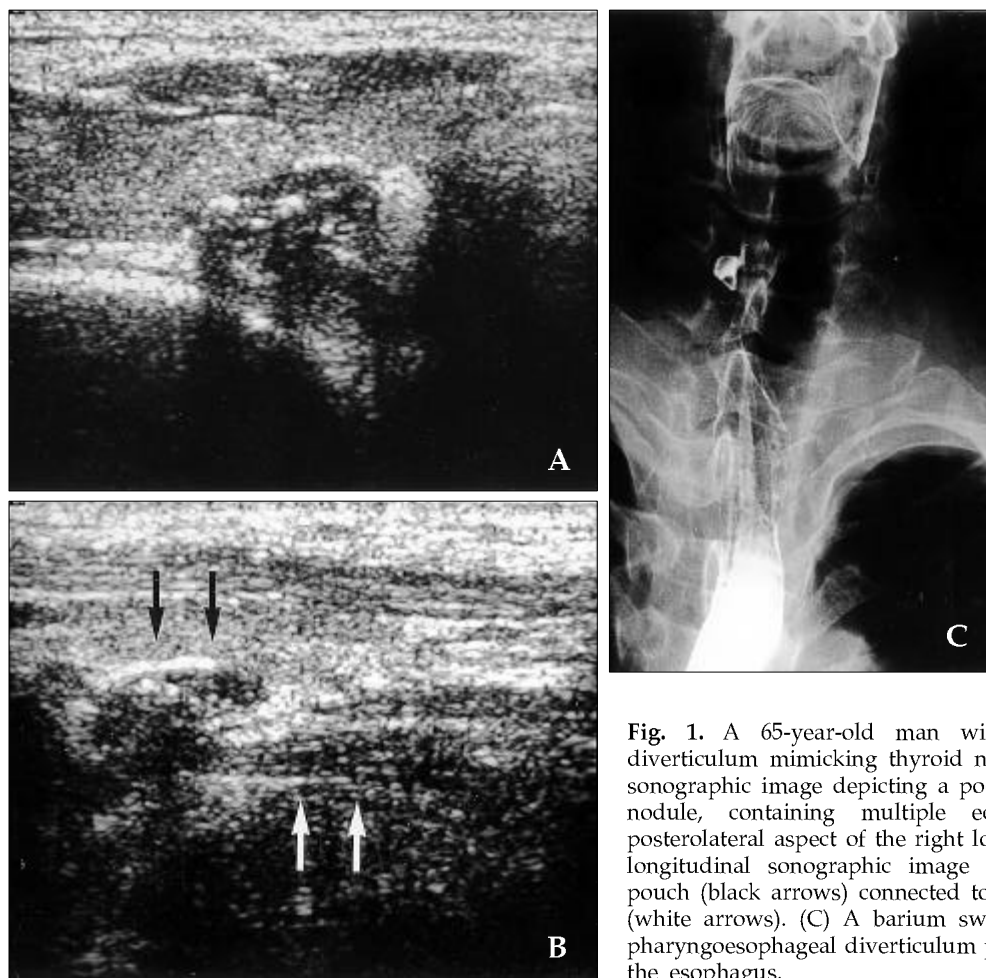


Fig. 1. A 65-year-old man with pharyngoesophageal diverticulum mimicking thyroid nodule. (A) A transverse sonographic image depicting a poorly defined hypoechoic nodule, containing multiple echogenic foci in the posterolateral aspect of the right lobe of the thyroid. (B) A longitudinal sonographic image depicting a protruding pouch (black arrows) connected to the cervical esophagus (white arrows). (C) A barium swallow study confirms a pharyngoesophageal diverticulum projecting to the right of the esophagus.

reports using ultrasonography of six cases of Zenker's diverticulum.^{1,3-6} In all instances, thyroid nodules were initially suspected due to a palpable mass in the lower neck, found on physical examination of the patients. The pharyngoesophageal diverticulum in this study was the first one found, incidentally, using ultrasonography. At its beginning, the esophagus was median, but deviated to the left as far as the root of the neck, gradually returning to the median plane near the fifth thoracic vertebra. In this case, the esophagus was distinctly placed on the right side of the trachea and the diverticulum was unusually located on the right side of the esophagus. The possible diseases suggested from differential diagnosis would be thyroid nodules (benign and malignant), thyroid abscesses, parathyroid hyperplasia and adenoma, benign or malignant lymphadenopathy, or pharyngocele and paratracheal air cysts.^{1,6,7}

denopathy, or pharyngocele and paratracheal air cysts.^{1,6,7}

In this case, the pharyngoesophageal diverticulum could be differentiated from thyroid nodules for the following three reasons; Firstly, the shape of the lesion changed constantly when the patient swallowed. This phenomenon is possibly due to esophageal peristaltic movement initiated by swallowing, air movement, or fluid or dietary residue in the diverticulum.^{3,4} Secondly, ultrasonographic examination revealed its connection to the cervical esophagus in the sagittal plane. Thirdly, the air in the esophagus caused a comet tail artifact, or reverberation artifact, resulting in echogenic foci within the diverticulum. The linear echogenic line on the interface between the pharyngoesophageal diverticulum and the thyroid parenchyma was also demonstrated. Echogenic

foci, due to the air in diverticulum, can cause confusion when one should distinguish calcification of thyroid malignancy such as papillary carcinoma from pharyngoesophageal diverticulum. Several reports also noted that nodular shadows were surrounded by the boundary hypoechoic zone, which resembles thyroid capsules, and suggests the stratal structure of the digestive tract.^{1,3,5,6}

The diagnosis of pharyngoesophageal diverticulum could be confirmed by employing a barium swallow study, which would demonstrate a protruding pouch filled with barium.

When a hypoechoic nodule containing echogenic foci is found in the posterolateral aspect of the thyroid using ultrasonography, we should not exclude the possibility of a pharyngoesophageal diverticulum mimicking thyroid nodules. Instead, observations should be made to see if the structure changes shape, and esophagography should be performed for purposes of confirmation.

REFERNECES

1. Kumar A, Aggarwai S, Pham DH. Pharyngoesophageal (Zenker's) diverticulum mimicking thyroid nodule on ultrasonography: report of two cases. *J Ultrasound Med* 1994;13:319-22.
2. Yokozawa T, Fukata S, Kuma K, Matsuzuka F, Kobayashi A, Hirai K, et al. Thyroid cancer detected by ultrasound-guided fine-needle aspiration biopsy. *World J Surg* 1996;20:848-53.
3. DeFriend DE, Dubbins PA. Sonographic demonstration of a pharyngoesophageal diverticulum. *J Clin Ultrasound* 2000;28:485-7.
4. Hayashi N, Tamaki N, Konishi J. Lateral pharyngoesophageal diverticulum simulating thyroid adenoma on sonography. *J Clin Ultrasound* 1984;12:592-4.
5. Biggi E, Derchi LE, Cicio GR, Neumaier CE. Sonographic findings of Zenker's diverticulum. *J Clin Ultrasound* 1982;10:395-6.
6. Komatsu M, Komatsu T, Inove K. Ultrasonography of Zenker's diverticulum: special reference to differential diagnosis from thyroid nodules. *Eur J Ultrasound* 2000; 11:123-5.
7. Goo JM, IM JG, Ahn JM, Moon WK, Chung JW, Park JH, et al. Right paratracheal air cysts in the thoracic inlet: clinical and radiologic significance. *AJR* 1999;173: 65-70.