

# Quantitative and Qualitative Muscular Changes after Selective Neurotomy

Kwan Chul Tark, Seong Joon Ahn, Tai Suk Roh, and Beyoung Yun Park

*Department of Plastic and Reconstructive Surgery, Yonsei University College of Medicine, Seoul, Korea.*

Disfigurement of body contour, caused by excessive muscular hypertrophy, can seldom be effectively and safely corrected by lipectomy, liposuction or combined partial myomectomy. This study was conducted to obtain basic knowledge for the development of a safe and effective method of treating patients with excessive and unwelcome muscle hypertrophy. Accordingly, we developed a new experimental rat model, consisting of the peroneal nerve and its target muscles - the anterolateral crural muscle group. After severance of 1/4, 1/2, and 1/1 of the peroneal nerve, functional parameters based on gross movement and electrophysiologic data were monitored. Changes in the external circumference and weight of the anterolateral crural muscle were documented and compared with control sides. Histologic and histomorphometric parameters of the muscle were also documented.

Average takeoff latency in 1/4 and 1/2 neurotomy groups was increased to 130% and 154% of the control at 3 months, and 156% and 149% of control at 6 months, respectively. Similarly, average peak-to-peak compound action potentials were 72% and 59% of the control at 3 months and 57% and 50% of control at 6 months. No definite gait disturbances were evident in the partial neurotomy groups.

Maximal circumferences of the anterolateral crural muscle group were significantly reduced to 86%, 71% and 66% of the control in the 1/4, 1/2 and 1/1 neurotomy groups at 3 months ( $p < 0.001$ ), and to 74%, 68% and 64% of the control at 6 months, respectively ( $p < 0.001$ ). The corresponding weights were 76%, 62%, and 50% of the control sides at 3 months, and 70%, 56%, and 48% at 6 months in 1/4, 1/2 and 1/1 neurotomy groups.

Histograms drawn showing the number of muscle fibers per  $\text{mm}^2$  in cross-sections, showed a total number of  $239 \pm 52$

in the control group; the size of muscle fibers was mainly medium to large. The more extensive the neurotomy, the greater the was the number of small angulated muscle fibers, up to a total of  $1,564 \pm 211$ .

Although more research work and clinical trials are required, we believe that selective neurotomy has the potential of being an effective tool for reducing muscle bulk, and avoiding apparent muscular dysfunction and complications.

**Key Words :** Selective neurotomy, muscle change after neurotomy, small angulated muscle fiber, nerve, denervation, electromyography after neurotomy, muscle circumference, muscle weight, nerve conduction velocity, compound action potential

## INTRODUCTION

Severance of a peripheral motor nerve invariably results in Wallerian degeneration, and leads to atrophic changes of the denervated muscle groups, which are finally replaced by ineffectual fibrous tissue.<sup>1</sup> The degree of muscle atrophy is mainly affected by myosin-ATPase activity,<sup>2</sup> but the process is also influenced by the type and severity of the initial nerve injury.

With the growing interest in the correction of contour imbalance and deformity, a need has risen to effectively address the problem of excessive adipose deposit and of the hypertrophic muscular component that largely comprises such deformities. Lipectomy and liposuction techniques are available, to efficiently handle the former, but these fall short of reducing muscle bulk. This is especially evident in contouring surgery of the calf areas, where the reduction of unwanted muscular bulk far outweighs the need for lipoplasty techniques for optimal results. In such a context, partial myomectomy has been advocated

Received September 19, 2001

Accepted September 24, 2001

*This study was supported by a Faculty Research Grant of Yonsei University College of Medicine for 1997 (No. 1997-16).*

*Reprint address: requests to Dr. Kwan Chul Tark, Department of Plastic and Reconstructive Surgery, Yonsei University College of Medicine, C.P.O. Box 8044, Seoul 120-752, Korea. Tel: 82-2-361-5694, Fax: 82-2-393-6947, E-mail: kctark@yumc.yonsei.ac.kr*

concurrently with a liposuction procedure, but the suggestion has failed to gain wide acceptance due to the risk of possible complications, such as motor dysfunction, internal hemorrhage and nerve injury.<sup>3,4</sup>

The purpose of this study was to develop a safe and novel technique for effectively reducing muscle volume, by controlled the denervation of a selected muscle group, without adversely affecting motor function. Using a rat model, changes in muscle volume, weight, size and morphologic parameters were obtained after selective neurotomy, by gross, histologic and histomorphometric analysis. Functional parameters based on gross movement and electrophysiologic data were monitored concurrently.

It is hoped that this study will set the basis for the future development of a safe and effective method of treating patients with excessive and unwelcome muscle hypertrophy.

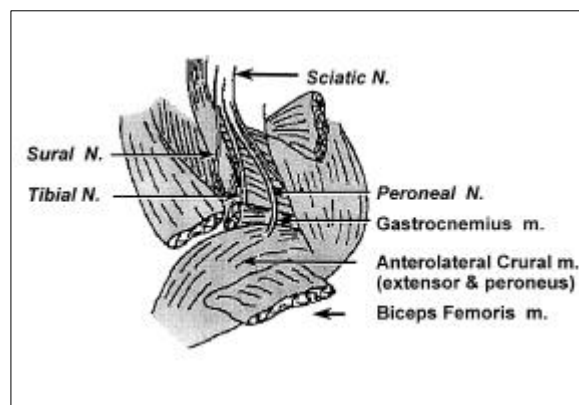
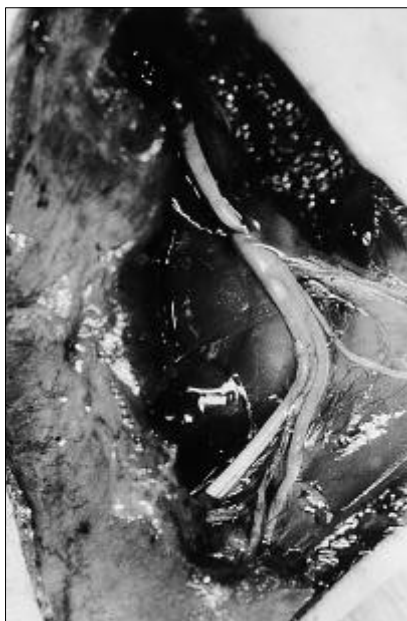### Hind Leg Anatomy and Function in the Rat

The sciatic nerve divides into two terminal components, the common peroneal and tibial nerves. At the level of the greater trochanter, the common peroneal nerve offers an articular branch to the knee joint, and the sural nerve similarly offers a branch to the skin of the lower leg. It then traverses the lateral surface of the superior muscular

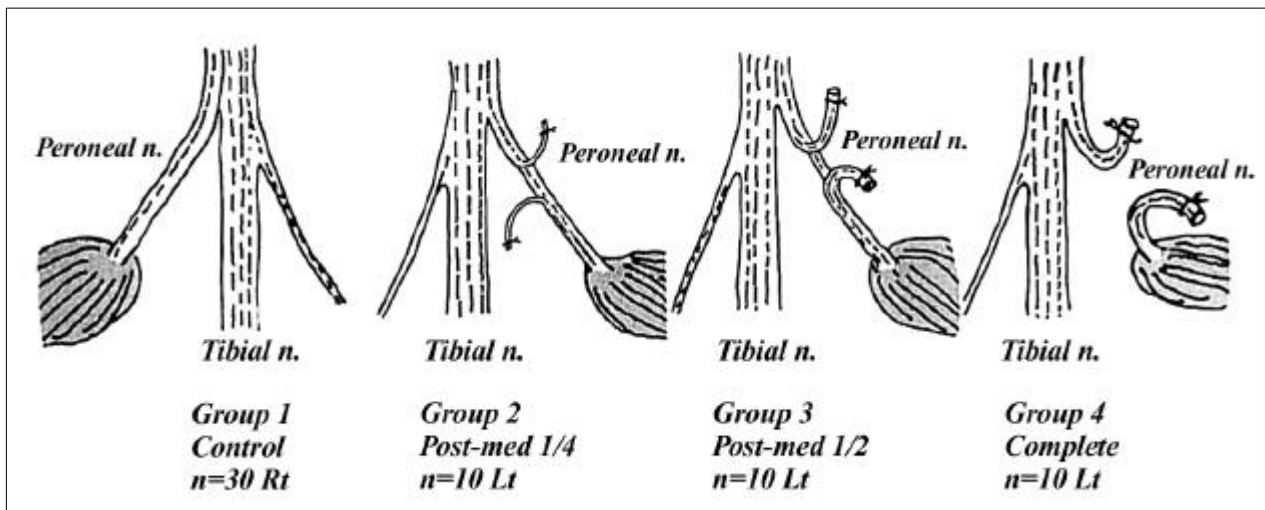
branch of the popliteal artery and enters the lower leg between the biceps femoris and the lateral head of the gastrocnemius. Below the knee the common peroneal nerve divides into the superficial and deep peroneal branches (Fig. 1, left and right). The anterior crural muscles - the tibialis anterior, extensor digitorum longus and extensor hallucis longus - are innervated solely by the deep peroneal nerve. The tibialis anterior dorsally flexes and supinates the foot, and the extensor digitorum longus and the extensor hallucis longus extend proximal phalanges and dorsally flex and supinate the foot. The lateral crural muscle group - the peroneuses - are innervated by the superficial and deep peroneal nerves, which pronate and plantar flex the foot. The posterior crural muscles - the gastrocnemius, soleus, plantaris, and popliteus flexor group and tibialis posterior are innervated by the tibial nerve (Fig. 1).<sup>5</sup>

### MATERIALS AND METHODS

Thirty Sprague-Dawley rats weighing 300 to 350 gm were anesthetized by intraperitoneally administered 4% chloral hydrate (0.75 ml/100 gm body weight). The left hind limb and gluteal region were then depilated with the topical agent Nair® (Carter-Wallace Inc., New York, USA) and the skin was incised from the ischial tuberosity down to the popliteal region. Biceps femoris muscles were identified and split longitudinally to expose the sciatic, tibial and peroneal nerves, and the anterolateral crural muscles were identified. Experimental procedures were carried out in 4 groups described as follows (Fig. 2).



**Fig. 1.** Anatomical dissection (left) and a schematic illustration (right) of the fully exposed sciatic nerve with its three major branches - the tibial nerve, peroneal nerve and the sural nerve - by biceps femoris muscle splitting incision.



**Fig. 2.** Schematic illustration of the experimental group. The experimental animals were divided into four groups; in the control group, the peroneal nerve was left untouched as a normal control, in the 1/4 neurotomy group, the posteromedial 1/4 of the peroneal nerve was transected, in the 1/2 neurotomy group, the posterior 1/2 of the peroneal nerve was transected, and in the 1/1 neurotomy group, the peroneal nerve was transected completely.

#### **Group 1: Control (n=30, left limb)**

Three and six months after neurotomy of the right limb, the animals were re-anesthetized with intraperitoneally administered 4% chloral hydrate (0.75 ml/100 gm body weight). Bilateral hind limbs and the gluteal region were depilated with Nair<sup>®</sup> and the bilateral skins incised from the ischial tuberosity down to the popliteal region. All left limbs were used as controls for the corresponding right limb measurements, including circumference and electromyography.

#### **Group 2: Posteromedial 1/4 of the peroneal nerve was severed (n=10, right limb)**

The peroneal nerve was transected 1cm distal to the bifurcation of the sciatic nerve, at its posteromedial one quarter.

#### **Group 3: Posteromedial 1/2 of the peroneal nerve was severed (n=10, right limb)**

The peroneal nerve was transected 1cm distal to the bifurcation of the sciatic nerve, at its posterior one half.

#### **Group 4: Total severance of the peroneal nerve (n=10, right limb)**

The peroneal nerve was transected completely, 1cm distal to its origin from the sciatic nerve.

The cut-ends were ligated with # 8.0 Nylon and buried in adjacent muscle.

Upon completion of the above procedures, skin closure was performed with 4-0 Nylon. Rats were caged independently to protect them from mutual mutilation, and fed dried pellets and water ad libitum.<sup>6</sup>

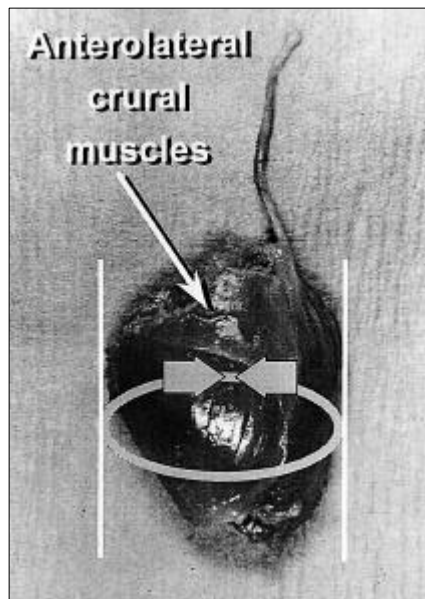
Three and 6 months after the procedures, 5 rats were randomly selected from each group and subjected to the following series of tests.

#### *Gross Movement and Electromyography*

Before anesthesia, gross movement of the right leg was observed. After anesthesia and dissection of the bilateral legs, the compound action potential and takeoff latency of the anterolateral muscle in each group were obtained by stimulating the bilateral peroneal nerves proximally. Left side measurements were used as controls, as mentioned before. All measurements were made in triplicate and averaged.

#### *Maximal Circumference and Weight of the Anterolateral Muscle Group*

After electromyographic study, the anterolateral crural muscle groups were isolated, and their maximal circumferences and weights were recorded (Fig. 3).



**Fig. 3.** Diagram showing the measurement of the largest muscle perimeter for assessing the degree of gross muscle atrophy. The perimeter was measured on a horizontal plane perpendicular to the limb axis.

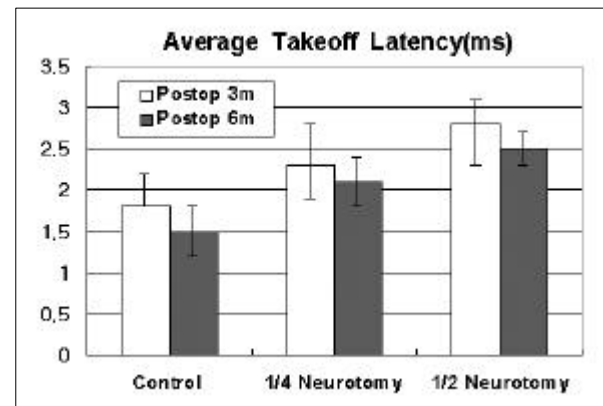
#### *Histologic and Morphometric Analysis of the Anterolateral Crural Muscles*

Muscle specimens were H & E stained and sectioned, slides were photographed under light microscopy ( $\times 200$ ) with a micrometer background. The images so obtained were analyzed using an IMAGE-PRO (Media Cybernetics, Silver Springs, MD, USA). After spatial calibration, the total number and diameter-sums of muscle fibers within an area of  $1\text{ mm}^2$  were measured and recorded to construct a histogram. Comparative analysis was then performed between the experimental groups. The fiber diameters were measured along the shortest axis of each fiber; diagonally cross-sectioned fibers at the peripheral zones or those displaying morphologic distortions, were excluded from the measurements.

The histologic characteristics of each denervated muscle was also documented.

#### **Statistical Analysis**

All variables are expressed as mean + standard deviation. The statistical significances of differences between groups and their appropriate controls were determined using the Student's *t* test.



**Fig. 4.** Average takeoff latency (ms). Average takeoff latency was significantly increased in the neurotomy group compared to those of controls 3 and 6 months after neurotomy ( $p < 0.001$ ). No recovery was observed during the follow up period of 6 months.

## **RESULTS**

### **Gross Movement and Electrophysiologic Measurements**

No definite abnormal gross movement of the hind legs was evident in the 1/4 and 1/2 neurotomy groups. In the total severance group, the extension of foot and proximal phalanges were impaired.

At 3 months, average takeoff latencies were increased to  $130 \pm 13\%$  and  $154 \pm 35\%$  of the controls in the 1/4 neurotomy and 1/2 neurotomy groups, respectively ( $p < 0.001$ ), and similarly at 6 months in the corresponding groups these were  $156 \pm 28\%$  and  $148 \pm 30\%$  of the controls ( $p < 0.001$ , Fig. 4).

At 3 months, the average peak-to-peak compound action potentials were  $72 \pm 12\%$  and  $59 \pm 7\%$  of the controls in the 1/4 neurotomy and 1/2 neurotomy groups ( $p < 0.001$ ), and at 6 months these became  $57 \pm 12\%$  and  $50 \pm 10\%$  of the controls in the same groups ( $p < 0.001$ , Fig. 5).

### **Maximal Circumference of the Anterolateral Crural Muscles**

Maximal circumference significantly decreased in the neurotomy groups at 3 months, and these were 86%, 71%, and 66% of the controls in the 1/4, 1/2 and 1/1 neurotomy groups, respectively

( $p < 0.001$ ), and after 6 months follow up this became 74%, 68% and 64% ( $p < 0.001$ ). At 6 months, the maximal circumferences of all control groups had increased relative to the appropriate 3-month groups (Table 1).

The observed circumference decrease was in proportion with the degree of denervation, up to maximal atrophy (Fig. 6).

### Weight Change of the Anterolateral Crural Muscles

Muscle weight was significantly decreased in

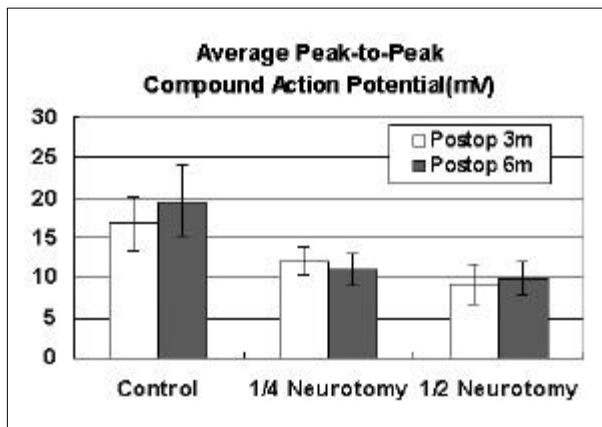


Fig. 5. Average peak-to-peak compound action potential (mV). Peak-to-peak compound action potential was significantly decreased in each neurotomy group 3 and 6 months after neurotomy compared to the corresponding controls ( $p < 0.001$ ). No significant change occurred during the follow up period of 6 months.

the neurotomy group at 3 months to  $76 \pm 8\%$ ,  $62 \pm 15\%$  and  $50 \pm 5\%$  of the control sides in the 1/4, 1/2 and 1/1 neurotomy groups respectively ( $p < 0.001$ ), and at 6 months this became  $70 \pm 12\%$ ,  $56 \pm 10\%$  and  $48 \pm 11\%$  of the control side ( $p < 0.001$ ) (Fig. 7). Muscle weight decreased in proportion to the degree of denervation, up to maximal atrophy (Fig. 6). At 6 months, the weights in all control groups were higher than those in all 3-month groups

### Histologic and Histomorphometric Studies

Histologic findings of the anterolateral crural muscle 6 months after neurotomy, showed healthier and larger fibers in the control group, whilst the 1/4 and 1/2 neurotomy groups showed small group atrophy and small angulated fibers, and the 1/1 neurotomy group showed pyknotic nuclear clustering and predominating small angular fiber distributions. The more extensive was the neurotomy, the greater was the number of small, angulated muscle fibers, a pathognomonic finding of denervation (Fig. 8).

Histograms were drawn showing the number of muscle fibers per  $\text{mm}^2$  in the muscle cross-section, and these showed a total number of  $239 \pm 52/\text{mm}^2$  in the control group, which were mainly medium to large in size. The more extensive was the neurotomy, the greater was the number of small angulated muscle fibers, which reached  $1,564 \pm 211$  per  $\text{mm}^2$  in the cross section of the 1/1 neurotomy group (Fig. 9).

Table 1. Changes in the Maximal Circumference of the Anterolateral Crural Muscles (mm)

3 Months Group	1/4 Neurotomy	1/2 Neurotomy	1/1 Neurotomy
Control	$49.5 \pm 4.0$	$50.5 \pm 4.3$	$48.1 \pm 4.4$
Operation Group	$49.5 \pm 4.0$	$49.5 \pm 4.0$	$49.5 \pm 4.0$
% Control	86%	71%	66%
$p^*$	$< 0.001$	$< 0.001$	$< 0.001$
6 Months Group	1/4 Neurotomy	1/2 Neurotomy	1/1 Neurotomy
Control	$69.1 \pm 5.1$	$60.8 \pm 3.4$	$63.3 \pm 3.2$
Operation Group	$46.1 \pm 3.7$	$41.2 \pm 4.4$	$40.4 \pm 4.5$
% Control	74%	68%	64%
$p^*$	$< 0.001$	$< 0.001$	$< 0.001$
$p^\dagger$	$< 0.05$	$p=0.08$	$< 0.005$

\*values between operation groups and corresponding control groups.

$^\dagger$  values between the 3 month and 6 month follow up groups.

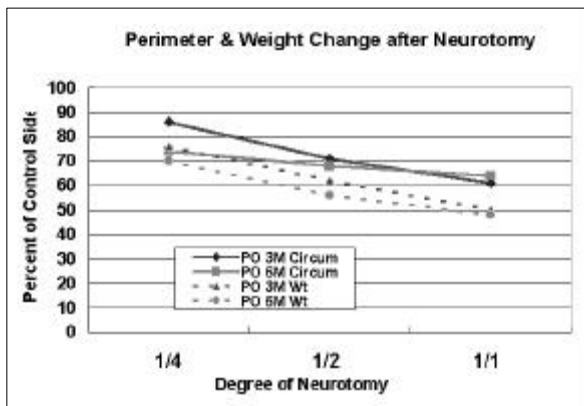


Fig. 6. Circumference and Weight Change after Neurotomy. Circumference and weight decreased in accord with the degree of denervation up to maximal atrophy.

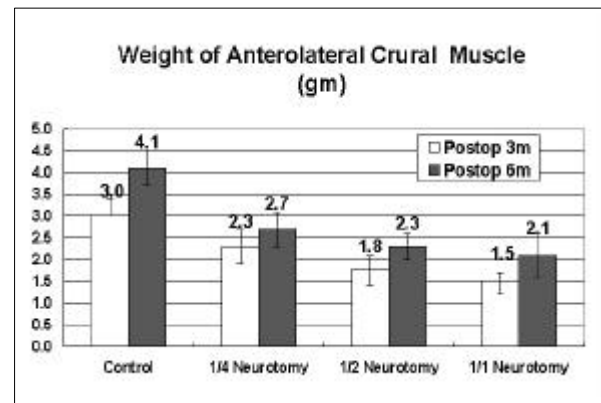


Fig. 7. Changes in the weight of the anterolateral crural muscle (gm). The average weight of the muscle was significantly lower in the neurotomy group at 3 and 6 months after neurotomy than in the corresponding controls ( $p < 0.05$ ). The slight increase in the 6 month group is considered to be due to normal muscular growth.

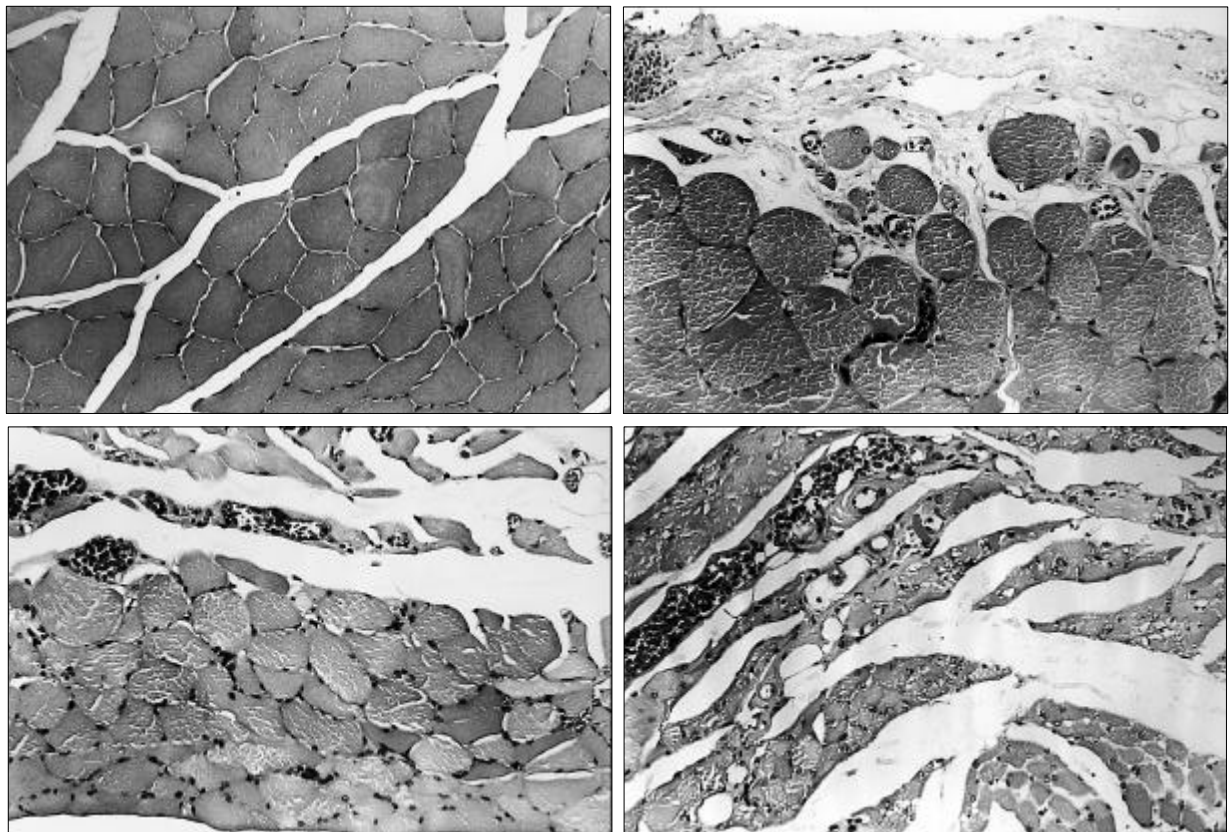


Fig. 8. Histologic findings of the anterolateral crural muscle 6 months after neurotomy. The control group (above left) showed healthier and larger fibers. The 1/4 neurotomy (above right) and 1/2 neurotomy groups (below left) showed small group atrophy and small angulated fibers. In the 1/1 neurotomy group (below right) pyknotic nuclear clustering was apparent and small angulated fibers were predominantly distributed. The number of small angulated fibers increased as the neurotomy became more extensive.

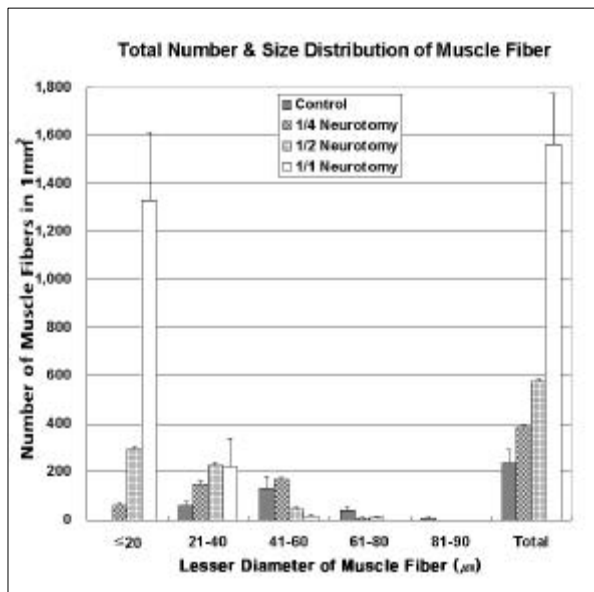


Fig. 9. Histogram of the total number and distribution of muscle fibers according to their diameters in cross sectional specimen of 1 mm<sup>2</sup> at 6 months follow up. In the control group the total number of muscle fibers was 239  $\pm$  52/mm<sup>2</sup>. The number of small angulated muscle fibers increased with increasing neurotomy, to a total of 1,564  $\pm$  211/mm<sup>2</sup>.

## DISCUSSION

Lipectomy and liposuction are effective methods of correcting excessive hypertrophy of adipose tissue in some patients. However, there are several associated complications, such as, irregular skin surface, long-lasting edema, and fibrosis. Moreover, effective correction of muscular hypertrophy is difficult to achieve.<sup>3,4,7</sup>

The purpose of this study was to develop a safe technique for effectively reducing muscle volume, by controlled the denervation of a selected muscle group without adversely affecting the motor functions, using a newly developed rat model.

When a motor nerve is severed or injured, its corresponding muscle group undergoes a gradual process of atrophy, and eventually is replaced by fibrous tissue. The extent of atrophy of the muscle group depends on the type and the degree of nerve injury.<sup>6,7</sup>

The molecular and cellular events of Wallerian degeneration have been extensively reviewed.<sup>7-9</sup> This process clears the distal stump of axoplasm and myelin, and thus prepares the way for sub-

sequent axon regeneration. Wallerian degeneration is initiated by the ingrowth of macrophages, triggering Schwann cell proliferation, which reaches a peak 3 days after nerve transection and continues for 2 weeks.

The time course of denervation changes within muscles and its consequences for functional recovery have been studied in both experimental animals and humans. Sunderland and Ray<sup>10</sup> found that denervated opossum muscle loses 50 to 60 percent of its weight at 60 days, by which time the average fiber cross-sectional area is reduced by 70 percent. Fibroblastic proliferation then reaches a peak at 89 days and results in the deposition of collagen, initially in the perimysium and later in the endomysium.

In human biopsy studies, significant fibrosis was found as early as 3 months<sup>11</sup> post-injury and this progressed in proportion to the total duration of denervation. The majority of muscle fibers had undergone moderate or severe atrophy at 3 months, and moderate to severe fibrosis was usually present after 11 months. In addition, a wide range of variation was found to exist among individuals. Bowden and Gutmann<sup>12</sup> performed 140 muscle biopsies on the patients of Sir Herbert Seddon. During the first 3 years of denervation they found progressive atrophy and fibrosis, and beyond 3 years they found progressive fragmentation and disintegration of muscle fibers, and their gradual replacement by fibrous tissue.

The present study demonstrates that when muscle is denervated its circumference and weight decreases in proportionate to the degree of denervation, up to maximal atrophy, by 61% in circumference and 48% in weight, in this particular experimental model. Moreover, the degree of maximal atrophy is comparable to that of Sunderland and Ray's reports.<sup>10</sup>

Gutmann<sup>13</sup> attributed deficits of muscle function after up to 8 months of denervation, to the deficient maturation of nerve fibers or motor end plates, moreover after 8 months, muscle fiber atrophy became the most significant limiting factor. In recent experiments, mouse soleus muscle denervated for 7 months regained 87 percent of its normal contractile force after reinnervation,<sup>14</sup> indicating that the deterioration of the intramuscular nerve pathways, rather than muscle

atrophy, is the primary determinant of poor functional recovery after prolonged denervation.<sup>15</sup>

In describing his clinical experiences, Sunderland observed "complete or very good restoration of function" after muscle denervation of up to 12 months.<sup>16</sup> Brushart<sup>17</sup> concluded that ideal reinnervation can be expected after 1 to 3 months of denervation, functional reinnervation can be expected after 1 year, and no reinnervation can be expected after 3 years.

In the present study, no gross movement disturbance was found in the partial neurotomy groups. Meanwhile, takeoff latency was prolonged and compound action potential weakened, and this continued until 6 months after denervation. To determine an accurate long-term outcome of reinnervation and the consequent restoration of contractile function, longer-term follow-up in bigger animals or in a clinical setting is indicated. In addition, detailed functional evaluations based upon a cross sectional topical map of the denervation nerve using either the sciatic function index<sup>18</sup> or walking track analysis<sup>19-21</sup> is a prerequisite to the implementation of selective neurotomy clinically, for the purpose of debulking.

Denervation of the lower motor neurones is associated with a characteristic set of pathological changes in muscles. Muscle fiber shrinks in size, but there may be little change in the architecture of the fiber. Even the cross-striations of individual atrophic muscle fibers are preserved until late in the atrophic process. Nuclei very often assume a tigroid form and may be gathered into clumps, so that during the later stages of neurogenic atrophy clumps of pyknotic sarcolemmal nuclei may be seen along the course of a pre-existing fiber.

Since one motor nerve supplies many muscle fibers, denervation will result in atrophic fibers scattered at random in a biopsy. These atrophic fibers are often clustered into groups, and the number of fibers within these groups increases with the severity of denervation, until whole fascicles may be rendered atrophic. These denervated fibers have an angulated shape and appear compressed in the interstices between other larger fibers. The presence of clustered 'small groups' or 'large groups' of atrophic and angulated fibers, compressed in the interstices of other larger fibers are pathognomonic of denervation.<sup>22</sup>

It is notoriously difficult to judge the size of fibers in a muscle biopsy by simple inspection. Since such changes are of fundamental importance to the interpretation of muscle biopsies, an accurate method of quantification is obviously essential. To this end, the construction of histograms of muscle fiber size provides a method that is both reproducible and simple.<sup>23</sup>

We chose a method, which combines simplicity and speed with reasonable accuracy, and involves the measurement of the 'lesser fiber diameter', defined as the maximum diameter of the lesser aspect of the muscle fiber. This measurement is designed to overcome the distortion that occurs when a muscle fiber is cut obliquely, producing an oval appearance in the fiber. Unless the lesser diameter is measured, an erroneously large measurement will result, since it is the only measurement that is not altered by either obliquity of the section or the kinking of muscle fiber, which are two common occurrences in muscle biopsies. Using this measurement the total number of muscle fibers in the cross-section was determined to be  $239 \pm 52/\text{mm}^2$  in the control group. The more extensive is the neurotomy, the greater is the number of small angulated muscle fibers - a pathognomonic finding of denervation.

Although more investigations and clinical trials are needed, refined selective neurotomy can be conceived to be an effective method of treating patients with excessive and unwelcome muscle hypertrophy.

Together with the selective neurotomy of motor nerve, similar neurotomy modalities are being attempted as an aesthetic or therapeutic purpose. Lee et al.<sup>24</sup> reported clinically successful remission of axillary hyperhidrosis after thoracoscopic sympathetic neurotomy. Jahng et al.<sup>25</sup> induced NADPH diaphorase staining after cervical vagotomy in an experimental study. These new modalities will expand their clinical implementation rapidly.

## REFERENCES

1. Gutmann E, Young JZ. The re-innervation of muscle after various period of atrophy. *J Anat* 1944;78:15-8.
2. Brooke MH, Kaiser KK. Muscle fiber types: How many and what kind? *Arch Neurol* 1970;23:369-79.



3. Watanabe K. Circumferential liposuction of calves and ankles. *Aesthetic Plast Surg* 1990;14:259-69.
4. Gottfried L, Klaus E. The resection of gastrocnemius muscles in aesthetically disturbing calf hypertrophy. *Plast Reconstr Surg* 1998;102:2230-6.
5. Greene EC. Anatomy of the rat. In: The American philosophical society, ed. *Transactions of the American Philosophical Society*, Vol. XXVII. New York: Hafner Publishing Co.; 1963.
6. Tark KC. Protection of abdominal flaps from self-mutilation in the rat. *Plast Reconstr Surg* 1989;84:376-7.
7. Lundborg G. Nerve regeneration & repair. A review. *Acta Orthop Scand* 1987;58:145-69.
8. Fawcett JW, Keynes RJ. Peripheral nerve regeneration. *Annu Rev Neurosci* 1990;13:43-60.
9. Scherer SS, Easter SS Jr. Degenerative and regenerative changes in the trochlear nerve of goldfish. *J Neurocytol* 1984;13:519-65.
10. Sunderland S, Ray LJ. Denervation changes in mammalian striated muscle. *Arch Neurol Neurosurg Psychiatry* 1950;13:159-77.
11. Aird RB, Naffziger HC. The pathology of human striated muscle following denervation. *J Neurosurg* 1953;10:216-27.
12. Bowden REM, Gutmann E. Denervation and reinnervation of human voluntary muscle. *Brain* 1944;67:273-313.
13. Gutmann E. Effect of delay of innervation on recovery of muscle after nerve lesions. *J Neurophysiol* 1948;11:279-94.
14. Irintchev A, Draguhn A, Wernig A. reinnervation and recovery of mouse soleus muscle after long-term denervation. *Neuroscience* 1990;39:231-43.
15. Fu SY, Gordon T. Contributing factors to poor functional recovery after delayed nerve repair: Prolonged denervation. *J Neurosci* 1995;15:3886-95.
16. Sunderland S. Capacity of reinnervated muscles to function efficiently after prolonged denervation. *Arch Neurol Psychiatry* 1950;64:755-71.
17. Brushart TM. Nerve repair and grafting. In: Green DP, Hotchkiss RN, Peterson WC, editors. *Green's Operative hand Surgery*. 4th ed. Philadelphia: Churchill Livingstone; 1999. vol 2, p.1381-403.
18. Kanaya F, Firrell JC, Breidenbach WC. Sciatic function index, nerve conduction tests, muscle contraction, and axon Morphometry as indicators of regeneration. *Plast Reconstr Surg* 1996;98:1264-74.
19. Bain JR, Mackinnon SE, Hunter DA. Functional evaluation of complete sciatic, peroneal, and posterior tibial nerve lesions in the rat. *Plast Reconstr Surg* 1989;83:129-36.
20. Dellon ES, Dellon AL. Functional assessment of neurologic impairment: Track analysis in diabetic and compression neuropathies. *Plast Reconstr Surg* 1991;88:686-94.
21. Dellon AL, Mackinnon SE. Sciatic nerve regeneration in the rat. Validity of walking track assessment in the presence of chronic contractures. *Microsurgery* 1989;10:220-5.
22. Dubowitz V. Disease of the lower motor neurone. In *Muscle Biopsy - A Practical Approach*. 2nd ed. London: Bailliere Tindall; 1985. p.223-5.
23. Dubowitz V. Disease of the lower motor neurone. In *Muscle Biopsy - A Practical Approach*. 2nd ed. London: Bailliere Tindall; 1985. p.86-9.
24. Lee DT, Hong YJ, Shin HK. Thoracoscopic sympathetic surgery for hyperhidrosis. *Yonsei Med J* 1999;40:589-95.
25. Jahng JW, Kim DG, Houpt TA. Subdiaphragmatic vagotomy induces NADPH diaphorase in the rat dorsal motor nucleus of the vagus. *Yonsei Med J* 2001;42:215-9.