

Clinicopathologic Study of Wegener's Granulomatosis with Special Emphasis on Early Lesions in 10 Korean Patients

Yong Beom Park¹, Jong Yoon Kim¹, John A Linton², Hyeon Joo Jung³, Soo Kon Lee¹,
and Dong Hwan Shin³

¹Division of Rheumatology, Departments of Internal Medicine, ²Family Medicine and ³Pathology,
Yonsei University College of Medicine, Seoul, Korea

We reviewed ten cases of Wegener's granulomatosis with special emphasis on the characteristics of the early stage of Wegener's granulomatosis. All patients presented with nonspecific symptoms and signs, so that Wegener's granulomatosis was not initially considered. However, half of the patients had clinical or radiologic disease in the nose/or paranasal sinuses as the primary presenting problems and showed neutrophil microabscess surrounded by palisading epithelioid cells and irregularly arranged giant cells in the nasal biopsy as the most characteristic feature.

Five of ten patients were believed to have a protracted superficial phenomenon before involvement of other organs, specifically the lung or kidney. Four of ten patients showed nonreactivity to ANCA test at the time of presentation. Although the number of cases reviewed in this study was small, the rate of nonreactivity to ANCA was higher than those of the larger series.

The importance of early diagnosis of Wegener's granulomatosis can not be overemphasized in view of the fact that cases unrecognized clinicopathologically finally progress to full-blown systemic form of Wegener's granulomatosis with poor prognosis. The diagnosis of Wegener's granulomatosis should be based on a thorough and meticulous examination of its characteristic histologic changes in biopsied tissue particularly extravascular foci.

Key Words: Wegener's granulomatosis, antineutrophil cytoplasmic antibody, nasal biopsy, early diagnosis, protracted superficial phenomenon

INTRODUCTION

Wegener's granulomatosis is an uncommon idiopathic, multisystem disease, typically involving the lung, upper airways and kidneys. It has been characterized by necrotizing granulomatous inflammation and vasculitis involving the respiratory tract, combined with a pauci-immune necrotizing inflammation affecting small to medium-sized vessels, which is commonly associated with necrotizing glomerulonephritis and antineutrophil cytoplasmic antibodies (ANCA).¹ The etiology of Wegener's granulomatosis remains unknown, though the disease occurs in any part of the world it tends to occur in Caucasians. A recent epidemiologic study estimated the prevalence of Wegener's granulomatosis in the United States at 3.0 per 100,000 persons.² In Korea, only few cases have been reported³⁻⁵ and clinicopathologic analysis of Wegener's granulomatosis patients has not been previously undertaken. It is not clear why Wegener's granulomatosis is seldom reported in Korea, and this may reflect a racial difference; more importantly, the disease might be undiagnosed because most surgical pathologists have rarely experienced the condition in Korea.

In this study we reviewed the clinical manifestations and pathologic findings of 10 cases with the clinicopathologic features characteristic of Wegener's granulomatosis and we paid special attention to the extended duration of mucosal lesions by reviewing the previous initial biopsies obtained when the disease was not suspected.

Received September 16, 2000
Accepted November 9, 2000

MATERIALS AND METHODS

We retrospectively reviewed the clinicopathologic records and biopsies of 10 Korean patients diagnosed as having Wegener's granulomatosis, six patients were seen at the Severance Hospital, Yonsei University Medical Center, Seoul, Korea, and the remainder as consultation cases of one of the authors (D.H.S.; 4 cases) between 1995 to 1999. Of these cases three treated at the Severance Hospital and Cha Hospital (Cases 1, 2, and 10) have been previously reported.³⁻⁵ Cases seen in consultation consisted of 3 nasal biopsies, one middle ear biopsy and open lung biopsy. All patients satisfy the ACR 1990 criteria for Wegener's granulomatosis.⁶

All patients underwent an evaluation that included history taking and a thorough physical examination. Laboratory tests included, white blood cell, hemoglobin, hematocrit, platelet, IgG, IgA, IgM, C-reactive protein (CRP), erythrocyte sedimentation rate (ESR, modified Westergren method), ANCA, anti-nuclear antibody (ANA), and rheumatoid factor (RF). Criteria for complete remission included the absence of evidence of active disease, complete resolution without signs of active inflammation, and the absence of systemic inflammatory disease.⁷

Initial biopsies were obtained from the organs affected at presentation and all were biopsied from nasal mucosa, with the exception of one biopsied from middle ear. Therefore, the pathologic material primarily reviewed consisted of 9 nasal and one middle ear biopsies. The size of the biopsy tissue ranged from 0.3 cm to as large as 1.7 cm but most were more than 0.5 cm in size. Twenty biopsy specimens were available, with several taken from the same patients. All were examined histologically with hematoxylin-eosin-stained slides. Most of the cases were studied with additional histochemical stains, including elastic tissue, trichrome, PAS, acid fast and methenamine silver. These special stains had been performed primarily to study blood vessels and exclude infection; fungal organisms and acid-fast bacilli were not identified. The cases were examined in terms of the type of necrosis and inflammation, the location of disease, separation into vascular and extravascular lesions, and associated reac-

tions. Slides of the lung and kidney biopsies were reviewed when available.

RESULTS

Clinical manifestations

All ten patients presented with nonspecific symptoms and signs which were not considered to be suggestive of Wegener's granulomatosis, but all were confirmed to have microscopic histopathology specific enough to warrant a diagnosis of Wegener's granulomatosis. The age range was 16 to 61 years with a median of 46 years, and the median duration from onset to diagnosis was 4 months (Table 1). The diagnosis of Wegener's granulomatosis was made within 7 months of symptom onset in nine patients, but in one patient the diagnosis was not made until 66 months later. This patient was believed to have had indolent progression of protracted disease which undoubtedly contributed to the diagnosis delay.

The signs and symptoms of Wegener's granulomatosis that were present at disease onset are shown in Table 1. Eight patients first sought medical attention because of upper or lower airway symptoms or both. Nasal, sinus, tracheal, or ear abnormalities were present in all patients at initial examination. In the absence of systemic illness, these problems were often considered to be secondary to allergy or infection. Symptomatic treatment, followed by persistent symptoms and complications, especially recurrent epistaxis, mucosal ulcerations, nasal septal perforation, or nasal deformity, led in some cases to more extensive evaluation. Findings of active urine sediment, pulmonary infiltrates of nodules, elevated erythrocyte sedimentation rates, unexplained anemia, and positive ANCA prompted definitive diagnosis by biopsy of the involved organs.

Pulmonary infiltrates, nodules, or both were initially present in 60% of the patients (Table 2). Symptoms included cough (40%) and hemoptysis (20%).

Seven patients (70%) presented with features of glomerulonephritis; one patient later developed glomerulonephritis at 6 years after disease onset.

Ocular abnormalities were noted in 40% of

Table 1. Initial Manifestations of Patients

Indices \ Case	1	2	3	4	5	6	7	8	9	10
Sex	M	F	M	M	F	F	M	M	F	M
Age	46	34	16	59	46	56	61	56	60	39
Duration (months) [†]	1	66	3	1	7	6	1	1	4	4
Fever	+	-	+	-	-	-	-	-	+	-
Headache	+	-	-	+	+	-	+	+	+	-
Weight loss	+	-	-	-	-	-	-	-	-	+
Rhinitis	+	+	+	+	-	+	+	-	-	-
Epistaxis	+	+	-	+	+	-	-	-	-	-
Sinusitis	+	+	+	+	+	+	-	-	+	-
Proptosis	-	-	-	+	-	+	-	+	-	-
Otitis	-	-	-	-	+	-	-	-	+	+
Hearing loss	-	-	-	-	+	-	-	-	+	-
Cough	+	-	+	-	-	-	-	-	+	+
Hemoptysis	+	-	-	-	-	-	-	-	+	-
Skin rash	+	+	+	+	-	-	-	-	+	-
Arthralgia	-	+	-	+	-	-	-	-	+	-
Serositis	-	-	-	-	-	-	-	-	+	-

M, male; F, female.

[†]duration from the first symptom or sign onset to diagnosis.

+presence of symptom or sign.

-absence of symptom or sign.

Table 2. Organ Involvement of Wegeners Granulomatosis Patients

Organ \ Case	1	2	3	4	5	6	7	8	9	10
Paranasal sinus	+	+	+	+	+	+	-	+	+	-
Nose/Nasopharynx	+	+	+	+	+	+	+	+	-	-
Ear	-	-	-	-	+	-	-	-	+	+
Eye	-	-	-	-	-	+	-	+	+	-
Lung	+	-	+	-	+	-	+	-	+	+
Kidney	+	+	+	+	+	+	-	-	+	-
Skin	+	+	+	+	-	-	-	-	+	-
Nervous system	+	-	-	-	-	-	-	-	-	+
Type [†]	1	3	1	1	2	1	2	2	1	2
Morbidity	Gangrene foot		Nasal deformity		Hearing loss	Subglottic stenosis	Subglottic stenosis	Nasal deformity	Death	Deafness

+presence of involvement.

-absence of involvement.

* thin basement membrane disease.

[†]1 generalized type, 2: limited type, 3: limited type for 6 years + generalized type.

patients during the early phases of Wegener's granulomatosis and most cases produced signifi-

cant symptoms. The most diagnostically helpful finding was proptosis, which, when present in the

setting of upper or lower airway disease or glomerulonephritis, was strongly suggestive of Wegener's granulomatosis. Painful proptosis was present in three patients at disease onset. No patient with retro-orbital pseudotumors lost vision, but entrapment of extraocular muscles also led to conjugate gaze loss that caused diplopia.

Arthralgia was a feature of disease in only 30% of patients. Fever due to Wegener's granulomatosis was initially present in 30% of patients. In all cases, the presence of fever prompted an evaluation for secondary infection. Significant weight loss, defined as a loss greater than 10% of usual body weight, occurred in 20% of patients at disease onset. When weight loss was present initially in conjunction with persistent fever, patients had frequently been evaluated for occult malignancy.

Skin disease occurred in 50% of patients initially. Lesions included palpable purpura, ulcers, vesicles, papules, and subcutaneous nodules.

Nervous system involvement was suspected in two patients at initial presentation; mononeuritis multiplex and facial palsy developed respectively.

Laboratory data

Sera from all patients were tested using indirect immunofluorescence for the presence of ANCA. Leukocytes from normal controls were placed on glass slides and fixed in 95% ethanol. Sera from six patients with active Wegener's granulomatosis produced diffuse granular cytoplasmic (c-ANCA) immunofluorescent staining of neutrophils, but no serum sample produced perinuclear (P-ANCA) immunofluorescent staining. ANA was negative in all patients but RF was positive in 40%.

Before starting therapy, patients with active Wegener's granulomatosis often had leukocytosis (median leukocyte count, $7.8 \times 10^9/L$; range, 3.9 to $22.3 \times 10^9/L$). Anemia occurred in four patients and was usually normocytic or normochromic. The median hematocrit was 35.5, and median hemoglobin was 12.0 g/dL. The median platelet count was $282 \times 10^9/L$. Thrombocytosis (platelets, $>400 \times 10^9/L$) occurred in one patient with active disease. Thrombocytopenia was not noted in any patient. ESR and CRP elevated with disease activity in all patients (median, 66 mm/h;

range, 33 to 135 mm/h; 8.0 mg/dL; range, 1.45 to 29.4, respectively). Serum levels of IgG, IgM, and IgA were within the normal range.

Histopathologic features

The most common biopsy site for diagnosis was the nasal mucosa, followed by the kidney, lung and middle ear. The first initial nasal biopsy was considered to show a histopathology which was not specific enough to warrant a diagnosis of Wegener's granulomatosis causing repeat biopsy in three cases.

The characteristic and consistent finding in positive biopsy specimens was mucosal ulceration, mixed acute and chronic inflammation, ill-defined granulomatous reaction surrounding necrosis and less often vasculitis of small vessels in the affected nasal mucosa and middle ear tissue. The mixed acute and chronic inflammation was associated with neutrophils often aggregating into small clusters and forming microabscesses (Table 3). Diffuse granulomatous reaction was present as sheets of epithelioid histiocytes, including multinucleated giant cells associated with lymphocytes (Fig. 1). Multinucleated giant cells were scattered diffusely in the granulomatous tissue, as well as among the peripheral cells of the palisading granuloma. Palisading microgranuloma with central focus of neutrophils and necrotic collagen surrounded by histiocytes and giant cells were also observed (Fig. 2). These lesions were all extravascular but similar changes were observed in the vessels, including fibrinoid degeneration of vessel walls and granulomatous vasculitis in four nasal biopsy specimens (Fig. 3). In the 10 cases studied, extravascular lesions predominated in the nasal biopsy specimens and vascular

Table 3. Pathologic Findings of 20 Nasal and Middle Ear Biopsy Specimens

Stromal inflammation	20/20 (100%)
Giant cells	18/20 (90%)
Ulcer	17/20 (85%)
Necrosis(Microabscess)	17/20 (85%)
Non-granulomatous vasculitis	16/20 (80%)
Eosinophils	12/20 (60%)
Granulomatous vasculitis	7/20 (35%)
Extravascular necrotic foci	6/20 (30%)

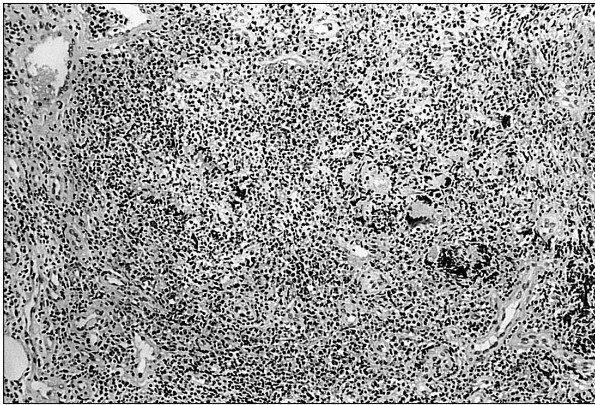

Fig. 1. Diffuse granulomatous inflammation of nasal mucosa. Note irregularly arranged multinucleated giant cells among lymphocytes, histiocytes, and neutrophils (H&E, $\times 100$).

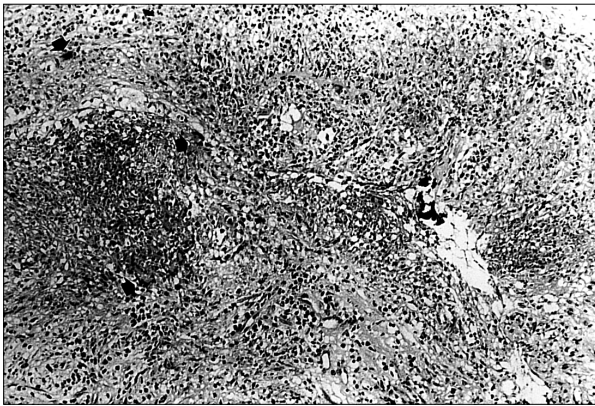


Fig. 2. Granulomatous inflammation and fibrinoid degeneration in middle ear tissue. A small vessel is infiltrated and partially obliterated by dense lymphohistiocytic infiltrate and multinucleated giant cells (arrows) and fibrinoid degeneration (H&E, $\times 100$).

lesions were absent in three of them. Plasma cells were numerous and most cases showed appreciable numbers of eosinophils, sometimes as many as seen in allergic polyp. The inflammatory reaction may overshadow both necrosis and vasculitis so that we could hardly find a small circumscribed focus of collagen necrosis histologically described as granular necrosis without peripheral palisading cells, which was stressed to be one of the earliest types of mucosal lesion in Wegener's granulomatosis.

Renal biopsies revealed changes of focal glomerulonephritis in five cases, and granulomatous glomerulonephritis was absent. Thin basement membrane disease was diagnosed in one patient.

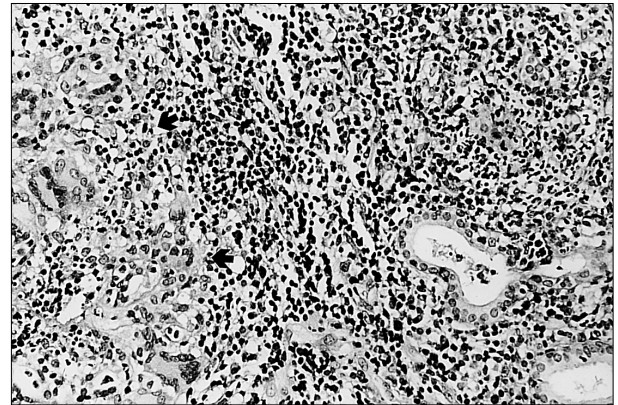


Fig. 3. Extravascular palisading microgranuloma (arrows) with central aggregate of neutrophils in the middle ear tissue (H&E, $\times 200$).

Skin biopsies were all abnormal although only one of 5 biopsies showed features strongly suggestive of Wegener's granulomatosis. The others showed nonspecific histopathologic changes.

Finally, no compact granuloma similar to those seen in tuberculosis or sarcoidosis was found in any case.

Clinical Outcome

Eight patients were treated with standard therapy (glucocorticoid and daily cyclophosphamide), two patients with glucocorticoid and methotrexate, and two patients with standard therapy plus sulfamethoxazole/trimethoprim. Treatment resulted in a marked improvement in all patients and complete remission in 70% of patients. Although some patients achieved complete remission within a few months, the median time for all patients receiving therapy to achieve remission was 5 months. Only one patient that achieved complete remission experienced relapse, which occurred 4 years after achieving remission.

Permanent disease-related morbidity occurred in five patients and included hearing loss (1 patient), cosmetic and functional nasal deformities (2 patients), tracheal stenosis (2 patients), and gangrene due to vasculitis (1 patient). Half of the patients experienced more than one permanent type of morbidity. No renal insufficiency was observed in our patients.

Hearing impairment was related to recurrent otitis media or sensori-neural impairment. Three

patients experienced recurrent otitis media and only one patient had partial unilateral hearing loss.

Nasal deformity did not occur in patients without concurrent chronic sinus disease. The emotional impact of nasal deformity is usually substantial. Concern about relapsing disease, however, led to restraint in carrying out nasal cosmetic surgery.

The tracheobronchial tree is one of the locations which Wegener's granulomatosis can cause irreversible damage. Two patients had tracheal stenosis, and the most common symptom was shortness of breath. In both of these patients, subglottic tracheal stenosis was irreversible. Symptoms and findings in one patient were modest and resolved during the course of treatment, but in the other patient tracheal stenosis was severe enough to necessitate laser dilatation.

Two patients experienced 2 occasions of serious infections, which was defined as requiring hospitalization and the administration of intravenous antibiotics. They included pneumonias due to *Pneumocystis carinii* and *Streptococcus pneumoniae*. *Pneumocystis* infection occurred in one patient during the period of daily glucocorticoid and cytoxan therapy, and she consequently died from *Pneumocystis carinii* pneumonia.

DISCUSSION

Wegener's granulomatosis is so rare that only a few cases have been reported in Korea.³⁻⁵ This study is the first comprehensive analysis of the clinical data of Korean patients with Wegener's granulomatosis. In this study, we gained a greater understanding of the disease. Only six of our patients had positive C-ANCA in the active stage, and this percentage of positive ANCA is lower than other reports in the active stage.⁷⁻⁹ It is not certain whether the finding is ascribable to either racial difference or to the small population studied. ANCA was first described in 1982¹⁰ and found to be highly associated with active Wegener's granulomatosis. ANCA has two main immunofluorescent staining patterns, which are described as a cytoplasmic pattern (c-ANCA) and a perinuclear pattern (p-ANCA). C-ANCA has

been found in 70-90% of patients with active Wegener's granulomatosis, and its target antigen is proteinase-3, a 29 kD serine protease found in the azurophilic granules of neutrophils.¹¹ P-ANCA has a wider range of disease association and antigen specificities but has been observed in 5-10% of patients with Wegener's granulomatosis where it is usually directed against myeloperoxidase, another constituent of neutrophil granules.^{12,13} The sensitivity of ANCA for Wegener's granulomatosis has been reported to range between 28% and 92%.⁹ This broad spectrum partly reflects the different criteria that were applied to establish the diagnosis of Wegener's granulomatosis. Several series have demonstrated a high specificity of c-ANCA for Wegener's granulomatosis, ranging from 80% to 100%. This high degree of sensitivity and specificity of c-ANCA for Wegener's granulomatosis has raised interest as to whether it may be used as a means of diagnosis. Despite these findings, the usefulness of ANCA as a diagnostic test is also influenced by the pre-test probability of disease, which will be low in most clinical situations, given the uncommon nature of Wegener's granulomatosis. Positive ANCA test results have also been reported to occur in other diseases that are part of the differential diagnosis of Wegener's granulomatosis.^{13,14} Thus, while a positive c-ANCA test result may be useful in suggesting the possibility of Wegener's granulomatosis, it should not normally be used in lieu of biopsy to make the diagnosis.¹⁵ While ANCA titers reflect overall disease activity, no correlation with endobronchial inflammatory activity was apparent.¹⁶

The diagnosis of Wegener's granulomatosis is usually established by the histological demonstration of vasculitis, granulomatous inflammation, and necrosis in a clinically appropriate setting. These histological features are often patchy in distribution, and the likelihood of obtaining a positive biopsy result is influenced by the organ site, and particularly, the size of the biopsy.¹⁷⁻¹⁹

Clinical manifestations and laboratory findings in our patients were somewhat different to those of other reports.^{7,8} Joint pain (30%) was less frequent in our patients than in other series (44%) at the time of presentation, whereas ocular

abnormalities (40%) and skin involvement (50%) were more frequent (15% and 13%, respectively).

In laboratory findings, thrombocytosis and leukocytosis were rarer than in other series.^{7,8} The test for ANA was negative in all patients and the positivity for RF was 40%. In other series, ANA was infrequently detected and the positivity of RF was reported to be approximately 60%.^{7,8} No laboratory findings were diagnostic of Wegener's granulomatosis although there were helpful for diagnosis.

Wegener's granulomatosis relapsed after disease remission in only one patient. Our Korean patients were thought to be very responsive to treatment. Most patients took the standard regimen (daily high dose of prednisolone and oral cyclophosphamide). But, two patients took methotrexate instead of cyclophosphamide. They both had microscopic hematuria, which was suspected to reflect the bladder toxicity of cyclophosphamide in one patient and in the other was attributed to thin basement membrane disease of kidney. A retrospective report underscored the considerable prognostic significance of renal involvement in patients with Wegener's granulomatosis.²⁰ The difficulty of differentiating the cause of the hematuria as bladder toxicity of cyclophosphamide or an underlying disease prompted us to choose methotrexate. Recently methotrexate has been increasingly used in patients with cyclophosphamide toxicity and are in relatively non-life threatening condition.^{21,22} The efficiency of methotrexate was reported to be comparable to conventional oral cyclophosphamide under non-life threatening condition.

Most interestingly, five of the ten patients we studied were considered to have a limited type of Wegener's granulomatosis at the time of the initial presentation with protracted superficial phenomenon. The reason for relatively high rate of limited type at the time of diagnosis in our patients was thought to be mainly due to early detection of disease. However, one patient was not diagnosed to have active full-blown Wegener's granulomatosis until more than 6 years had passed before the first symptom ascribed to Wegener's granulomatosis. Unusually indolent progression of disease in patient caused delay in diagnosis justifying the protracted superficial

phenomenon in Wegener's granulomatosis such that the case was previously reported.³

Whereas the early descriptions of the disease were based on autopsy series reflecting the fatal outcome of untreated disease, it is now well recognized that Wegener's granulomatosis can involve essentially any organ system, and that symptoms may be limited to one or two organ systems, and in particular, the upper and/or lower respiratory tract over very extended periods of time. Such protracted phenomena in Wegener's granulomatosis were defined as ulcerated necrotizing lesions of the mucosa and skin, which remain localized for months and years in untreated cases. The sites of involvement are usually the nose, nasopharynx, paranasal sinuses, middle ears, laryngeal area, and various areas of the skin, particularly of the face.²³ Its long duration as a localized lesion provides time enough to perform a biopsy, and provide a histologic diagnosis. Furthermore, it allows the administration of cytotoxic therapy before other organs are affected or intractable renal failure occurs.²⁴

The recognition of all facets of the clinical spectrum of Wegener's granulomatosis is essential to ensure early therapy that may prevent irreversible organ damage. Histopathologically diffuse granulomatous tissue was a frequent finding and suggestive of Wegener's granulomatosis, but difficult to assess if observed in the absence of palisading granuloma or palisading histiocytes.²⁵ Although not specific, the presence of scattered multinucleated giant cells in small sized samples may serve as a helpful diagnostic clue in the absence of a vasculitis or clearcut granulomatous inflammation.¹⁹

The major differential diagnoses especially in the nasal biopsies include angiocentric immunoproliferative lesions, allergic angiitis and granulomatosis, and most importantly granulomatous infection.¹⁷ Wegener's granulomatosis may be confused with angiocentric malignant lymphomas but in contrast to Wegener's granulomatosis, the proliferating lymphoid cells of angiocentric malignant lymphomas demonstrate cytologic atypia. When striking eosinophilia is present allergic angiitis and granulomatosis (Churg-Strauss syndrome) should be strongly considered, and the distinction should be based mainly on clinical

grounds. The necrotizing granulomas and vasculitis of Wegener's granulomatosis may be mimicked by granulomatous infection. Therefore, it is very important to exclude it by using special stains and culture. In fact, compact granulomas typical of sarcoid and mycobacterial infection are only rarely encountered in Wegener's granulomatosis.^{17,18}

The concept has long been held that Wegener's granulomatosis is primarily a vasculitis, however, Wegener's granulomatosis is more than a vasculitis, it is a vasculitis and a necrotizing granulomatosis.^{23,24,26} Recent studies have reemphasized this fact.^{17,19,23,25,27} Vessels are independent contemporaneous target tissues, and extravascular and vascular lesions appear in various combinations. Should vascular lesions be minimal or absent, the diagnosis must depend on the recognition of the extravascular lesions. With the advent of cyclophosphamide therapy the urgency to establish the diagnosis and avoid focal necrotizing glomerulonephritis is obvious and the diagnosis must often be made on the basis of biopsy specimens containing only extravascular lesions.

In summary, the clinician must be aware of the possibility of Wegener's granulomatosis while the lesion remains localized and small, and the pathologist must rely on histologic details, such as, in particular the palisading granuloma, foci of extravascular granular necrosis, fibrinoid degeneration, and vasculitis of both fibrinoid degeneration and granulomatous types, and the absence of sarcoid-type compact granuloma. Even in the absence of vasculitis, however, the extravascular granulomatous features are considered characteristic and especially applicable to biopsies from the head and neck, which are often small and lack good-sized vessels, making the recognition of the nonvasculitic pathologic features of Wegener's granulomatosis even more important.

Dong Hwan Shin, M.D.

*Department of Pathology, Yonsei University
College of Medicine, C.P.O. BOX 8044, Seoul
120-752, Korea,*

Tel: 82-2-361-5240, Fax: 82-2-362-0860,

E-mail: shindh417@yumc.yonsei.ac.kr

REFERENCES

1. Valente RM, Hall S, O'Duffy JD, Conn DL. Vasculitis and related disorders. In: Kelley WN, Harris ED, Ruddy S, Sledge CB, editors. *Textbook of Rheumatology*. 5th ed. Philadelphia: W.B. Saunders; 1997. p.1099-103.
2. Cotch MF, Hoffman GS, Yerg DE, Kaufman GL, Targonski P, Kaslow RA. The epidemiology of Wegener's granulomatosis. *Arthritis Rheum* 1996;39: 87-92.
3. Lee CH, Lee JY, Song JH, Lee J, Park CS, Lee SK, et al. A case of protracted Wegener's granulomatosis which is progress to generalized form. *Korean J Med* 1997;52:559-64.
4. Lee SH, Yang DG, Cho HM, Song KH, Park JM, Yoo JS, et al. A case of Wegener's granulomatosis with obstruction of both anterior tibial and peroneal arteries. *Tuberculosis Resp Dis* 1996;43:779-85.
5. Kwon KW, Choi YJ, Ahn HJ, Han MS, Shin DH. Wegener's granulomatosis involving lung and middle ear. *Korean J Pathol* 1998;32:470-3.
6. Leavitt RY, Fauci AS, Bloch DA, Michel BA, Hunder GG, Arend WP, et al. The American College of Rheumatology 1990 Criteria for the classification of Wegener's granulomatosis. *Arthritis Rheum* 1990;33: 1101-7.
7. Hoffman GS, Kerr GS, Leavitt RY, Hallahan CW, Lebovics RS, Travis WD, et al. Wegener's granulomatosis: An analysis of 158 patients. *Ann Intern Med* 1992;116:488-98.
8. Fauci AS, Haynes BF, Katz P, Wolff SM. Wegener's granulomatosis: prospective clinical and therapeutic experience with 85 patients for 21 years. *Ann Intern Med* 1983;98:76-85.
9. Nolle B, Specks U, Ludemann J, Rohrback MS, DeRemee RA, Gross WL. Anticytoplasmic autoantibodies: their immunodiagnostic value in Wegener's granulomatosis. *Ann Intern Med* 1989;111:28-40.
10. Davies DJ, Moran JE, Niall JF, Ryan GB. Segmental necrotising glomerulonephritis with antineutrophil antibody: possible arbovirus aetiology. *BMJ* 1982;285: 606.
11. Niles JL, McCluskey RT, Ahmad MF, Arnaout MA. Wegener's granulomatosis autoantigen is a novel neutrophil serine proteinase. *Blood* 1989;74:1888-93.
12. Falk RJ, Jennette JC. Anti-neutrophil cytoplasmic autoantibodies with specificity for myeloperoxidase in patients with systemic vasculitis and idiopathic necrotizing and crescentic glomerulonephritis. *N Engl J Med* 1988;318:1651-7.
13. Gross W. Anti-neutrophil cytoplasmic autoantibody testing in vasculitides. *Rheum Dis Clin North Am* 1995; 4:987-1011.
14. Davenport A. False positive perinuclear and cytoplasmic anti-neutrophil cytoplasmic autoantibody results leading to misdiagnosis of Wegener's granulomatosis

- and/or microscopic polyarteritis. *Clin Nephrol* 1992;37:124-30.
15. Langford CA. The diagnostic utility of c-ANCA in Wegener's granulomatosis. *Clev Clin J Med* 1998;65:135-40.
 16. Daum TE, Specks U, Colby TV, Edell ES, Brutinel MW, Prakash UBS, et al. Tracheobronchial involvement in Wegener's granulomatosis. *Am J Resp Crit Care Med* 1995;151:522-6.
 17. Devaney KO, Travis WD, Hoffman GS, Leavitt R, Lebovics R, Fauci AS. Interpretation of head and neck biopsies in Wegener's granulomatosis. A pathologic study of 126 biopsies in 70 patients. *Am J Surg Pathol* 1990;14:555-64.
 18. Travis WD, Hoffman GS, Leavitt RY, Pass HI, Fauci AS. Surgical pathology of the lung in Wegener's granulomatosis. Review of 87 open lung biopsies from 67 patients. *Am J Surg Pathol* 1991;15:315-33.
 19. Del Buono EA, Flint A. Diagnostic Usefulness of Nasal Biopsy in Wegener's Granulomatosis. *Hum Pathol* 1991;22:107-10.
 20. Briedigkeit L, Kettritz R, Gobel U, Natusch R. Prognostic factors in Wegener's granulomatosis. *Postgrad Med J* 1993;69:856-61.
 21. Hoffman GS, Leavitt RY, Kerr GS, Fauci AS. The treatment of Wegener's granulomatosis with glucocorticoid and methotrexate. *Arthritis Rheum* 1992;35:1322-9.
 22. Sneller MC, Hoffman GS, Talar-Wiliams C, Kerr GS, Hallahan CW, Fauci AS. An analysis of forty-two Wegener's granulomatosis patients treated with methotrexate and prednisolone. *Arthritis Rheum* 1995;38:608-13.
 23. Fienberg R. The protracted superficial phenomenon in Pathergic (Wegener's) granulomatosis. *Hum Pathol* 1981;12:458-67.
 24. Fienberg R. A Morphologic and Immunohistologic Study of the Evolution of the Necrotizing Palisading Granuloma of Pathergic (Wegener's) Granulomatosis. *Semin Resp Med* 1989;10:126-32.
 25. Mark EJ, Matsubara O, Tan-Liu NS, Fienberg R. The Pulmonary Biopsy in the Early Diagnosis of Wegener's (Pathergic) Granulomatosis: A Study Based on 35 Open Lung Biopsies. *Hum Pathol* 1988;19:1065-71.
 26. Colby TV, Tazelaar HD, Specks U, DeRemee RA. Editorial: Nasal Biopsy in Wegener's Granulomatosis. *Hum Pathol* 1991;22:101-4.
 27. Lombard CM, Duncan SR, Rizk NR, Colby TV. The Diagnosis of Wegener's Granulomatosis From Transbronchial Biopsy Specimens. *Hum Pathol* 1990;21:838-42.