

Radiologic Laryngeal Parameters in Acute Supraglottitis in Korean Adults

Man-Gang Yong¹, Moo-Jin Choo¹, Chang-Seop Yum¹, Seong-Bok Cho¹, See-Ok Shin¹,
Dong Wook Lee¹, Sung-Jin Kim², and Ju-Chang Kim²

Departments of ¹Otolaryngology and ²Diagnostic Radiology, College of Medicine, Chungbuk National University, Cheongju, Korea.

Soft-tissue lateral neck radiography is important for diagnosing acute supraglottitis. This study aimed to determine the objective criteria for a diagnosis of acute supraglottitis from soft-tissue lateral neck radiographs in Korean adults. The parameters in 30 adult patients with acute supraglottitis were compared with those of age- and sex-matched normal 30 Korean adults. The mean of epiglottis width (EW) and aryepiglottic fold width (AEW) in the control group were 4.37 ± 0.93 mm, 2.45 ± 0.71 mm, respectively and in the patient group they were 15.87 ± 3.60 mm, 6.4 ± 2.55 mm, respectively. The sensitivity and specificity of an EW greater than 7mm were 100%, and 100% respectively. The sensitivity and specificity of an AEW greater than 4.5 mm were 83%, and 100% respectively.

Key Words: Supraglottitis, epiglottis width, aryepiglottic fold width, parameter

INTRODUCTION

Acute supraglottitis, so called epiglottitis, is an infection of the supraglottic structures that can obstruct the airway. Direct visualization with nasopharyngolaryngoscopy or indirect laryngoscopy remains the standard in diagnosing supraglottitis. Soft-tissue lateral neck radiography has been thought to be useful in diagnosing acute supraglottitis. Soft-tissue films are often used as a screening procedure before direct visualization

when supraglottitis is suspected in a stable condition. The diagnostic criteria of supraglottitis on soft-tissue films should be strict because a nasopharyngolaryngoscopy or an indirect laryngoscopy requires special training and expertise. However, the radiologic parameters for acute supraglottitis in Korean adults have not been reported. The reported radiologic signs of supraglottitis are subjective.¹⁻⁴ The purpose of this study was to obtain the objective criteria for diagnosing acute supraglottitis in adults on soft-tissue lateral neck radiographs.

MATERIALS AND METHODS

Patients

Thirty patients with acute supraglottitis between January, 1997 and December, 1999 were evaluated. Thirty normal Korean adults who were age- and sex-matched were selected as a control group. The subjects' ages ranged from 25 to 62 years old for the patient group, and 23 to 61 years old in the control group. The patient group consisted of 17 males and 13 females and the control group consists of 16 males and 14 females.

The radiographic parameters were measured by two Otolaryngologists and two Diagnostic Radiologists who had no prior knowledge of the patients and the control group. The parameters were measured twice at different times. The measurements from by each reviewer were averaged. The maximum widths of several structures were measured, including the epiglottis width (EW)

Received January 5, 2001
Accepted May 25, 2001

Reprint address: request to Dr. Moo-Jin Choo, Department of Otolaryngology, Chungbuk National University Hospital, 62, Gaeshin-Dong, Heungduk-Gu, Cheongju 361-711, Korea. Tel: 82-43-269-6350, Fax: 82-43-265-6157, E-mail: mjchoo@med.chungbuk.ac.kr

and the aryepiglottic fold width (AEW). The measurements were followed by a modification of Rothrock's method with the drawing division and ruler (an error, 0.05 mm) which was measured by one inspector with a magnifier ($\times 2$). A student's t-test was used for statistical analysis (Table 1).

Table 1. Dermographics of Normal Controls and Patients with Acute Supraglottitis

	Control group(n=30)	Patient group(n=30)
Age(range)	23-61	25-62
Male: Female	16:14	17:13

Method of radiographic examination

Radiological studies of the pharyngolaryngeal structures, both the anteroposterior and lateral projections, were done using the method described by Ballenger.⁵

Measurement of parameters

The epiglottis width (EW) is the widest anterior-posterior diameter of suprahoid epiglottis. The aryepiglottic fold width (AEW) is the widest width of the A-E fold (Fig. 1).

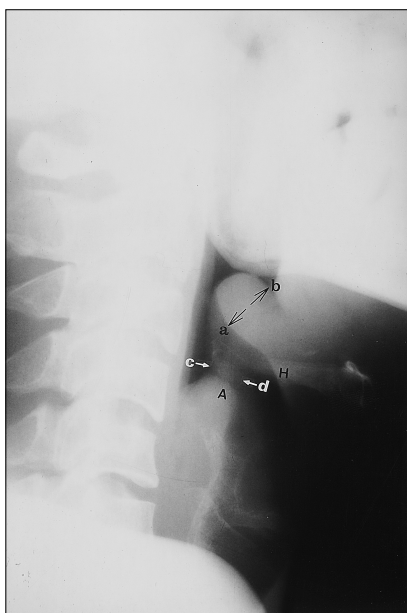


Fig. 1. Measurement of parameters a-b: Epiglottis width, c-d: Aryepiglottic width. H, Hyoid bone; A, Arytenoid.

RESULTS

The mean of epiglottis width (EW) and aryepiglottic fold width (AEW) in the control group were 4.37 ± 0.93 mm (2SD) and 2.45 ± 0.71 mm (2SD), respectively. The patient group showed larger parameters, which were measured as 15.87 ± 3.60 mm, and 6.4 ± 2.55 mm. These results are statistically significant ($p < 0.05$). (Table 2). In diagnosing acute supraglottitis in Korean adults, an EW more than 7 mm showed 100% sensitivity and specificity. An AEW more than 4.5 mm showed 83% sensitivity and 100% specificity (Table 3).

Table 2. Radiologic Parameters of the Larynx in the Normal Control and Acute Supraglottitis Patients

	Control group(n=30)	Patient group(n=30)
EW(mm)	$4.37(\pm 0.93)^*$	$15.87(\pm 3.60)^*$
AEW(mm)	$2.45(\pm 0.71)$	$6.44(\pm 2.55)$

* $p < 0.05$.

Values are given as mean and two standard deviation.
EW, epiglottic width; AEW, aryepiglottic fold width.

Table 3. Sensitivity and Specificity of EW and AEW in Acute Supraglottitis

	Sensitivity	Specificity
EW > 7.0 mm	100%	100%
AEW > 4.5 mm	83%	100%

DISCUSSION

Acute epiglottitis is an inflammatory disease, usually caused by *H. influenzae*, which affects the epiglottis and surrounding structures. Supraglottitis is thought to be a more proper term because the inflammation usually involves the supraglottis structure. In children, manipulating the upper airway by an indirect laryngoscopy or tongue blade can be hazardous because of laryngospasm. In contrast direct visualization of the larynx is considered a safe procedure in adults. A flexible nasopharyngolaryngoendoscope has been reported as the method of choice for investigating epiglottic disease.⁶ However, this technique requires special training and expertise. Therefore, the use of soft tissue radiography of the neck is preferable.

Table 4. Comparison of the Radiologic Parameters in Supraglottitis in Adult

	Schmaker ¹¹		Rothrock ¹²			Author	
Number of cases	6 patients		18 study group* (6 patients) 18 control group [†] (6 patients)			30 patients 30 control group	
Parameters	EW > 8 mm	AEW > 7 mm	EW/C3W > 0.5	AEW/C3W > 0.4	EW/EH > 0.6	EW > 7 mm	AEW > 4.5 mm
Sensitivity	-	-	100%	100%	100%	100%	83%
Specificity	-	-	100%	100%	100%	100%	100%

* Eighteen measurements on six patients (Measurements of each radiograph were made by three senior emergency medicine residents).

[†] Control group with croup, pharyngitis, and dysphasia.

EH, Epiglottic Height.

Many subjective radiologic findings have been reported as useful signs in acute supraglottitis. These include a ballooned hypopharynx, the thumb sign, the impression of increased epiglottic and aryepiglottic fold widths, a narrowed tracheal air column, prevertebral soft-tissue swelling, and obliteration of the vallecula and pyriform sinuses.^{1-4,7-9} In diagnosing epiglottitis, the vallecula sign was reported to have a sensitivity of 98.2% and a specificity of 99.5%.¹⁰

Schmaker¹¹ reviewed the standard lateral neck films of six patients over the age of 18 with epiglottitis and five with a normal epiglottis. Radiographic anatomy measured the angle of the valleculae, retropharyngeal soft tissue width at C2, the retrotracheal soft tissue width at C6, the width of the epiglottis, the width of the aryepiglottic folds, and the hypopharyngeal to tracheal air column ratio. An epiglottis width greater than 8 mm and an aryepiglottic folds width greater than 7 mm was suggestive of epiglottitis in adults, and that other radiographic anatomy measurements might not be useful. However, the small number of patients included in this study precludes offering these as rigid guidelines. The application of these criteria to a larger population is needed to determine a more accurate sensitivity and specificity.

In retrospective review by Rothrock et al.,¹² the maximum widths of several structures were measured, including the epiglottis width (EW), the epiglottis height (EH), aryepiglottic folds (AEW), the third cervical vertebral body (C3W), and the hypopharynx (HW). An EW/EH > 0.6, AEW/C3W > 0.4, and EW/C3W > 0.5 were all

found to be 100% sensitive and 100% specific in diagnosing six adults with epiglottitis. An EW/EH > 0.6, an AEW/C3W > 0.35, and an EW/C3W > 0.5 were found to be 100% sensitive and 87%, 96%, and 87% specific in diagnosing pediatric epiglottitis, respectively.

The structures (EW, AEW) on the soft-tissue lateral neck radiograph were simply measured instead of the ratios of potentially enlarged structures to a fixed reference (C3W). Simple measurements of the significant structures in our study showed a relatively high sensitivity and specificity compared to previous studies. With these results, any physician may easily interpret soft tissue lateral neck radiography to diagnose supraglottitis (Table 4).

REFERENCES

1. Hodge KM, Ganzel TM. Diagnosis and therapeutic efficacy in croup and epiglottitis. *Laryngoscope* 1987; 97:621-5.
2. Swischuck LE. Emergency radiology of the acutely ill or injured child. 2nd ed. Baltimore: Williams & Wilkins; 1986. p.127-40.
3. Podgore JK. The "thumb sign" and "little finger sign" in acute epiglottitis. *J Pediatr* 1976;88:154-5.
4. Schabel SI, Katzberg RW, Burgener FA. Acute inflammation of epiglottitis and supraglottic structures in adults. *Radiology* 1977;122:601-4.
5. Ballinger PW. Merrill's atlas of radiographic positions and radiologic procedures. 5th ed. London: Mosby Company; 1982.
6. Cox GJ, Bates GJ, Drake-Lee AB, Watson DJ. The use of flexible nasoendoscopy in adults with acute epiglottitis. *Ann R Coll Surg Engl* 1988;70:361-2.
7. Capitanio MA, Kirkpatrick JA Jr. Upper respiratory

- tract obstruction in infants and children. *Radiol Clin North Am* 1968;6:265-77.
8. Rapkin RH. The diagnosis of epiglottitis: Simplicity and reliability of radiographs of the neck in the differential diagnosis of the croup syndrom. *J Pediatr* 1972;80:96-8.
 9. Swischuk LE, Smith PC, Fagan CJ. Abnormalities of the pharynx and larynx in childhood. *Semin Roentgenol* 1974;9:283-300.
 10. Ducic Y. Description and evaluation of the vallecula sign: A new radiologic sign in the diagnosis of adult epiglottitis. *Ann Emerg Med* 1997;30:1-6.
 11. Schumaker HM. Radiographic parameters in adult epiglottitis. *Ann Emerg Med* 1984;13:588-90.
 12. Rothrock SG. Radiologic diagnosis of epiglottitis: Objective criteria for all ages. *Ann Emerg Med* 1990;19:9:978-82.