

Lower Gastrointestinal Bleeding due to Cytomegalovirus Ileal Ulcers in an Immunocompetent Man

Sung Woo Choi¹, Jun Pyo Chung¹, Young Koo Song¹, Young Nyun Park², Juck Kum Chu¹,
Dong Joo Kim¹, Jae Han Jung¹, Chang Hoon Lee¹, Se Joon Lee¹, Hyo Jin Park¹, Kwan Sik Lee¹,
Sang In Lee¹, In Suh Park¹, and Seung Kook Sohn³

Departments of ¹Internal Medicine, ²Pathology, ³General Surgery Yonsei University College of Medicine, Seoul, Korea

Cytomegalovirus (CMV) infections are commonly reported in severely immunocompromised hosts and ulcers of the alimentary tract are frequently observed in systemic CMV infections. However, invasive and ulcerative disease of the gastrointestinal (GI) tract caused by CMV has also been reported in healthy adults. Many reports show that a CMV infection can produce localized ulcerations in the esophagus, stomach, small intestine, and colon in nonimmunocompromised individuals. The most common site of involvement by CMV infection in the GI tract is the colon followed by the upper GI tract and the least common site is the small intestine. Although GI bleeding is one of the major presenting symptoms of patients with CMV infections of the GI tract, lower GI bleeding due to CMV ileal ulcers in immunocompetent patients, to our knowledge, has not been reported in the English literature. Recently, we experienced a case of lower GI bleeding due to CMV ileal ulcers in a 57-year-old man who had no evidence of immunocompromise. This case suggests that small intestinal ulcers due to CMV infection should be included in the differential diagnosis of lower GI bleeding even in immunocompetent hosts.

Key Words: Cytomegalovirus, immunocompetent host, ileum, ulcer, bleeding

INTRODUCTION

Cytomegalovirus (CMV) infections are commonly reported in severely immunocompromised hosts with acquired immunodeficiency syndrome (AIDS) and in patients who have received immunosuppressive therapy after transplantation or

chemotherapy for malignant disease.¹ The alimentary tract is the target organ for CMV infections, and ulcers of the alimentary tract are frequently observed in systemic CMV infections.^{2,3} However, invasive and ulcerative disease of the gastrointestinal (GI) tract caused by CMV has also been reported in healthy adults. Many reports show that a CMV infection can produce localized ulcerations in the esophagus,⁴ stomach,^{5,6} small intestine,⁷⁻⁹ and colon¹⁰⁻¹⁴ in nonimmunocompromised individuals. The most common site of the involvement by CMV infection in the GI tract is the colon followed by the upper GI tract and the least common site is the small intestine.¹⁵

Although GI bleeding is one of the major presenting symptoms of patients with CMV infections of the GI tract,^{15,16} lower GI bleeding due to CMV ileal ulcers in immunocompetent patients, to our knowledge, has not been reported in the English literature. Recently, we experienced a case of lower GI bleeding due to CMV ileal ulcers in a 57-year-old man who had no evidence of immunocompromise. This case suggests that small intestinal ulcers due to CMV infection should be included in the differential diagnosis of lower GI bleeding even in immunocompetent hosts.

CASE REPORT

A 57-year-old man was admitted to the hospital on March 6th, 1999 because of a two-day history

Received August 4, 2000
Accepted August 28, 2000

of dark blood per the rectum. He was told that his blood pressure was high, but he did not take any medicine. Otherwise, the patient had been well except for a self-limited diarrheal illness one month prior to this admission. He had consumed alcohol in mild quantities and was an ex-smoker (30 pack years). On admission, he complained of mild abdominal discomfort, anorexia, and nausea, but denied vomiting, fever, weakness, weight loss or dyspnea. The physical examination revealed an average Korean man 168 cm tall and weighing 60 kg. The temperature was 36.8°C, the blood pressure 150/100 mmHg, and the pulse rate 80/min. He appeared slightly ill and the examination of the abdomen revealed mild direct tenderness on the epigastrium and the left periumbilical area, but no masses or organomegaly. The rectal examination was positive for dark blood, but negative for a mass.

Laboratory findings included a hemoglobin of 8.5 g/dL, a leukocyte count of 7,360/mm³ (neutrophil 53.8%, lymphocytes 27.8%, monocytes 5.7%, eosinophils 12.1%), and a platelet count of 213,000/mm³. The serum electrolytes and blood chemistry were not remarkable. The HBsAg and anti-HBs antibody were negative. At the emergency room, a nasogastric tube was inserted and the result of test irrigation was negative for bleeding. Since it was a Saturday evening and his vital signs were stable, we decided not to perform any urgent endoscopic examinations. The patient was transferred to an intensive care unit.

Despite the transfusion of several pints of packed red blood cells, his hemoglobin did not go up. Moreover, he passed large amounts of dark blood through the rectum on the third hospital day. An esophagogastroduodenoscopy (EGD) was performed and revealed a small red scarring change on the lesser curvature of the distal antrum. Neither fresh blood nor blood clots were found as far as the third portion of the duodenum. In consideration of profuse bleeding, a radionuclide angiography was performed instead of a colonoscopic examination, which suggested active bleeding at the distal small bowel (Fig. 1). An abdominal angiography was carried out to localize the exact bleeding site and to try an angiographic intervention, but failed to demonstrate any active bleeding sites. A small bowel

enteroclysis taken on the fourth hospital day showed an ulcerative lesion on the ileum (Fig. 2). The patient continued to pass blood per the rectum and a total 16 pints of packed red blood cells were transfused up to the fifth hospital day when surgical exploration was performed.

On exploration, the serosa of part of the proximal ileum (approximately 100 cm proximal to the ileocecal valve) was erythematous. A segmental resection of the proximal ileum (22 cm) was

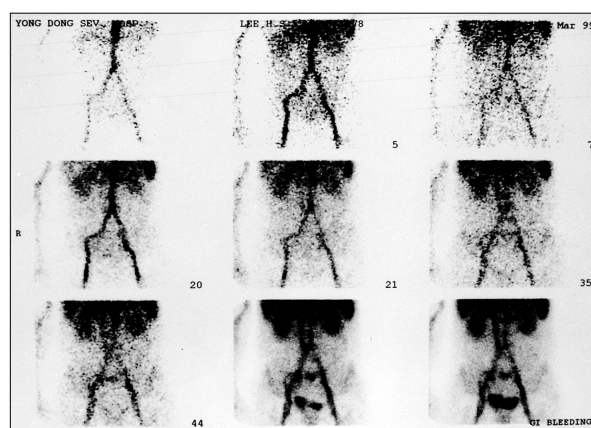


Fig. 1. A serial static radionuclide image angiography showing the migration of increased radioactivity to the right lower quadrant of the abdomen suggesting that the bleeding focus be around the distal jejunum or proximal ileum.

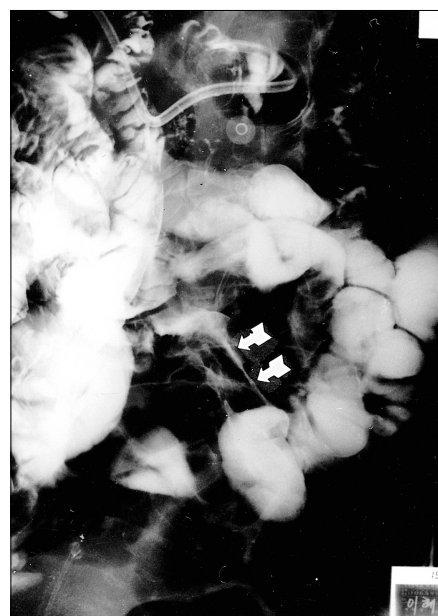

Fig. 2. An x-ray film of small bowel enteroclysis showing luminal narrowing and mucosal irregularity in the proximal ileum (arrows).

carried out. On opening the resected ileum along the antimesenteric border, the lumen was found to be filled with blood. Since inspection of the mucosal side of the resected ileum revealed that the distal resection margin was positive for inflammation, an additional segmental resection of the ileum (11 cm) was performed.

Grossly, the mucosae of the resected ileum were edematous and had multifocal shallow geographic ulcerations (Fig. 3). The largest ulcer was 4.5×2.0 cm in size. The serosal fat tissue was not adhered. Microscopically, multifocal shallow mucosal ulcerations and regeneration were observed with a mild degree of inflammatory change. Beneath the ulcers, cytomegalic intranuclear inclusion bodies were found mainly in the endothelial cells (Fig. 4),

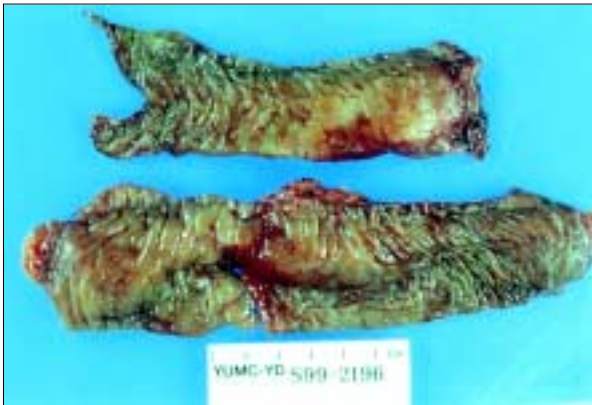

Fig. 3. Gross morphology of the resected specimen showing edematous mucosae and a large (3.0×2.5 cm) geographic ulceration together with multiple small scattered ulcerations.

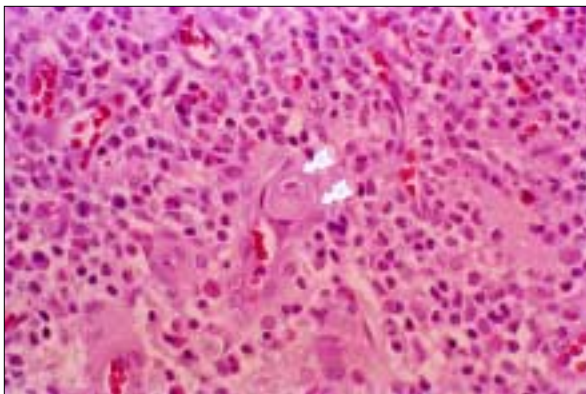


Fig. 4. A microscopic finding of the resected specimen showing a cell with cytomegalic change by a large intranuclear, deeply basophilic inclusion (arrow) (H&E, $\times 400$). These cytomegalic cells were mainly found beneath the ulcer bed.

and thus a diagnosis of CMV enteritis was made. However, the pathologic examination of the biopsied specimens taken from the scarring antral ulcer during the EGD examination was negative for cytomegalic inclusion bodies. After the pathologic diagnosis was confirmed, the serum IgM anti-CMV antibody, CMV-PCR (polymerase chain reaction), and anti-HIV (human immunodeficiency virus) antibody were checked, but all were negative. The patient recovered uneventfully and was discharged on the seventeenth hospital day. Anti-viral medication was not prescribed, but the patient has done well up in the 18 months after operation.

DISCUSSION

The present patient is a case of CMV infection of the ileum causing massive lower GI bleeding. Such localized CMV infection of the GI tract is rare if there is no history of previous intestinal disease such as ulcerative colitis or if a severely immunocompromised state is not apparent. Moreover, according to Cheung and Ng,¹⁵ CMV infection of the small intestine occurred in only one out of 19 non-AIDS patients (4.7%), although it is not clear whether that case was immunocompetent or not.

Recently, Taniwaki et al.² reported a case of multiple ileal ulcers due to CMV infection in an immunocompetent 65 year-old woman. She was reported to present with abdominal pain, nausea, and vomiting. A small bowel radiography with water-soluble iodine demonstrated a mass lesion with a central ulcer in the small intestine. Examination of the resected specimen revealed multiple ileal ulcers with perforation. Other cases with CMV infection of the small intestine reported to present with diarrhea with or without hypoalbuminemia.^{7,8} Thus our present patient is the first case of CMV infection of the small intestine to present with GI bleeding. When the ulcerative lesion was found on small bowel enteroclysis, we included intestinal tuberculosis, Crohn's disease or lymphoma in the differential diagnosis. A CMV ulcer of the ileum was never considered in this case.

There has been some controversy as to whether CMV infection of the GI tract is a primary infec-

tion^{17,18} or the consequence of a superimposed infection of previously damaged tissue¹⁹⁻²¹ and whether the distribution of CMV inclusion bodies is related to the symptoms of the patients. Our present case illustrates that CMV infection of the GI tract can be a primary infection, and that involvement of the endothelial cells rather than that of glandular epithelial cells is the major pathogenetic mechanism leading to tissue damage and ulceration. The occlusion caused directly by the invasion of these cells into the lumen of capillaries and venules and the formation of fibrin thrombi are believed to result in ischemia and consequently mucosal ulceration.²

The diagnosis of GI CMV infection is not difficult if tissues are available. Histopathological determination of the CMV infection does not need the aid of an immunohistological method, because CMV causes a specific cellular change of either the intranuclear or intracytoplasmic cytomegalic inclusion.²² The problem, however, is that cytomegalic inclusion is sometimes not observed in the cells of cultured organs from which CMV was isolated, and the CMV infection is not always associated with cytomegalic inclusion.²³ This means that the CMV infection should be suspected in order to confirm it with an immunohistological stain, virus identification by culture, PCR, electronmicroscopy, etc. Thus the diagnosis of GI CMV infection should be difficult if an immunocompetent patient presents with an unusual manifestation. The present previously healthy man presented with GI bleeding. Fortunately in this case, the lesion was localized by a small bowel enteroclysis and the patient's condition made operation unavoidable, so the diagnosis of CMV infection of the ileum was made possible by histopathologic examination of the resected specimen.

The prognosis of CMV infection in immunocompromised patients is usually poor and therefore ganciclovir or foscarnet is recommended for the treatment of these patients.²⁴ Taken other reported cases together with our present case, however, the outcome of localized CMV-associated lesions in the GI tract seems to be quite good in immunocompetent patients even without anti-viral medications. Actually, two recent major reviews on the use of ganciclovir and foscarnet in

the treatment of CMV disease did not support any role of these drugs in immunocompetent individuals.^{25,26}

In summary, we described the first case of CMV infection of the small intestine to present with GI bleeding in a 57-year-old man who had no evidence of immunocompromise. We suggest that small intestinal ulcers due to CMV infection be included in the differential diagnosis of lower GI bleeding even in immunocompetent hosts.

Jun Pyo Chung, M.D.

Department of Internal Medicine, Yongdong Severance Hospital, Yonsei University College of Medicine, Yongdong P.O. Box 1217, Seoul 135-720, Korea,

Tel: 82-2-3497-3310, Fax: 82-2-3463-3882,

E-mail: chungjp@yumc.yonsei.ac.kr

REFERENCES

1. Goodgame RW. Gastrointestinal Cytomegalovirus disease. *Ann Intern Med* 1993;119:924-35.
2. Taniwaki S, Kataoka M, Tanake H, Mizuno Y, Hirose M. Multiple ulcers of the ileum due to Cytomegalovirus infection in a patient who showed no evidence of immunocompromised state. *J Gastroenterol* 1997;32: 548-52.
3. Nowak TV, Goddard M, Batteiger B, Cummings OW. Evolution of acute Cytomegalovirus gastritis to chronic gastrointestinal dysmotility in a nonimmunocompromised adult. *Gastroenterology* 1999;116:953-8.
4. Villar LA, Massanri RM, Mitros FA. Cytomegalovirus infection with acute erosive esophagitis. *Am J Med* 1984;76:924-7.
5. Andrade JD, Bambirra EA, Lima GF, Moreira EF, De Oliveira CA. Gastric cytomegalic inclusion bodies diagnosed by histologic examination of endoscopic biopsies in patients with gastric ulcer. *Am J Clin Pathol* 1983;79: 493-6.
6. Arnar DO, Gudmundsson G, Theodors A, Valtysson G, Sigfusson A, Jonasson JG. Primary cytomegalovirus infection and gastric ulcers in normal host. *Dig Dis Sci* 1991;36:108-11.
7. Dent DM, Duys PJ, Bird AR, Birkenstock WE. Cytomegalic virus infection of bowel in adults. *S Afr Med* 1975; 49:669-72.
8. Tajima T. An autopsy case of primary cytomegalic inclusion enteritis with remarkable hypoproteinemia. *Acta Pathol Jpn* 1974;24:151-62.
9. Underwood JCE, Corbett CL. Persistent diarrhea and hypoalbuminemia associated with cytomegalovirus enteritis. *Br Med J* 1978;22:1029-30.

10. Blair SD, Forbes A, Parkins RA. CMV colitis in an immunocompetent adult. *J R Soc Med* 1992;85:238-9.
11. Cunningham M, Cantoni L, Humair L. Cytomegalovirus primo-infection in a patient with idiopathic proctitis. *Am J Gastroenterol* 1986;81:586-8.
12. Maignan M, Wahl D, Thiaucourt D, Bach D, De Korwin JD, Vaillant G, et al. Self-limited primary cytomegalovirus colitis in an immunocompetent individual. *J Intern Med* 1992;232:357-9.
13. Surawicz CM, Myerson D. Self-limited cytomegalovirus colitis in immunocompetent individuals. *Gastroenterology* 1988;94:194-9.
14. Wolfe BM, Cherry JD. Hemorrhage from cecal ulcers of cytomegalovirus infection. Report of a case. *Ann Surg* 1973;177:490-4.
15. Cheung ANY, Ng IOL. Cytomegalovirus infection of the gastrointestinal tract in non-AIDS patients. *Am J Gastroenterol* 1993;88:1882-6.
16. Teixidor HS, Honig CL, Norsoph E, Albert S, Mouradian JA, Whalen JP. Cytomegalovirus infection of the alimentary canal: radiologic findings with pathologic correlation. *Radiology* 1987;163:317-23.
17. West JC, Armitage JO, Mitros FA, Klassen LW, Corry RJ, Ray T. Cytomegalovirus cecal erosion causing massive hemorrhage in a bone marrow transplant recipients. *World J Surg* 1982;6:251-5.
18. Meiselman MS, Cello JP, Margaretten W. Cytomegalovirus colitis. Report of the clinical, endoscopic and pathologic findings in two patients with the acquired immune deficiency syndrome. *Gastroenterology* 1985;88:171-5.
19. Cooper HS, Raffensperger EC, Jonas L, Fitts WT Jr. Cytomegalovirus inclusions in patients with ulcerative colitis and toxic dilatation requiring colonic resection. *Gastroenterology* 1977;72:1253-6.
20. Gottlieb MS, Groopman JE, Weinstein WM, Fahey JL, Detels R. The acquired immunodeficiency syndrome. *Ann Intern Med* 1983;99:208-20.
21. Goodman ZD, Boitnott JK, Yardley JH. Perforation of the colon associated with cytomegalovirus infection. *Dig Dis Sci* 1979;24:376-80.
22. Iwasaki T. Alimentary tract lesions in cytomegalovirus infection. *Acta Pathol Jpn* 1987;37:549-65.
23. Makasaet FF, Holley KE, Smith TF, Keys TF. Cytomegalovirus studies of autopsy tissue. II. Incidence of inclusion bodies and related pathologic data. *Am J Clin Pathol* 1975;63:859-65.
24. Anonymous. Treatment of serious cytomegalovirus infections with 9-(1,3-dihydroxy-2-propoxymethyl) guanine in patients with AIDS and other immunodeficiencies. Collaboratory DHPG Treatment Study Group. *N Engl J Med* 1986;314:801-5.
25. Markham A, Faulds D. Ganciclovir. An update of its therapeutic use in cytomegalovirus infection. *Drugs* 1994;48:455-84.
26. Wagstaff AJ, Bryson HM. Foscarnet. A reappraisal of its antiviral activity, pharmacokinetic properties and therapeutic use in immunocompromised patients with viral infections. *Drugs* 1994;48:199-226.