

A Case of Nephrogenic Diabetes Insipidus Caused by Obstructive Uropathy Due to Prostate Cancer

Eun-Gyoung Hong¹, Yujin Suh¹, Yoon-Sok Chung¹, Hyeon-Man Kim¹, Gyu-Tae Shin², Do-Young Chung³, and Rae-Woong Park⁴

Abstract

Nephrogenic diabetes insipidus (DI) secondary to chronic urinary tract obstruction is a rare disease. The exact cause is unknown but it is likely that increased collecting duct pressures cause damage to the tubular epithelium, resulting in insensitivity to the action of arginine-vasopressin (AVP). A 77-year-old man complaining of polyuria and polydipsia was treated with alpha glucosidase inhibitor under the impression of polyuria due to diabetes mellitus. But his symptoms did not improve. Water deprivation and AVP administration study revealed that the patient had nephrogenic DI. Urinary tract obstruction due to an enlarged prostate was suggested as a principal cause of nephrogenic DI. The patient underwent transurethral resection of the prostate and bilateral subcapsular orchiectomy. After surgery, the urine osmolality was normalized and the patient became symptom-free. We report a case of nephrogenic DI due to obstructive uropathy which was cured by surgery eliminating obstruction.

Key Words: Nephrogenic diabetes insipidus, prostate cancer, obstructive uropathy

INTRODUCTION

The causes of diabetes insipidus (DI) are numerous and Randall et al.¹ divided them into primary and secondary forms. The most frequent cause of DI is deficient secretion of arginine-vasopressin (AVP), referred to as central DI. DI is an infrequent complication of systemic cancer and the frequency of metastatic tumor as a cause of central DI occurs in 6% to 20% of cases.¹⁻⁵ It is recognized as a rare paraneoplastic phenomenon. Nephrogenic DI may be acquired owing to obstructive uropathy, unilateral renal artery stenosis, or acute tubular necrosis. In these cases, nephrogenic DI is associated with poor reabsorption of water in the renal collecting ducts, resulting in both increased production and poor concentration of urine.^{6,7} This may be due to either a lack of adequate vasopressin production, or failure

of the collecting duct epithelium to recognize vasopressin.

We experienced a case of a man who had nephrogenic DI with cancer of the prostate. The patient was initially diagnosed with diabetes mellitus with symptoms of polyuria and polydipsia over a period of 3 months at a private clinic. But after treatment with oral hypoglycemic agent, there was no improvement. We evaluated this patient with plasma AVP level, water deprivation test, and the response to exogenous vasopressin administration. We finally diagnosed this case as a nephrogenic DI of obstructive uropathy due to prostate cancer. We report this case with a review of the literature.

CASE REPORT

A 77-year-old male was admitted for evaluation of polyuria and polydipsia of 3 months' duration. Before admission, he visited the out-patient clinic and was treated for polyuria with the clinical diagnosis of diabetes mellitus. Symptoms did not improve even after treatment with alpha glucosidase inhibitor (voglibose 0.3 mg, daily). Past medical records revealed a history of colorectal malignancy and segmental

Received July 12, 1999

Accepted August 20, 1999

Departments of ¹Endocrinology and Metabolism, ²Nephrology, ³Urology and ⁴Pathology, Ajou University School of Medicine, Suwon, Korea.

Address reprint request to Dr. Y. S. Chung, Department of Endocrinology and Metabolism, Ajou University School of Medicine, Suwon 442-721, Korea. Tel: 82-331-219-5127, Fax: 82-331-219-5109, E-mail: cys3333@chollan.net

colectomy, 8 years before. He was diagnosed with hypertension on his visit to our hospital and has since been treated with ramipril 5 mg, and cilazapril 5 mg daily. His family history revealed a daughter with diabetes mellitus who was on treatment with oral hypoglycemics. The patient did not complain of general weakness, easy tiredness, weight loss, or urinary difficulty on admission; however, he did have voiding difficulty of a few years' duration that was neither treated nor evaluated.

His height was 163 cm and weight was 63 kg. Physical examination showed the patient well nourished. Vital signs were as follows: blood pressure 160/100 mmHg, pulse rate 88 beats per minute, respiratory rate 20 breaths per minute, body temperature 36.2°C. Examination of the head and neck did not reveal any lymphadenopathy and no abnormality was found in the chest. The abdomen was also unremarkable. Digital rectal examination revealed marked enlargement of the prostate and nodularity of the right lobe.

Laboratory data revealed hemoglobin 12.0 g/dl, hematocrit 37.7%, white blood cell count 6,400/mm³, platelet 174,000/mm³. Prothrombin time was 11 seconds and activated partial thromboplastin time was 30 seconds. Serum aspartate aminotransferase was 25 U/L and alanine aminotransferase was 31 U/L. Serum sodium, potassium, and chloride were 138, 5.0, 112 mEq/L, respectively. Serum total calcium and inorganic phosphorus were 9.4 and 4.6 mg/dl. Blood urea nitrogen and serum creatinine increased to 30.1 and 2.2 mg/dl. Serum uric acid was 6.9 mg/dl, total bilirubin 0.5 mg/dl, albumin 4.3 g/dl, and total cholesterol 201 mg/dl. Fasting and postprandial 2-hour glucose levels were 114 mg/dl and 237 mg/dl, respectively. Insulin levels for fasting and postprandial were 5.4 μ U/ml, 32.6 μ U/ml, and C-peptide levels were 4.44 ng/ml, 8.92 ng/ml, respectively. HbA_{1c} was 6.6% (normal, 3.5–6.5). The 24-hour urine test showed a decreased creatinine clearance of 16.4 ml/min. Serum and urine osmolarity were 306 and 204 mosm/kgH₂O, respectively. Urine specific gravity was <1.005. Serum carcinoembryonic antigen was 2.3 ng/ml (normal, <4.5). Prostate specific antigen increased to 69 ng/ml (normal, 0–4).

The chest x-ray was normal. Abdominal sonography revealed a 4.4 cm-sized cyst in the lower pole of the left kidney. Marked bilateral hydronephrosis and dilation of the distal ureter was also noted. The

Table 1. Water Deprivation Test

Time	Wt	U.osm	S.osm	U.SG
6 am	66.30	204	306	1.010
7 am	66.10	192	308	1.010
8 am	65.95	204	311	1.015
9 am	65.60	202	305	1.010
10 am	65.35	205	309	1.010
11 am	65.15	207	307	1.010
12 pm	64.90	217	311	1.010
1 pm	64.70	223	312	1.010

(1 hr after 5 units AVP)

Wt, body weight (kg); U.osm, urine osmolarity (mosm/kg H₂O); S.osm, serum osmolarity (mosm/kgH₂O); U.SG, urine specific gravity; AVP, arginine-vasopressin.

sizes of the right and left kidney were 11 and 12 cm, respectively. There were no findings suggestive of metastasis in the liver. Sella MRI showed no evidence of hypothalamic or pituitary lesion.

Water deprivation test was performed (Table 1). The plasma AVP level was 4.51 pg/ml (normal, 0.0–4.7) prior to vasopressin administration. Repeated vasopressin administration test also revealed no significant increase of urine osmolarity after vasopressin injection (250 mosm/kgH₂O before AVP administration, and 257 mosm/kgH₂O after AVP administration). The clinical diagnosis of nephrogenic DI was made. After admission urinary output was more than 4 L/day. A therapeutic trial of hydrochlorothiazide (50 mg, daily) was administered and symptomatic improvement (nocturia and polyuria) was noted (urinary output 2–3 L/day). Obstructive uropathy was suspected as a cause of nephrogenic DI. Diagnostic studies of the urinary tract were performed.

Urodynamic studies revealed a Qmax of 8.5 ml/sec (normal, >10) and obstructive pattern was noted. Residual urine was 750 cc. Voiding cystourethrography showed no reflux, but severe, multiple trabeculation of the bladder was noted. The bladder capacity was 150 cc. Transrectal ultrasonography showed an enlarged prostate (5.8 × 4.6 × 5.4 cm) with 1.2 cm and 0.8 cm-sized focal hypoechoic lesions in the peripheral zones of the right and left prostate, respectively (Fig. 1). A Tc-99m DTPA scan with furosemide showed decreased perfusion and uptake, bilaterally, a perfusion defect of the lower pole of the left kidney, photopenia of both kidneys, hydroureter, and a good response to furosemide, suggesting ob-

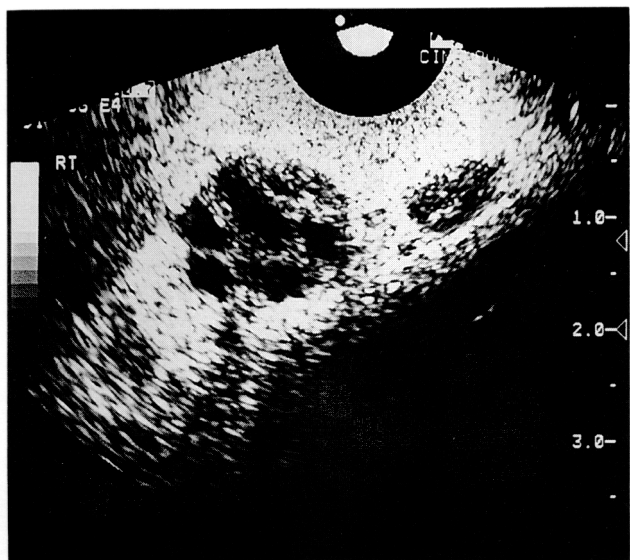


Fig. 1. Transrectal ultrasonography showed focal hypoechoic lesion in both peripheral zone of peripheral gland suggesting prostate cancer.

structive uropathy due to prostatic urethral obstruction (Fig. 2). Cystoscopy showed severe trabeculation and diverticula of the bladder. Prostate biopsy was performed concurrently with TRUS and revealed prostate adenocarcinoma (Gleason's score=7) (Fig. 3).

The patient underwent transurethral resection of the prostate and bilateral subcapsular orchiectomy on the 24th day of admission. After operation urinary output was 2,100 ml/day. The patient recovered well and was discharged 4 days after surgery. On outpatient follow-up, the urine osmolality was normalized (548 mosm/kgH₂O), serum osmolality was 302 mosm/kgH₂O, and plasma AVP was 1.0 pg/ml. We recommended the patient stop hydrochlorothiazide after the 14th postoperative day. Urine osmolality was 445 mosm/kgH₂O, serum osmolality was 304 mosm/kgH₂O, and urinary output was 1,500 ml/day after stopping medication.

DISCUSSION

Nephrogenic DI was first described in the literature as an X-linked familial disease, characterized by insensitivity of the renal tubules to the antidiuretic action of AVP. It occurs with greatest frequency in male subjects and with variable expression in women.⁶ It usually presents itself at an early age with polyuria

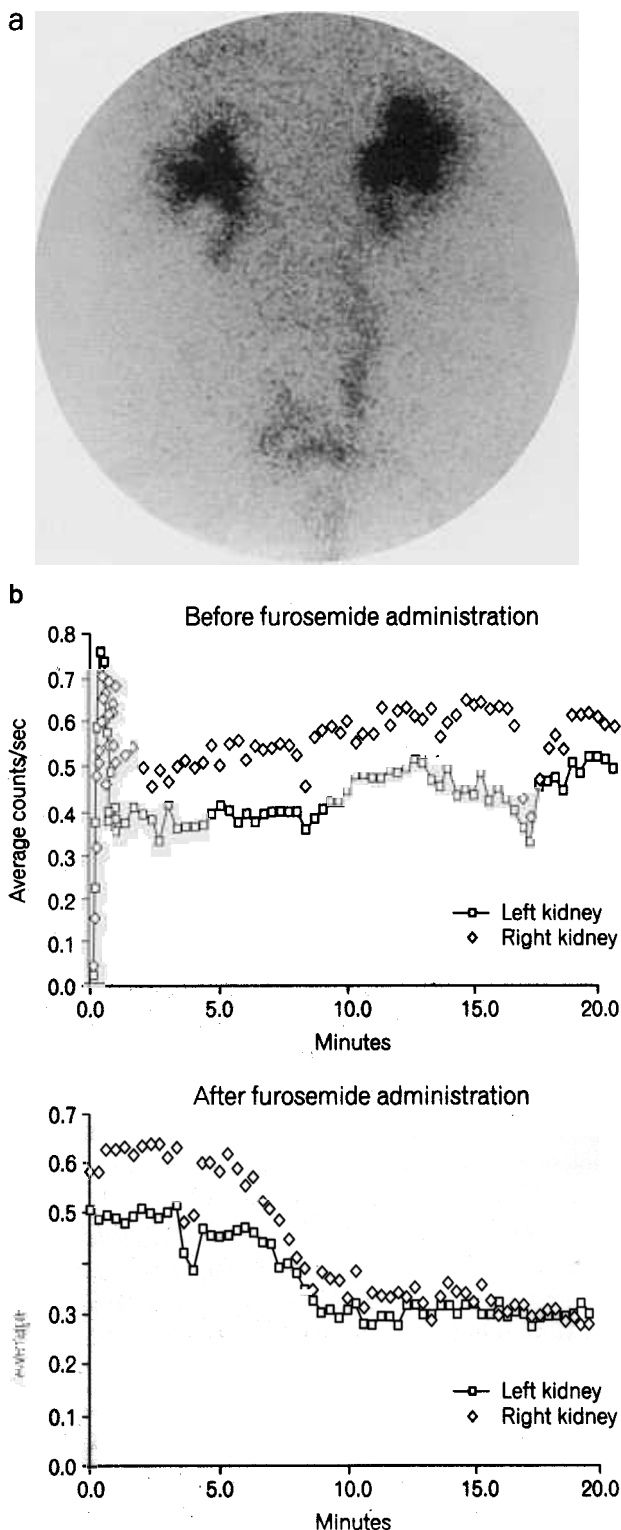


Fig. 2. Tc^{99m} DTPA scan with furosemide revealed obstructive uropathy due to prostate pathology. (a) Tc^{99m} DTPA scan showed bilateral hydronephrosis and hydroureter. (b) Tc^{99m} DTPA renogram revealed obstructive uropathy which had responded after furosemide administration.

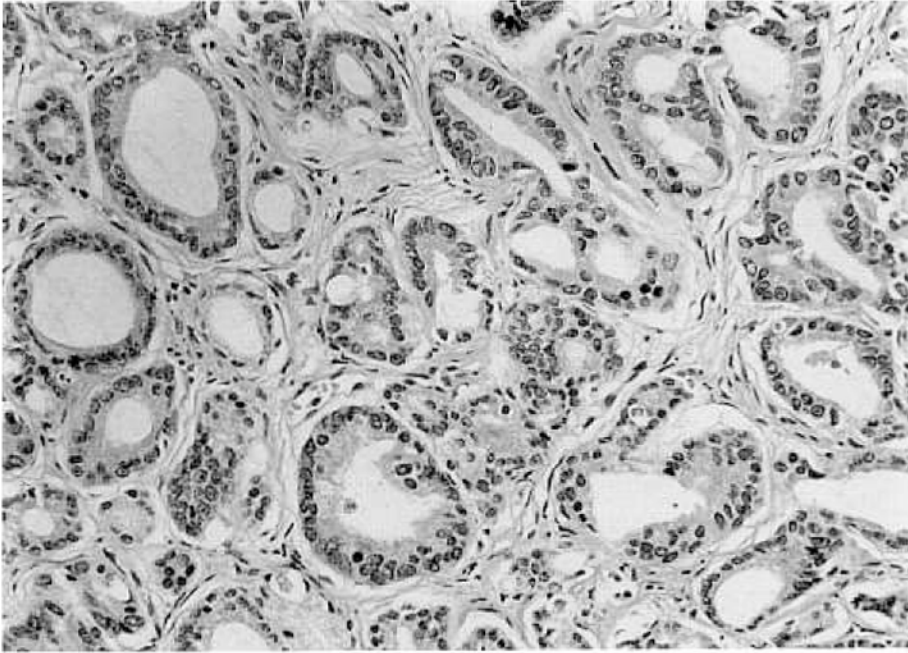


Fig. 3. Microscopic findings of prostate biopsy revealed adenocarcinoma of prostate showing acinar proliferation with atypia and crowding between glands (H&E, $\times 200$).

and polydipsia, or with signs of severe dehydration, fever, vomiting and convulsions,^{2,7} and persists throughout life. However, an autosomal dominant form has also been reported.⁸ Similar defects were found as a result of hypokalemia, hypercalcemia, or by the use of drugs causing renal tubular damage. But in our case, DI occurring at an old age with no significant family history was noted. Also, our patient was not receiving medication and had no metabolic abnormalities, therefore, hereditary causes were ruled out.

Another rare cause of nephrogenic DI is chronic partial urinary tract obstruction. This syndrome has been given a variety of synonyms, including such non-specific terms as water diuresis, water-losing state, water-losing nephritis and obstructive water-losing nephropathy. Baum et al. used the term nephrogenic DI, which describes most closely the pathophysiology of this entity.^{9,10} The exact cause of nephrogenic DI in the case of urinary tract obstruction is unknown, but severe hyposthenuria indicates an intact diluting ability of the kidney and this locates the defect distal to Henle's loop. It is likely that increased collecting duct pressures cause damage to the tubular epithelium resulting in insensitivity to the action of AVP. In cases of slight hydronephrosis, the polyuria can appear during the obstruction, but in cases of severe hydronephrosis, polyuria is prevented by the obstructive lesion. After restoration

of the urine flow, the tubular defect persists and is no longer opposed, resulting in severe polyuria. There are three possible mechanisms responsible for profound polyuria and hyposthenuria: 1) reduction in the number of functioning nephrons with an increased glomerular filtration rate per nephron; 2) decreased proximal tubular reabsorption of sodium and water; and 3) decreased water absorption in the collecting duct and descending limb of Henle's loop.¹¹ In our patient, the unique symptoms of severe hydronephrosis and polyuria showed no response to water deprivation or exogenous vasopressin administration. After surgical correction of urinary obstruction, the symptoms were resolved and urinary concentrating ability was restored.

Nephrogenic DI should be suspected following appropriate clinical presentation and imaging findings. Ultrasonography, voiding cystourethrography, and reflux studies are all important modalities that should be considered. Urologic evaluation with cystoscopy and retrograde urethrography also may be needed to exclude subtle obstructive lesions. Intrarenal resistive index values between 0.5 and 0.7 are indicative of nonobstructive dilatation, as an elevated resistive index (>0.82) may be associated with a physiologically significant upper urinary tract obstruction.¹²⁻¹⁴ And when renal insensitivity to the hormone is incomplete, patients with nephrogenic DI

are able to concentrate their urine when deprived of water or given large doses of vasopressin.

This syndrome must be differentiated from the much more common postobstructive diuresis. This polyuria follows a relatively brief period of urinary tract obstruction and usually resolves itself in 2 to 8 days. It is characterized by isosthenuria and appears to be the response of the kidney to an abnormal extracellular environment such as volume expansion and the accumulation of sodium and urea in contrast to intrinsic renal damage of DI.¹⁵

Treatment of nephrogenic DI usually is medical with thiazide diuretics, a low salt diet, encouragement of frequent micturition, and indomethacin to lessen the progression of the dilatation. Thiazides work by a vasopressin-independent mechanism that involves inhibition of sodium reabsorption in the diluting segment of the nephron followed by increased reabsorption of glomerular filtrate in the proximal tubule. Some patients with partial nephrogenic DI can be treated successfully with high doses of DDAVP. Also, some patients with nephrogenic DI can be successfully treated by eliminating the predisposing factor (drug or disease responsible for the nephrogenic DI). In our case, urine osmolarity was completely normalized after prostate surgery. Therefore, when possible, the curative aim of surgery should be considered as a definitive treatment of nephrogenic DI of obstructive uropathy.

Although most reports suggest that renal failure is rare, case reports of renal failure leading to dialysis exist.^{6,8,16} In our case, mild renal failure initially developed, but severe defects in renal function were not detected. In conclusion, we report a case of nephrogenic DI of obstructive uropathy due to prostate cancer which was successfully treated by prostate surgery.

REFERENCES

1. Kimmel DW, O'Neill BP. Systemic cancer presenting as diabetes insipidus: Clinical and radiographic features of 11 patients with a review of metastatic-induced diabetes insipidus. *Cancer* 1983;52:2355-8.
2. Nobels F, Colemont L, Goethals M, Abs R. Nephrogenic diabetes insipidus: An unusual presentation of recurrent rectal cancer. *Cancer* 1991;68:2056-9.
3. Randall RV, Clark EC, Bahn RC. Diabetes insipidus. *Mayo Clin Proc* 1959;34:299-304.
4. Blontner H. Primary or idiopathic diabetes insipidus. A systemic disease. *Metabolism* 1958;7:191-200.
5. Houck WA, Olson KB, Horton MB. Clinical features of tumor metastasis to the pituitary. *Cancer* 1970;26:656-9.
6. Nakada T, Miyauchi T, Sumiya H, Shimazaki J. Non-obstructive urinary tract dilatation in nephrogenic diabetes insipidus. *Int Urol Nephrol* 1990;22:419-27.
7. Ramsey EW, Morrin PAF, Bruce AW. Nephrogenic diabetes insipidus associated with massive hydronephrosis and bladder neck obstruction. *J Urol* 1974;111:225-8.
8. Zender HO, Ruedin P, Moser F, Bolle JF, Leski M. Traumatic rupture of the urinary tract in a patient presenting nephrogenic diabetes insipidus associated with hydronephrosis and chronic renal failure: Case report and review of the literature. *Clin Nephrol* 1992;38:196-202.
9. Baum N, Anhalt M, Carlton CE Jr, Scott R Jr. Post-obstructive diuresis. *J Urol* 1975;114:53-6.
10. Baum NH, Burger R, Carlton CE Jr. Nephrogenic diabetes insipidus associated with posterior urethral valves. *Urology* 1974;4:581-3.
11. Gibbons MD, Koontz WW Jr. Obstructive uropathy and nephrogenic diabetes insipidus in infants. *J Urol* 1979;122:556-9.
12. Gilbert R, Garra B, Gibbons MD. Renal duplex Doppler ultrasound: An adjunct in the evaluation of hydronephrosis in the child. *J Urol* 1993;150:1192-4.
13. Fung LC, Steckler RE, Khoury AE, McLorie GA, Chait PG, Churchill BM. Intrarenal resistive index correlates with renal pelvis pressure. *J Urol* 1994;152 (2 Pt 2):607-11.
14. Stevens J, Brown BD, McGahan JP. Nephrogenic diabetes insipidus: A cause of severe nonobstructive urinary tract dilatation. *J Ultrasound Med* 1995;14:543-5.
15. Earley LE. Extreme polyuria in obstructive uropathy: Report of a case of "Water-Losing Nephritis" in an infant, with a discussion of polyuria. *N Engl J Med* 1956;255:600-5.
16. Streitz JM Jr, Streitz JM. Polyuretic urinary tract dilatation with renal damage. *J Urol* 1988;139:784-5.

1. Kimmel DW, O'Neill BP. Systemic cancer presenting as