

# Endoscopic Surgery for Obstructive Hydrocephalus

Joong-Uhn Choi, Dong-Seok Kim, and Se-Hyuk Kim

## Abstract

Endoscopic surgery is popular in the neurosurgical field. The purpose of this study was to determine the role of endoscopy in obstructive hydrocephalus. From 1989 to 1999, we performed 81 endoscopic third ventriculostomies and 10 septostomies. Seventy-one of 81 operations were performed with endoscopic third ventriculostomy alone and 10 patients had endoscopic third ventriculostomy and ventriculoperitoneal shunt simultaneously. Age distribution varied from 2 months to 62 years of age. Our selection criteria included aqueductal stenosis (39 patients) and obstructive hydrocephalus due to tumor or cyst (42 patients). The most common candidate for endoscopic septostomy was atresia of the foramen of Monro (4 patients). Endoscopic septostomy was also performed to simplify shunting in patients with multiseptated ventricle due to shunt infection, germinoma, thalamic tumor, craniopharyngioma, cyst and brain abscess. Sixty-five of 71 patients who were treated with endoscopic third ventriculostomy alone showed successful results (91.5%). However, 6 patients had unsatisfactory results and they needed a ventriculoperitoneal shunt. With no mortality, transient surgical complications were observed in 7 patients: 2 transient diabetes insipidus from electrical injury to the pituitary stalk, 1 epidural hematoma from sudden drainage of CSF, 1 delayed intraventricular hemorrhage, 2 obstruction of fenestration site and 1 transient memory disturbance from injury to the fornix. Endoscopic septostomy was useful in simplifying shunting in all cases with complicated hydrocephalus. Endoscopic surgery is straightforward and effective in appropriately selected cases with obstructive hydrocephalus.

**Key Words:** Endoscopic third ventriculostomy, endoscopic surgery, obstructive hydrocephalus, septostomy

## INTRODUCTION

In the era before the shunting of cerebrospinal fluid, the most common operation for the relief of obstructive hydrocephalus was third ventriculostomy.<sup>1-7</sup> Third ventriculostomy was first performed by Dandy in 1922.<sup>8</sup> Unfortunately, this operation had a high failure rate when the hydrocephalus was congenital, and it had a significant surgical morbidity rate.<sup>9-13</sup> The development of the valved shunt by Nulsen and Spitz in 1951 revolutionized the management of hydrocephalus. However, in the long term, shunting for hydrocephalus still has numerous drawbacks related to shunt malfunction and infection. In part, the report by Guiot that third ventriculostomy using stereotactic methods could be safe and easy stimulated our curiosity.<sup>14</sup> Interest was further stimu-

lated by the report of Sayers and Kosnik that third ventriculostomy was effective for the control of congenital hydrocephalus if it was preceded by a period of low-pressure shunting.<sup>15</sup>

Mixer had actually performed endoscopic third ventriculostomy as early as 1923, but the procedure never became popular because of the large diameters and poor illumination of the existing instrumentation.<sup>16</sup> This situation changed in the 1960s with the development of fiberoptic technology. The incorporation of this technology into endoscopic equipment permitted the construction of small-diameter endoscopes with high-intensity external light sources.<sup>17-20</sup>

The author has performed endoscopic surgery in 91 patients with obstructive hydrocephalus since 1989, and now reports the results of this procedure with a review of the literature.

## MATERIALS AND METHODS

### Patient selection

Obstructive hydrocephalus is a primary indication for endoscopic third ventriculostomy. Our selection

Received October 22, 1999  
Department of Neurosurgery, Brain Research Institute, Yonsei University College of Medicine, Seoul, Korea.  
Address reprint request to Dr. J. U. Choi, Department of Neurosurgery, Brain Research Institute, Yonsei University College of Medicine, C.P.O. Box 8044, Seoul 120-752, Korea. Tel: 82-2-361-5631, Fax: 82-3-393-9979, E-mail: dskim33@yumc.yonsei.ac.kr

criteria include aqueductal stenosis and obstructive hydrocephalus due to tumor or cyst. Endoscopic third ventriculostomy is not suitable for patients who have had meningitis or subarachnoid hemorrhage, or who have congenital hydrocephalus.

The most common candidate for endoscopic third ventriculostomy in our series was aqueductal stenosis, which included 39 cases. Other causes were 15 tectal tumors, 11 pineal tumors, 10 posterior fossa tumors, 2 cavernous malformations on midbrain, 2 obstructions of fourth ventricular exit, 1 thalamic tumor, and 1 Dandy-Walker cyst. The most common candidate for endoscopic septostomy was atresia of foramen of Monro (4 patients). Endoscopic septostomy could be also used to simplify shunting in patients with isolated ventricle after shunting, multiseptated ventricle due to shunt infection, germinoma, thalamic tumor, craniopharyngioma, and brain abscess.

### Diagnostic work-up

Routine preoperative work-ups were computed tomography, radioisotope cisternography, CSF flow study with phase contrast cine MR and cine MR.

Radioisotope cisternography is useful in confirming obstruction or isolation in some portion of the ventricle. However, it has the risk of tonsillar herniation and radiation hazard. MR imaging provides important information concerning the morphology of the third ventricle and allows the identification of an appropriate puncture site in the floor of the third ventricle. CSF flow study with phase-contrast cine MR is useful in quantitatively evaluating CSF dynamics in patients with hyperdynamic aqueductal CSF or aqueductal obstruction. Cine MR would also provide beautiful views of CSF flows via the ventriculostomy site in the floor of the third ventricle after endoscopic third ventriculostomy.

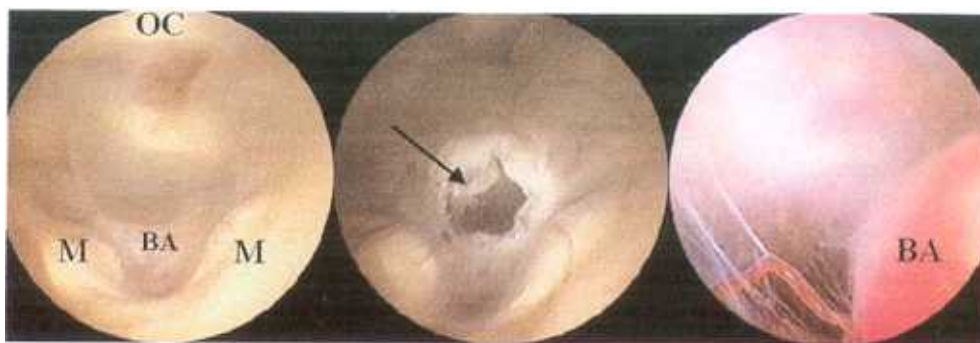
### Instrumentation

Instrumentation for endoscopic third ventriculostomy consists of a 30-degree Hopkins pediatric telescope (Karl Storz, Tuttlingen, Germany) with an outside diameter of 2.7 mm, a sheath for the telescope with an outside diameter of 3.8 mm, a stylet, coagulating electrodes, a Nd-Yag laser system, a fiberoptic light guide, a Xenon light source and an endovision system. We used the rigid type only for

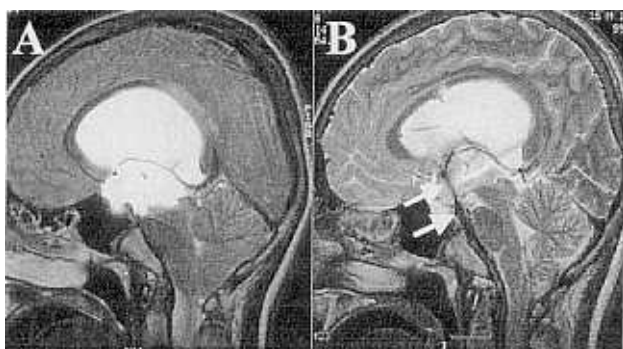
third ventriculostomy, but a steerable endoscope can be used with the advantage of changing the direction of view in manipulating intraventricular structures. For perforating the third ventricle floor, monopolar-coagulating electrode was applied via the working channel. The Nd-Yag laser system was used on a low-wattage setting to incise the septum. Therefore, we could create CSF communication between the isolated ventricle and normal CSF pathways. An irrigation system with a warm normal saline solution via the telescope sheath was useful and essential in maintaining clear vision during endoscopic procedures.

### Operative technique

Third ventriculostomy is performed under general anesthesia. The patient is positioned supine, and routine skin preparations and draping are used for a burr hole. A burr hole is made 1 cm in front of the coronal suture and 2–3 cm lateral to the midline. The right lateral ventricle is tapped using a ventricular catheter through the burr hole, and a peelay catheter is placed via a tract. The tip of the tapping catheter is directed to the glabella and tragus of the right ear. The telescope with sheath is then advanced into the lateral ventricle through the peelay catheter. The foramen of Monro is identified, and the telescope is then advanced through the foramen to visualize the floor of the third ventricle. The site for third ventriculostomy is located halfway along the midline between the infundibular recess and the mamillary body. In some cases of severe hydrocephalus, the dome of the basilar artery is visualized in front of both mamillary bodies. To perforate the third ventricular floor, the coagulating electrode is advanced via a working channel in the sheath. Monopolar electrocoagulation with the electrode can easily perforate the third ventricular floor under direct vision (Fig. 1). Sometimes the telescope can be advanced through a thinned coagulated portion of the third ventricle floor. A flow of CSF through the hole is usually seen after perforation. The hole is enlarged with the insertion of the telescope and the basilar artery in the interpeduncular cistern is usually inspected. The telescope and its sheath are removed and the cortical incision is packed with a piece of gelfoam. The wound is closed and an epidural pressure monitoring sensor can be inserted for postoperative



*Fig. 1. Endoscopic appearance of third ventricular floor. Left: Before ventriculostomy. Center: After ventriculostomy. Right: Endoscope is advanced through the hole into the interpeduncular cistern. M, mamillary body; OC, optic chiasm; Arrow, site of ventriculostomy; BA, basilar artery.*



*Fig. 2. Brain MRI of a 16-year-old boy with tectal tumor. A: Before ventriculostomy. Aqueductal stenosis and dilated lateral ventricle are seen. B: After ventriculostomy. Flow void is clearly seen between the third ventricle and interpeduncular cistern (arrow).*

intracranial pressure (ICP) monitoring.

#### Postoperative management and assessment of outcome

Initially, ICP is monitored for 48h until a trend is established. In patients who show high ICP for over 48 hours postoperatively, lumbar drainage of CSF has been tried for 1 week. Brain MRI with T2-weighted axial and T2-weighted mid-sagittal thin slices is performed on the 10th postoperative day. A flow void in the floor of the third ventricle can usually be seen (Fig. 2).

The assessment of outcome is based on a combination of (a) resolution of symptoms of raised ICP, (b) ICP measurements, and (c) a neuroimaging study, e.g., MRI with a CSF flow study or cine MR (Fig. 3).

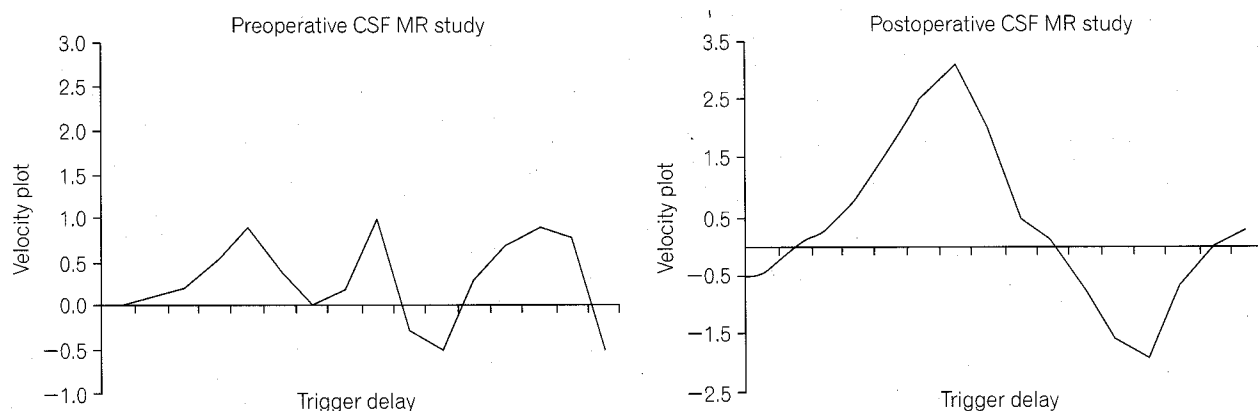
There are two possible results:

1. Success, i.e., the patient does not need a shunt and has improved clinical symptoms;
2. Failure, i.e., there was no significant alteration in symptoms in the postoperative period and the patient required placement of an extracranial shunt postoperatively.

## RESULTS

Eighty-one patients with obstructive hydrocephalus underwent endoscopic third ventriculostomy. Ten of the 81 cases had third ventriculoperitoneal shunt simultaneously (group B), because we thought that these patients might possibly have CSF absorption problems. Sixty-five out of 71 patients treated with endoscopic third ventriculostomy alone (group A) were successful (91.5%) (Table 1). Among the 65 successful cases, 5 patients showed delayed milestones. Temporary CSF drainage from lumbar puncture was helpful to maintain the subarachnoid CSF pathway for these patients.

Endoscopic surgery failed in 6 cases who had to be treated with ventriculoperitoneal shunt (Table 2). Three of the 6 failed cases were patients with aqueductal stenosis under the age of 1 year. The other failed cases were a 14-year-old boy who had aqueductal stenosis due to tectal tumor, and a 12-year-old boy with a pineal tumor. Endoscopic surgery in those 2 patients was early in our experience. We thought that this failure might be related to minor bleeding around ventriculostomy site. We judged failure of endoscopy after 48 hours of ICP monitoring, but



**Fig. 3.** CSF flow study using phase-contrast cine MR. Left: Preoperative CSF flow dynamics. CSF flow at prepontine cistern is irregular pattern. Right: After endoscopic third ventriculostomy, postoperative CSF flow study reveals that the flow velocity and stroke volume definitely increased at the prepontine cistern compared to preoperative study.

**Table 1.** Results of Endoscopic Third Ventriculostomy (Group A)

Causes of hydrocephalus	Number of patients	Outcome	
		Success	Failure
Aqueductal stenosis	27	23	4
Aqueductal stenosis with tectal tumor	11	10	1
Aqueductal stenosis, s/p V-P shunt	6	6	
Obstruction of fourth ventricle exit	2	2	
Pineal tumor	11	10	1
Thalamic tumor	1	1	
Posterior fossa tumor	10	10	
Cavernous malformation on midbrain	2	2	
Dandy-Walker cyst	1	1	
Total	71	65 (91.5%)	6 (8.5%)

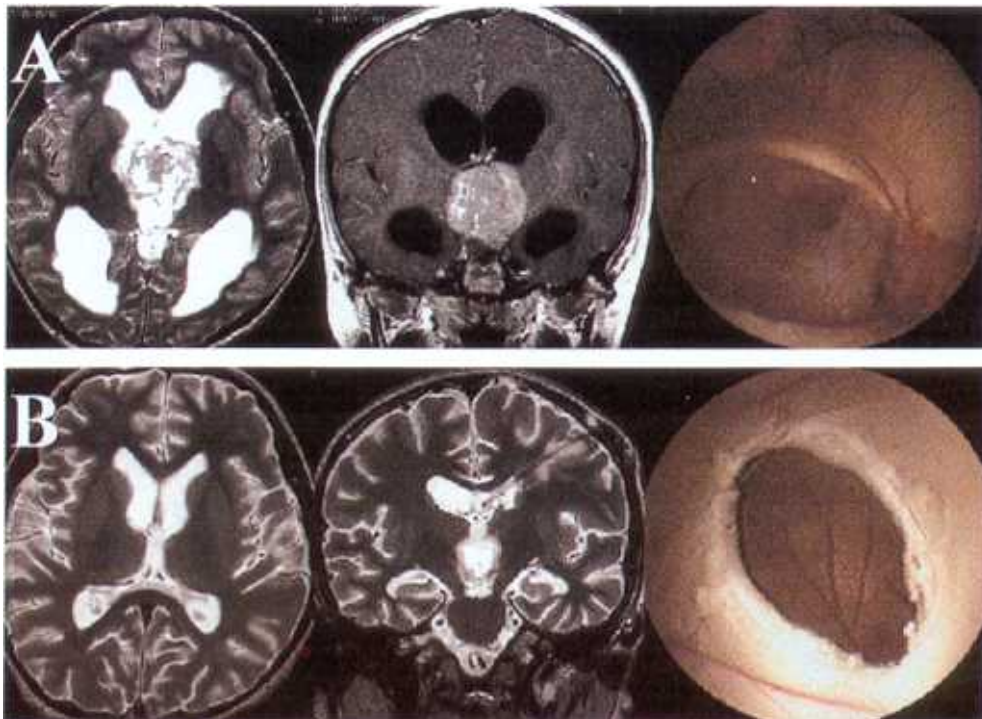
**Table 2.** Unsuccessful Endoscopic Third Ventriculostomy (Failed Group A)

Causes of hydrocephalus	Sex	Age	Treatment
Aqueductal stenosis	M	8/12	V-P shunt
Aqueductal stenosis	M	2/12	V-P shunt
Aqueductal stenosis, Post-hemorrhagic*	M	5/12	V-P shunt
Aqueductal stenosis, Post-hemorrhagic*	M	33	V-P shunt
Tectal tumor	M	14	V-P shunt
Pineal tumor	M	12	V-P shunt

\* Obstruction of ventriculostomy site.

these cases might have been successful if we had tried lumbar CSF drainage for over 1 week.

The other group (Group B) of our series consisted of 10 patients who had been treated with endoscopic third ventriculostomy and ventriculoperitoneal shunt simultaneously. Six patients had ventriculoperitoneal shunt owing to aqueductal stenosis previously at other hospitals, and they had presented with shunt malfunction. These patients were treated with third ventriculostomy with shunt revision. The other four cases presented with hydrocephalus with posterior fossa tumor under the age of 1 year. These patients were treated with third ventriculostomy with shunt revision. The other 4 cases presented with hydrocephalus with posterior fossa tumor under the age of



**Fig. 4.** Endoscopic septostomy. **A:** Before septostomy. Brain MRI showed obstructive hydrocephalus due to bilateral obstruction of the foramen of Monro by suprasellar germinoma. We confirmed the obstruction of the foramen of Monro by suprasellar germinoma with endoscopic view. **B:** Brain MRI showed complete resolution of hydrocephalus 2 weeks after septostomy and one course of chemotherapy with PE regimen. Endoscopic view showed the contralateral ventricle through the septostomy site.

1 year. These 10 patients were thought to need prompt relief of high intracranial pressure or they would have CSF absorption problems. Sixteen patients who had been treated with endoscopic third ventriculostomy and ventriculoperitoneal shunt (10 patients in group B and 6 patients with failed results in group A) have not had any shunt revisions for the last 5 years.

There has been no operative mortality in our series of 81 patients. However, we did have postoperative complications in 7 patients: 2 transient diabetes insipidus from the electrical injury to pituitary stalk, 1 transient memory disturbance from the injury to fornix, 1 epidural hematoma from sudden drainage of CSF, 1 delayed intraventricular hemorrhage, and 2 obstruction of fenestration site. The IVH resolved spontaneously, and the epidural hematoma was evacuated and the patient did well. Two patients showed a thick third ventricular floor, through which we failed to achieve fenestration during endoscopy. These 2 cases were excluded from our series.

Endoscopic septostomy was performed in 10 patients with isolated ventricle owing to atresia of the foramen of Monro, multiseptated ventricle due to shunt infection, germinoma, thalamic tumor, cranio-pharyngioma, cyst and brain abscess. This procedure was useful in simplifying the shunting in all cases (Fig. 4).

## DISCUSSION

### History of neuroendoscopy

Neuroendoscopy was first performed in 1910 by V.L. l'Espinasse, a surgeon from Chicago. He used a rigid cystoscope to fulgurate the choroid plexus bilaterally in 2 infants. One child died immediately and the other lived for 5 years. The event received little attention and passed almost unnoticed at the time. In 1922, Dandy used a rigid cystoscope in an attempt at choroid plexus fulguration in 2 patients.

The instrument was primitive and the procedures were only "partially successful". Dandy correctly predicted that ventriculostomy would be replaced by newer indirect methods of imaging the intracranial contents.<sup>8</sup>

In 1923, Mixer performed the first endoscopic third ventriculostomy in a 9-month old girl with advanced obstructive hydrocephalus due to aqueductal stenosis.<sup>16</sup> He introduced a small urethroscope into the lateral ventricle and then through the dilated foramen of Monro. Under visual guidance, he pushed a flexible sound through the floor of the third ventricle and successfully connected the third ventricle with the basal subarachnoid space.

Although investigators continued to perform ventricular endoscopy, the procedure gradually fell out of favor. Its primary use was to inspect the ventricles, or to extirpate or cauterize the choroid plexus.<sup>21,22</sup> Therapy was often ineffective, and morbidity and mortality rates were very high. Later, improved neuroimaging techniques made it unnecessary to inspect the ventricular system directly. In addition, the development of the valve shunt by Nulsen and Spitz in 1951 revolutionized the management of hydrocephalus. However, shunts are troublesome devices, plagued by many complications including infection, obstruction, misplacement, over-drainage, and under-drainage, etc.

Technical advances in optics, miniaturization, and the steerability of instruments have created renewed interest in neuroendoscopy.<sup>23,24</sup> The modern fiberoptic endoscope appears to provide a simple and safe means for performing third ventriculostomy. It has the advantage over the stereotactic technique of requiring less sophisticated equipment, and allowing direct visualization of the ventriculostomy site.

### Indication

Proper patient selection is crucial to a successful third ventriculostomy.<sup>2,25,26</sup> It is first necessary for all patients to have adequately-dilated third and lateral ventricles. Jones et al. suggested that a suitable size for the third ventricle for endoscopic surgery is about 1 cm bicoronal diameter.<sup>26</sup> Most successes reported in the literature were in patients with acquired aqueductal stenosis.<sup>2,25-27</sup> In our series, aqueductal stenosis also showed good results, especially in children over 1 year of age. We performed endoscopic third ventri-

culostomy and ventriculoperitoneal shunt simultaneously in 6 patients with aqueductal stenosis who showed malfunction of a previously-inserted shunt and in 4 young children with posterior fossa tumor who were supposed to have problems in extra-ventricular CSF circulation due to previous infection or hemorrhage. We anticipate that they will become less dependent on the shunts, which are now communicating above the level of the tentorium. If one could accurately assess the reabsorptive capacity or patency of the subarachnoid space prior to operation, it would be helpful in the selection of appropriate candidates for this procedure.

Several pathologic processes result in compartmentalization or isolation of a portion of the ventricular system, obstructing free drainage of cerebrospinal fluid. Familiar examples are the development of multiple septations arising from bacterial or posthemorrhagic ventriculitis, unilateral dilatation of the lateral ventricle due to atresia of the foramen of Monro, and isolated ventricle due to overdrainage of CSF after shunting. Of course, obstructive hydrocephalus at any level within the ventricular system represents compartmentalization. Each of these pathologic conditions can be very difficult to manage definitively by either shunt diversion or craniotomy. In our experience, neuroendoscopy in association with microtools, especially Nd-yag laser system, that allow dissection or vaporization can often effectively address this challenging group of conditions with substantially less invasiveness and greater operative simplicity.

### Diagnostic work-up

The role of radiological study in management of hydrocephalus is twofold: first to establish that hydrocephalus is present; and second to determine the cause if possible. Both CT and MRI can establish the presence of hydrocephalus, but because of its multiplanar capability, MRI is superior to CT in permitting sagittal, coronal and axial views to be easily obtained. Furthermore, T2-weighted sagittal image of MRI is an excellent test to demonstrate the region of the foramen of Monro which may be occluded because of adhesions or tumors such as colloid cysts, the aqueduct which may be stenosed, or occluded, and the fourth ventricle and its exit foramina which may be obstructed.

The sensitivity of MR imaging to motion was used



to advantage in a study performed to characterize CSF motion in various parts of the neuroaxis. More recent developments of pulse sequence have allowed the generation of MR velocity images that yield quantitative flow information.<sup>28-31</sup> Qualitative cine MR allows a rapid and dramatic evaluation of both normal and abnormal flow in a visual form.<sup>29,30</sup> Quantitative evaluation that allows calculation of CSF velocity is also possible.<sup>30</sup> Cine CSF flow studies can demonstrate the patency of the aqueduct as well as the flow of CSF through to the fourth ventricle and then into the basal cisterns. Flow in the pericord CSF spaces, as well as in the pontine and suprasellar cisterns, is also easily seen. The signal strength is dependent on the velocity of the CSF and therefore ranges between black and white. Using CSF flow study with phase-contrast cine MR, we could confirm the patency of the ventriculostomy site and measure the stroke volume and velocity postoperatively increased compared to preoperative study at the prepontine cistern.

### Outcome

Saint-Rose reviewed 2 identical series of patients with aqueductal stenosis.<sup>32</sup> Thirty-eight patients were treated by insertion of a ventriculoperitoneal shunt and 30 had a third ventriculostomy. He could achieve the best results for third ventriculostomy in patients whom the onset of aqueductal stenosis occurred after 1 year of age; approximately 80% of these patients are shunt-independent after the procedure. This is similar to the results in our series. In the group of patients treated by third ventriculostomy, the ventricle remained enlarged despite clinical normalization in 60% of the patients. Fifty-eight percent of the shunted group developed slit-like ventricles on the CT scan during the same follow-up period. From a neurological, endocrinologic, social and behavioral point of view, there was no statistical difference between the 2 groups.

The major risks of third ventriculostomy are hypothalamic dysfunction by extending the fenestration into the infundibular recess, and hemorrhage from damage to arteries, ependymal veins, or choroid plexus. Hoffman et al. reported their experience of stereotactic third ventriculostomy and reviewed 797 cases treated with third ventriculostomy from the literature.<sup>25</sup> A total of 569 patients were treated with

open craniotomy and 228 cases with percutaneous technique, mostly by the stereotactic method. The overall success rate was about 53%. Operative mortality was 10.3% with the open method and 3.5% with the percutaneous technique. Hoffman concluded that endoscopic third ventriculostomy is a less invasive and effective mean of treating obstructive hydrocephalus.

We had also experienced some postoperative complications such as transient diabetes insipidus, transient memory disturbance, epidural hematoma, and delayed intraventricular hemorrhage. However, these complications were temporary and the patients did well. We conclude that endoscopic third ventriculostomy is a safe and effective mean of treating hydrocephalus in appropriately selected cases with obstructive hydrocephalus.

### REFERENCES

1. Elvidge AR. Treatment of obstructive lesions of the aqueduct of Sylvius and the fourth ventricle by interventriculostomy. *J Neurosurg* 1966;24:11-23.
2. Manwaring KH, Rekeate H, Kaplan A. Hydrocephalus management by endoscopy (Abstract). *Ann Neurol* 1989;26:488.
3. McNickle HF. The surgical treatment of hydrocephalus: A simple method of performing third ventriculostomy. *Br J Surg* 1947;34:302-7.
4. Miler CF, White RJ, Roski RA. Spontaneous ventriculocisternostomy. *Surg Neurol* 1979;11:63-6.
5. Scarff JE. Third ventriculostomy as the rational treatment of obstructive hydrocephalus (Abstract). *J Pediatr* 1965;6:870-1.
6. Scarff JE. Evaluation of treatment of hydrocephalus. Reports of third ventriculostomy and endoscopic cauterization of choroid plexuses compared with mechanical shunts. *Arch Neurol* 1966;382-91.
7. Volkel JS, Voris HC. Third ventriculostomy in obstructive hydrocephalus: Long term arrest in 4 cases. *J Neurosurg* 1966;24:568-9.
8. Dandy WE. An operative procedure for hydrocephalus. *Bull Johns Hopkins Hosp* 1922;33:189-90.
9. Brocklehurst G. Transcallosal third ventriculochiasmatic cisternostomy. New approach to hydrocephalus. *Surg Neurol* 1974;2:109-14.
10. Dandy WE. Diagnosis and treatment of strictures of the aqueduct of Sylvius (causing hydrocephalus). *Arch Surg* 1945;51:1-14.
11. Patterson RH, Bergland RM. The selection of patients for third ventriculostomy based on experience with 33 operations. *J Neurosurg* 1968;29:252-4.
12. Perlman BB. Percutaneous third ventriculostomy in the

- treatment of a hydrocephalic infant with aqueduct stenosis. *Int Surg* 1968;49:443-8.
13. Scarff JE. Third ventriculostomy by puncture of the lamina terminalis and the floor of the third ventricle. *J Neurosurg* 1966;24:935-43.
  14. Guiot G. Ventriculo-cisternostomy for stenosis of the aqueduct of Sylvius. *Acta Neurochir (Wien)* 1973;28:275-89.
  15. Sayers HP, Kosnik EJ. Percutaneous third ventriculostomy: Experience and technique. *Childs Brain* 1976;2:24-30.
  16. Mixter WJ. Ventriculoscopy and puncture of the floor of the third ventricle. *Boston Med Surg J* 1923;188:277-8.
  17. Fukushima T. Endoscopic biopsy of intraventricular tumors with the use of a ventriculofiberscope. *Neurosurgery* 1978;2:110-3.
  18. Griffith HB. Technique of fontanelle and presutural ventriculoscopy and endoscopic ventricular surgery in infants. *Childs Brain* 1975;1:359-63.
  19. Vries J. An endoscopic technique for third ventriculostomy. *Surg Neurol* 1978;9:165-8.
  20. Vries JK. Endoscopy as an adjunct to shunting for hydrocephalus. *Surg Neurol* 1980;13:69-72.
  21. Powell MP, Torrens MJ, Thomson JLG, Horgan JG. Isodense colloid cysts of the third ventricle: A diagnostic and therapeutic problem resolved by ventriculoscopy. *Neurosurgery* 1983;13:234-7.
  22. Scarff JE. The treatment of non-obstructive (communicating) hydrocephalus by endoscopic cauterization of the choroid plexuses. *J Neurosurg* 1970;33:1-18.
  23. Auer LM, Deinsberger W, Niederkorn K, Gell G, Kleinert R, Schneider G, et al. Endoscopic surgery versus medical treatment for spontaneous intracerebral hematoma: A randomized study. *J Neurosurg* 1989;70:530-5.
  24. Auer LM, Holzer P, Ascher PW, Heppner F. Endoscopic neurosurgery. *Acta Neurochir* 1988;90:1-14.
  25. Hoffman HJ. The advantages of percutaneous third ventriculostomy over other forms of surgical treatment for infantile obstructive hydrocephalus In: Morley TP, editor. *Current Controversies in Neurosurgery*. Philadelphia: WB Saunders; 1976. p.691-703.
  26. Jones RFC, Stening WA, Bradon M. Endoscopic third ventriculostomy. *Neurosurgery* 1990;26:86-92.
  27. Heilman CB, Cohen AR. Endoscopic ventricular fenestration using a "saline torch". *J Neurosurg* 1991;74:224-9.
  28. Harris GJ, Rhew EH, Noga T, Pearlson GD. User-friendly method for rapid brain and CSF volume calculation using trans-axial MR images. *Psychiatry Res* 1991;40:61-8.
  29. Katayama S, Asari S, Ohmoto T. Quantitative measurement of normal and hydrocephalic CSF flow using phase-contrast cine MR imaging. *Acta Med Okayama* 1993;47:157-68.
  30. Kim DS, Choi JU, Huh R, Yun PH, Kim DI. Quantitative assessment of CSF dynamics using phase-contrast cine MR imaging in hydrocephalus. *Child's Nerv Syst* 1999;15:461-7.
  31. Nitz WR, Bradley WG, Watanabe AS, Lee RR, Burgoyne B, O'Sullivan RM, et al. Flow dynamics of cerebrospinal fluid: Assessment with phase-contrast velocity MR imaging performed with retrospective cardiac gating. *Radiology* 1992;183:395-405.
  32. Sainte-Rose C. Third ventriculostomy. *Neuroendoscopy*. New York: Marg Ann Liebert, Inc.; 1992. p.47-62.