

# Neuro-Behcet's Disease Presenting with Isolated Unilateral Lateral Rectus Muscle Palsy

Helen Lew<sup>1</sup>, Jong-Bok Lee<sup>1</sup>, Seung-Han Han<sup>1</sup>, Hee-Seon Kim<sup>2</sup>, and Sang-Kyun Kim<sup>3</sup>

## Abstract

The authors present the clinical findings of a 30-year-old female and a 29-year-old male who both had isolated unilateral lateral rectus muscle palsy in neuro-Behcet's disease. The clinical feature related to isolated abducens nerve palsy was identified by CT, systemic assessment and extraocular examination. These patients' constellation of findings appear to be unique: it does not follow any previously reported pattern of ocular manifestations of neuro-Behcet's disease.

**Key Words:** Neuro-Behcet's disease, sixth nerve palsy

## INTRODUCTION

Behcet's disease is a chronic systemic disease including recurrent oral and genital ulceration, ocular inflammation, arthritis, and neurological manifestations.<sup>1</sup> Anterior uveitis and occlusive retinal vasculitis are the most common ocular manifestations of Behcet's disease.<sup>2</sup> Meningoencephalitis, often affecting the brainstem, is the most common neurologic involvement of Behcet's disease with spinal cord symptom, peripheral nerve disorder, cerebellar symptoms, cranial nerve palsy, increased intracranial pressure signs, and extrapyramidal symptoms. The lesion relatively spares the tegmentum of the brainstem, where the medial longitudinal fasciculus fibers are located.<sup>3</sup> We report isolated lateral rectus palsy without iritis or any other ocular symptoms as an initial manifestation of neuro-Behcet's disease.

## CASE REPORT

Received November 21, 1998

Accepted May 7, 1999

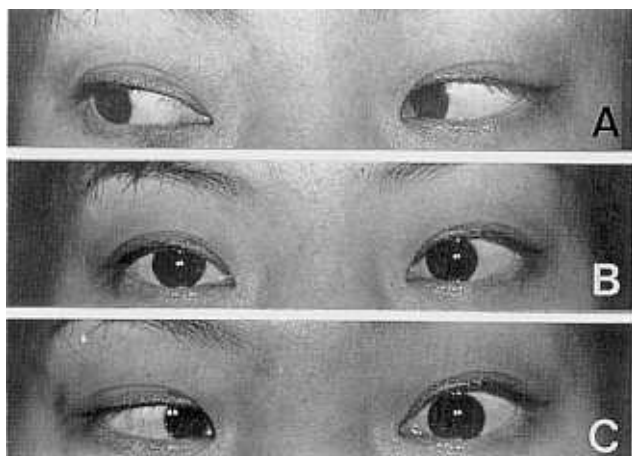
<sup>1</sup>The Institute of Vision Research, Department of Ophthalmology, Eye & ENT Hospital, Yonsei University College of Medicine,

<sup>2</sup>Department of Ophthalmology, Pocheon Cha University College of Medicine, <sup>3</sup>Department of Ophthalmology, Inha University College of Medicine

Address reprint request to Dr. Helen Lew, Department of Ophthalmology, Eye & ENT Hospital, Yonsei University College of Medicine, C.P.O. Box 8044, Seoul 120-752, Korea. Tel: 82-2-361-8450, Fax: 82-2-312-0541, E-mail: hllew0332@yumc.yonsei.ac.kr

## Case 1

A 30-year-old woman was referred to us with acute-onset diplopia. She had undergone recurrent aphthous ulceration of the oral mucous membrane, genital ulcers, and erythema nodosum-like lesions for 3 years. The diagnosis of Behcet's disease was made by the criteria of the Behcet's disease research committee of Japan<sup>4</sup> and the International study group for Behcet's disease.<sup>5</sup> The pathergy test was reported to be positive. On initial examination, visual acuity was 20/20 in each eye. The pupils reacted promptly to light. Extraocular movement was consistent with left isolated cranial 6<sup>th</sup> nerve palsy. With the right eye fixing, there were 50 prism diopters of left esotropia at the primary position. The amount of deviation did not change on right gaze, but was markedly increased to 70 prism diopters on left gaze with marked limitation in abduction of the left eye (Fig. 1). The forced duction test was negative. Slit-lamp and ophthalmoscopic examinations were normal in both eyes. The C-reactive protein was normal, 0.2 mg/dl, and the erythrocyte sedimentation rate was 38 mm/hour, while other virus marker study showed normal reports except for erythematous swelling of the ankle joint. The rheumatoid factor was negative. The remainder of the neurological examination and physical examination were normal. The magnetic resonance imaging (MRI) evaluation of the brain and orbit was also normal. A diagnosis of neuro-Behcet's disease was made and prednisolone 5 mg/day and oral administration of colchicine (1.2 mg/day) was main-

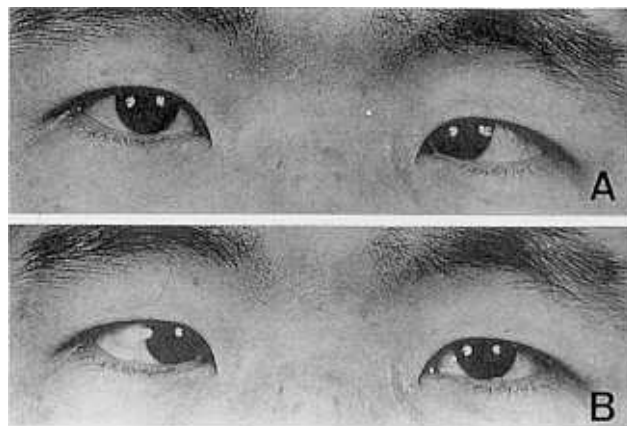


**Fig. 1.** Clinical photographs of eye movements. Both eyes were capable of full movement on right gaze (A). Fifty prism diopters of left esotropia were noted in the primary position (B). The left eye did not cross the midline and showed an increased amount of esotropia to 70 prism diopters on left gaze (C).

tained. The patient has been observed and followed up for evaluation of extraocular motility.

## Case 2

A 29-year-old male with sudden abducens palsy was found to have oral aphthae, genital ulcer, skin lesions, and other neurological manifestations; weakness and sensory loss of the lower extremities, ataxic gait, speech disturbance, and urinary difficulty, but he had no other ocular manifestations such as uveitis or retinal vasculitis apart from than lateral rectus palsy. The pathergy test was reported to be negative. The diagnosis was confirmed as Behcet's disease according to criteria of the Behcet's disease research committee of Japan<sup>4</sup> and the International study group for Behcet's disease.<sup>5</sup> He had 35 prism diopters of left esotropia at the primary position. The amount of deviation did not change on right gaze but was markedly increased to 50 prism diopters on left gaze with marked limitation in abduction of the left eye (Fig. 2). The rheumatoid factor was positive. Cerebrospinal fluid examination showed an opening pressure of 130 mmH<sub>2</sub>O, a leukocyte count of 34 mm<sup>3</sup> with 100% monocytes and a protein level of 56 mg/dl. The magnetic resonance imaging (MRI) of the brain and orbit was normal. The patients' clinical picture was consistent with an isolated sixth cranial nerve palsy, considering the neuro-Behcet's disease. The limitation of abduction of the left eye changed to normal after



**Fig. 2.** Clinical photographs of eye movements. Thirty-five prism diopters of left esotropia were noted in the primary position (A). The left eye did not cross the midline on left gaze, whereas the left eye adducted completely (B).

two cycles of pulse steroid therapy.

## DISCUSSION

Behcet's disease is a multisystem disease with features of mucocutaneous, ocular, intestinal, articular, vascular, and neurologic involvement.<sup>6,7</sup> The subclassification of neuro-Behcet's disease may be applied if the Behcet's disease patients have positive symptoms of central nervous system complications. The clinical picture is usually characterized by signs of either a meningoencephalitis or a sinus thrombosis.<sup>8-10</sup> Our patient was determined as having neuro-Behcet's disease with oral aphthae, genital ulcers, erythema nodosum, arthralgias, and neurologic involvement. Neurological involvement was observed in 2.2% of the general population while 5.7% to 9.2% of Asians have presented with central motor paresis, brain stem and cerebellar symptoms.<sup>11</sup> Systemic manifestations in our patients showing neuro-Behcet's lesions are most consistent with vasculitis predominantly affecting the small venules of the central nervous system.<sup>12</sup> These lesions have a predilection for the diencephalic structures and the brain stem, and they are usually demonstrable by use of radiological examination. Resolution of the abnormalities on CT and MR scans are known to be correlated with the clinical improvement brought about by steroid and immunosuppressive therapy.<sup>12,13</sup>

Both of our patients had a unilateral abducens

nerve palsy combined with other neurological manifestations. To our knowledge, an isolated focal lesion affecting the abducens nerve has not previously been reported in a patient with neuro-Behcet's disease. The only fascicular syndrome of the third cranial nerve is usually reported to be associated with other neurological findings because of the involvement of neighboring structures.<sup>14</sup> That study reported a clinical case of fascicular oculomotor palsy with few associated minor signs, secondary to neuro-Behcet's disease with magnetic resonance imaging (MRI) findings. The lesion extending from the mesencephalon to the capsulothalamic area without involvement of the posterior commissure suggests that the upgaze palsy is due to the mass effect of the lesion, particularly on the rostral mesencephalon, and that the oculomotor nerve palsy is the result of fascicular involvement.<sup>14</sup> Isolated lateral rectus palsies are rare and all of the reported cases have been of vascular origin.<sup>14</sup> Colchicine, a strong inhibitor of polymorphonuclear chemotaxis, is known to be effective not only for oral aphthous ulcers but also for vasculitis in which the early stage is predominated by polymorphonuclear cells. The patients also had oral medication and one of them showed improvement in the limitation of abduction. The differential diagnosis for abducens nerve palsy has to be done for diabetes, hypertension (which spontaneously improved in about 3 months), idiopathic conditions, pontine glioma, meningioma, trauma, temporal arteritis, and aneurysm of the cavernous sinus (which last at least 6 months or permanently). Therefore, neuro-Behcet's disease must be considered for patients complaining of sudden lateral rectus palsy as a differential diagnosis.

## REFERENCES

1. Berlin C. Behcet's syndrome with involvement of central nervous system. Report of a case with neoprosy. *Arch Dermatol Syphilol* 1994;49:227.
2. Joseph BM, Francis VC. Behcet disease. *Surv Ophthalmol* 1982;26:190-203.
3. Saribas O, Aydin-Kirkali P, Erdem E, Calguner M. Fascicular oculomotor nerve palsy in neuro-Behcet's disease. *J Clin Neuroophthalmol* 1991;11:300-5.
4. Mizushima Y, Inaba G, Mimura Y, Ono S. Diagnostic criteria for Behcet's disease in 1987, and guideline for treating Behcet's disease (in Japanese). *Saishin Igaku* 1988; 43:391-3.
5. International Study Group for Behcet's Disease (ISGBD). Criteria for diagnosis of Behcet's disease. *Lancet* 1990; 335:1078-80.
6. Shimizu T, Ogino T. Clinico-pathological studies on the intestinal lesions in Behcet's disease with special reference to entero-Behcet's syndrome. *Stomach Intestine* 1975;10: 1593-9.
7. Takano M, Mizajuna T, Kiuchi M. Behcet's disease and the HLA system. *Tissue Antigens* 1976;8:95-9.
8. Oshima Y, Shimizu T, Yokohari R, Matsumoto T, Kano K, Kogami T, et al. Clinical studies in Behcet's syndrome. *Ann Rheum Dis* 1963;22:36-45.
9. Aggarwal JL. Behcet's disease with recurrent facial paralysis. *Br J Ophthalmol* 1973;57:704-5.
10. O'Duffey JD, Goldstein NP. Neurological involvement in seven patients with Behcet's disease. *Am J Med* 1976;61: 170-8.
11. Bang D, Yoon KH, Chung HG, Choi EH, Lee ES, Lee SN. Epidemiological and clinical features of Behcet's disease in Korea. *Yonsei Med J* 1997;38:428-36.
12. Steven LG, Smith JL. Chronic isolated sixth nerve palsies. *Arch Neurol* 1989;46:79-82.
13. Shimizu T. Epidemiological and clinico-pathological studies on neuro-Behcet's syndrome. *Adv Neurol Sci* 1972;16: 167-78.
14. Masai H, Kashii S, Kimura H, Fukuyama H. Neuro-Behcet disease presenting with internuclear ophthalmoplegia. *Am J Ophthalmol* 1996;122:897-8.