

# The Effect of Selective Tibial Neurotomy and Rehabilitation in a Quadriplegic Patient with Ankle Spasticity Following Traumatic Brain Injury

Sung Ho Jang<sup>1</sup>, Sung-Min Park<sup>1</sup>, Seong Ho Kim<sup>2</sup>, Sang Ho Ahn<sup>1</sup>, Yun Woo Cho<sup>1</sup>, and Mi Ok Ahn<sup>1</sup>

Department of <sup>1</sup>Physical Medicine & Rehabilitation and <sup>2</sup>Neurosurgery, Yeungnam University College of Medicine, Taegu, Korea.

Ankle spasticity following brain injury leads to abnormal posture and joint contracture; making standing or walking impossible. This study investigates the efficacy of selective tibial neurotomy (STN) and intensive rehabilitation in a patient who suffered ankle spasticity after brain injury. This case describes a 37-year-old man whose traumatic brain injury (TBI) resulted in severe right ankle spasticity and contracture. He was unable to stand due to severe right ankle spasticity and contracture. Intensive rehabilitation and STN allowed him to walk without brace at 6 months and run at 12 months after STN. STN is an effective procedure to resolve localized spasticity of the ankle and it may be considered as a management strategy after local injection to alleviate ankle spasticity and/or contracture prior to orthopaedic surgery.

**Key Words:** Ankle spasticity, contracture, brain injury, selective tibial neurotomy

## INTRODUCTION

The ankle spasticity of brain-injured patients often causes severe problems, especially in successful rehabilitation, because it leads to abnormal posture and joint contracture, making standing or walking impossible.<sup>1</sup> Spasticity is often defined as

a velocity-dependent increase in muscle tone characterized by hyperactive stretch reflex and it is one type of hypertonus that develops after upper motoneuron injury.<sup>2</sup> Local management procedures for relieving ankle spasticity include local injection procedures, such as chemical neurolysis using alcohol<sup>3-5</sup> or phenol<sup>6-8</sup> and botulinum toxin type A injection,<sup>9-12</sup> neurosurgical procedures, such as tibial neurectomy<sup>13</sup> or selective tibial neurotomy (STN),<sup>14-16</sup> and orthopedic procedures, such as tenotomy or tendon lengthening of the achilles tendon. Of these procedures, STN can selectively reduce ankle spasticity by partially resecting the motor nerve branches innervating the spastic muscles. Although it has several other significant advantages such as maintaining long-lasting effect and a low incidence of complication compared to other local management procedures, Sindou reported that the incidence of the most common complication, dysesthetic pain, was 12.9% (8/ 62).<sup>15</sup> However, the incidence of posterior tibial nerve block by using alcohol was 20% (4/21)<sup>5</sup> and by using phenol was 30% (3/10).<sup>7</sup> We consider that STN blocks the motor branches of the posterior tibial nerve, and that the incidence of dysesthetic pain of STN is lower than that of the posterior tibial nerve block by using alcohol or phenol. STN is not well known to Korea clinicians who manage ankle spasticity following brain injury. We report a quadriplegic patient with traumatic brain injury (TBI), who was initially unable to stand due to severe spasticity and contracture of the right ankle, yet who developed the ability to walk and then run

Received July 31, 2003

Accepted April 24, 2004

*This research was supported by a grant from the Neuroscience Association of Yeungnam University Medical Center.*

*Reprint address: requests to Dr. Sung Min Park, Department of Physical Medicine & Rehabilitation, College of Medicine, Yeungnam University, 317-1 Daemyungdong, Namku, Taegu 705-717, Korea. Tel: 82-53-620-3279, Fax: 82-53-625-3508, E-Mail: smseven@hanmail.net*

through STN and intensive rehabilitative management.

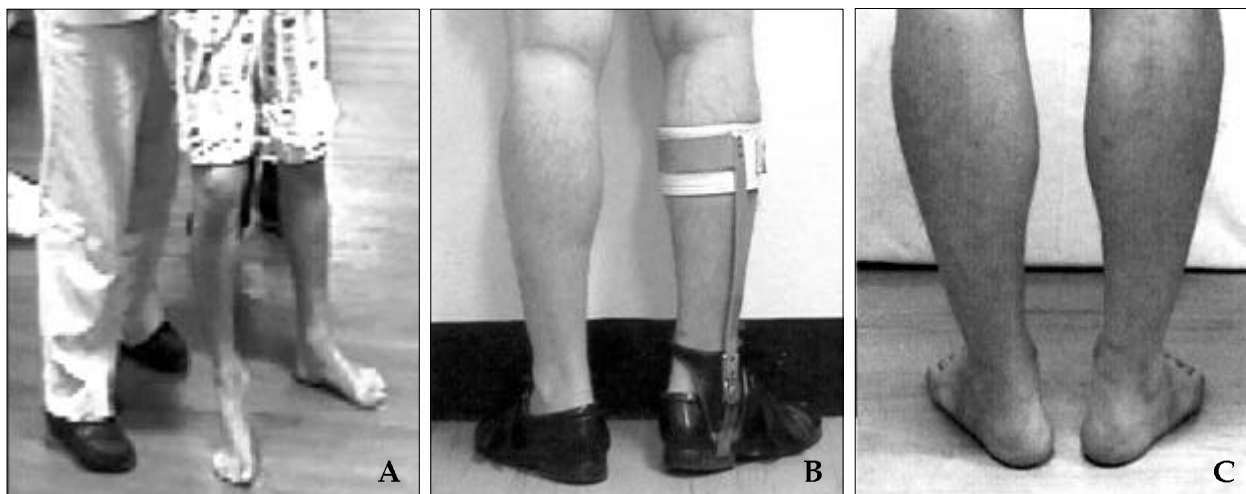
## CASE REPORT

A 37-year-old male patient who had suffered a traffic accident underwent craniectomy and hematoma removal for traumatic intracerebral hemorrhage and epidural hematoma on the left temporoparietal lobe at the department of neurosurgery in a university hospital. At 2 months after admission, he underwent a lumboperitoneal shunt operation due to hydrocephalus. He began to participate in rehabilitative management 11 months after admission. At that time, manual muscle testing revealed grossly G grade on both upper and lower limbs, except P grade on the right ankle dorsiflexor. He had an equinovarus deformity (30-degree plantar flexion contracture in passive range of motion) of the right ankle and a Modified Ashworth Scale (MAS)<sup>17</sup> score of 4 for his right ankle plantar flexors. The ankle contracture and spasticity made standing impossible for him (Fig. 1A). During 10 months of rehabilitative management, motor point blocks for the motor branch to gastrocnemius muscle with 3% phenol were performed 3 times to reduce the right ankle plantar flexor spasticity. After injec-

tion, the MAS score of the right ankle plantar flexor decreased from 4 to 2, ankle clonus disappeared and the passive range of motion of his right ankle dorsiflexion was improved from 30-degree plantar flexion to 15 degree; however, the strength of the ankle dorsiflexor was not improved. Furthermore, the effect was only temporary for 1 - 2 weeks and the patient had not experienced any improvement on a functional level through rehabilitative management before STN.

After STN, the MAS score of the right ankle plantar flexor decreased from 4 to 1, and ankle clonus completely disappeared. The strength of the ankle dorsiflexion was improved from P to P+ and the passive range of motion of his right ankle dorsiflexion was improved from 30-degree plantar flexion contracture to 15 degrees. The effect lasted at least 3 years.

STN was done to reduce right ankle plantar flexor spasticity at the department of neurosurgery in the same hospital, 21 months after initial admission. A skin incision was made vertically in the midline around the transverse popliteal line in an operation room. Each motor branch of the posterior tibial nerve was visually identified by each muscle contraction using electrical stimulation to its motor branches. Half to four-fifths of the selected motor branch was cut



**Fig. 1.** Standing posture of the quadriplegic patient with traumatic brain injury. This patient could not stand due to spasticity and contracture of the right ankle before selective tibial neurotomy (STN) (A). He could stand with a short leg brace with varus T-strap at 2 months after STN (B). The spasticity and contracture were markedly improved and he could stand without brace at 6 months after STN (C).

and an interval over 5 mm was inserted between the cut ends to prevent neuroma formation. The motor branches of the posterior tibial nerve to the gastrocnemius, soleus and tibialis posterior muscles were resected to reduce ankle clonus and plantar flexor spasticity with equinovarus deformity. At postoperative 3rd day, the patient started on rehabilitative management including stretching of the ankle plantar flexor and sitting balance training. After he underwent a total stitch-out at postoperative 2 weeks, the rehabilitative management focused on strengthening of the ankle dorsiflexors using neuromuscular electrical stimulation, standing balance training and stretching Achilles tendons using a wedge board. At that time, the MAS score of the right ankle plantar flexor decreased from 4 to 2 and ankle clonus completely disappeared after STN. The strength of the ankle dorsiflexor was improved from P (pre-STN) to P+. The passive range of motion of his right ankle dorsiflexion was improved from 30-degree plantar flexion contracture to 15 degrees. At 2 months after STN, the MAS score for the right ankle plantar flexor decreased from 4 (pre-STN) to 1+, and the strength of the ankle dorsiflexor was improved from P (pre-STN) to F+. The passive range of motion of his right ankle dorsiflexion was improved from 30-degree plantar flexion contracture (pre-STN) to 5 degrees. He began to stand and walk about 10 meters with a short leg brace with a varus T-strap attached. Varus controlled AFO lengthens the shortened tendons and improves the postural control (Fig. 1B). Gait training using a treadmill was begun at that time to enhance gait endurance. At 6 months after STN, he could walk without brace. The MAS score for the right ankle plantar flexor decreased from 4 (pre-STN) to 0, the strength of the ankle dorsiflexor was improved from P (pre-STN) to G-. The passive range of motion of his right ankle dorsiflexion was improved from 30-degree plantar flexion contracture (pre-STN) to 0 degrees (Fig. 1C). The strength of the right ankle dorsiflexor was improved from P (pre-STN) to G grade at 12 months after STN and he was able to run a short distance without brace. At 3 years after STN, he was able to walk and run without any evidence of aggravation of right ankle

plantar flexor spasticity.

## DISCUSSION

The patient in this case report could not stand or walk due to spasticity and contracture of the right ankle. Although he underwent rehabilitative management for about 10 months, commencing from 11 months after initial injury, there was no significant improvement on a functional level. However, intensive rehabilitative management after STN allowed him to walk independently with a short leg brace at 2 months after STN. He could walk without brace at 6 months and run at 12 months after STN. Considering that he had experienced no improvement on a functional level due to the right ankle problem prior to STN, it is apparent that STN was the turning point of his successful rehabilitation.

The management procedures for relieving ankle spasticity are grossly divided into non-surgical (motor point blocks using alcohol or phenol and neuromuscular junction block using botulinum toxin type A) and surgical (neurectomy, neurotomy, tendon lengthening, and tendon transfer). Motor point blocks are commonly used to alleviate ankle spasticity. Motor point blocks using alcohol or phenol have some advantages of cost effectiveness, and their effect duration is 6-12 months.<sup>7</sup> Botulinum toxin A features ease of injection and its effect duration is about 3-6 months. Although motor point blocks and botulinum toxin A injection gain some advantages from being noninvasive procedures, they do have several disadvantages, including their effect duration being shorter than that of STN. The administration of motor point blocks can be difficult when injecting into deep muscles and in cases of uncooperative patients. Botulinum toxin type A injection is expensive compared to other noninvasive procedures and may cause antibody formation following re-injection.<sup>18</sup> STN has the significant advantage of long-lasting effect. Sindou et al.<sup>15</sup> reported that its effect was long-lasting over one to ten years of follow-up. In our case, there was no evidence of aggravating spasticity at 3 years after STN. Although tendon surgery, such as tendon lengthening and teno-

tomy, is one of several surgical procedures can correct ankle contracture or deformity, it has a significant limitation in that it can not reduce ankle spasticity. However, STN can selectively reduce ankle spasticity. Because the equinus and clonus of the ankle originate from the medial and lateral gastrocnemius and soleus muscle, and the varus of that from the tibialis posterior,<sup>14,19</sup> the motor branches of the posterior tibial nerve which innervate the gastrocnemius, soleus and tibialis posterior muscles were resected in this patient.

Little<sup>20</sup> recommended tenotomy or tendon lengthening as a management strategy after phenol or alcohol injection for localized spasticity. We performed STN as the first procedure to relieve ankle spasticity in this patient and planned to consider tendon surgery for residual contracture at about 6-12 months after STN. However, orthopaedic surgery was not necessary because the contracture was markedly improved through STN and rehabilitative management. Therefore, in agreement with the opinion of Sindou et al.,<sup>16</sup> it seems logical to perform peripheral selective neurotomy as a first step among invasive procedures if spasticity and contracture are combined. If there is any residual contracture that inhibits function after intensive rehabilitative management, it should be corrected by orthopedic surgery. STN has another advantage in allowing the earlier commencement of rehabilitative management. Most orthopaedic surgery requires casting after operation which delays early rehabilitation; STN, however, does not. In this case, the patient began simple exercise at the third postoperative day and was able to undergo active rehabilitative management after the time of stitching out; 2 weeks after STN.

Although STN has some disadvantages of requiring anesthesia to operate and anticoagulant therapy for 7-10 days to prevent deep vein thrombosis,<sup>15</sup> it is an effective procedure to resolve localized spasticity of the ankle. We suggest that STN may be considered as a management strategy after local injection to alleviate ankle spasticity and/or contracture prior to orthopaedic surgery, as in this patient.

## REFERENCES

1. Botte MJ, Nickel VL, Akeson WH. Spasticity and contracture: physiologic aspects of formation. *Clin Orthop* 1988;233:7-19.
2. Lance JW: Symposium synopsis in Feldman RG, Young RR, Koella WP: spasticity: Disordered Motor Control, Chicago, Year Book; 1980. p.485-94.
3. Carpenter EB, Seitz DG. Intramuscular alcohol as an aid in the management of spastic cerebral palsy. *Dev Med Child Neurol* 1980;22:497-501.
4. Chua KSG, Kong K-H. Alcohol neurolysis of the sciatic nerve in the treatment of hemiplegic knee flexor spasticity: clinical outcomes. *Arch Phys Med Rehabil* 2000;81:1432-5.
5. Chua KSG, Kong K-H. Clinical and functional outcome after alcohol neurolysis of the tibial nerve for ankle-foot spasticity. *Brain Inj*, 2001;15:733-9.
6. Halpern D., Meelhuysen F.E. Phenol motor point block in the management of muscle hypertonia. *Arch Phys Med Rehabil*. 1966;47:659.
7. Kirazli Y, On AY, Kismali B, Aksit R. Comparison of phenol block and botulinum toxin type A in the treatment of spastic foot after stroke: a randomized, double-blind trial. *Am J Phys Med* 1998;9:510-5.
8. Petrillo CR, Knoploch S. Phenol block of the tibial nerve for spasticity: a long-term follow-up study. *Internal Disability Study* 1988;10:97-100.
9. Grazko MA, Polo KB, Jabbari B. Botulinum toxin A for spasticity, muscle spasm, and rigidity. *Neurology* 1995; 45:712-7.
10. Reichel G. Botulinum toxin for treatment of spasticity in adults. *J Neurol* 2001;248 Suppl 1:25-7.
11. Oates JA, Wood AJJ. Therapeutic uses of botulinum toxin. *N Engl J Med* 1991;324:1186-94.
12. Simpson DM. Clinical trials of botulinum toxin in the treatment of spasticity. *Muscle Nerve* 1997;20 Suppl 6: S169-75.
13. Stoffel A. The treatment of spastic contractures. *Am J Orthop* 1912;10:611-3.
14. Philippe Decq, Paul Filipetti, Alexandro Cubillos, Velislav Slavov. Soleus neurotomy for treatment of the spastic equinus foot. *Neurosurgery* 2000;47:1154-61.
15. Sindou M, Mertens P. Selective neurotomy of the tibial nerve for treatment of the spastic foot. *Neurosurgery* 1988;23:738-44.
16. Sindou MP. Mertens P. Neurosurgery for spasticity. *Stereotact Funct Neurosurg* 2000;74:217-21.
17. Bohannon RW, Smith MB. Interrater reliability of a modified Ashworth scale of muscle spasticity. *Phys Ther* 1986;67:206-7.
18. Zuber M, Sebald M, Bathien N, Recondo JD, Rondot P. Botulinum antibodies in dystonic patients treated with type A botulinum toxin: Frequency and significance. *Neurology* 1993;43:1715-8.
19. Msaddi AK, Mazroue AR, Shahwan S, al Amri N, Dubayan N, Livingston D, et al. Microsurgical selective

peripheral neurotomy in the treatment of spasticity in cerebral-palsy children. *Stereotact Funct Neurosurg* 1997;69:251-8.

20. Delisa JA, Grans BM. *Rehabilitation medicine: principles and practice*, 3rd ed. Lippincott-Raven; 1988. p.1007-9.