

# Radiological Considerations of Posterior Cervical Lateral Mass Fixation Using Plate and Screw

Seung-Hwan Yoon<sup>1</sup>, Hyung-Chun Park<sup>1</sup>, Heon-Seon Park<sup>1</sup>, Eun-Young Kim<sup>1</sup>, Yoon Ha<sup>1</sup>,  
Chong-Kweon Chong<sup>2</sup>, Seung-Min Kim<sup>3</sup>, and Dae-Cheol Rim<sup>4</sup>

Departments of <sup>1</sup>Neurosurgery and <sup>2</sup>Anesthesiology, Inha University Hospital, College of Medicine, Inha University, Incheon, Korea;

<sup>3</sup>Department of Neurosurgery, Kosin Medical School, Gospel Hospital, Pusan, Korea;

<sup>4</sup>Department of Neurosurgery, Hallym University Hospital, College of Medicine, Hallym University, Pyungchon, Korea.

The aim of this study is to determine whether the posterior cervical fusion methods with the plate-screw system applied to the lateral mass of cervical spine are radiologically safe to patients. The lateral cervical X-rays and CT scans were done on 40 normal adults without cervical problem. Based on Roy-Camille and Magerl's method, the theological trajectory of screw was shown on films and the parameters were measured. The study based on Roy-Camille's method showed less than one percent chance of injury on the facet joint and the mean depth of the screw to be  $10.5 \pm 1.4$  mm. On the other hand, Magerl's method showed the mean depth of screw to be  $11.9 \pm 1.5$  mm which is slightly larger than that of Roy-Camille's method and no chance of facet injury occurred. A reduced lateral angle of screw ( $19.6 \pm 3.5^\circ$ ) performed with the concept based on Magerl's method resulted a longer depth of screw ( $13.5 \pm 2.1$  mm). Both Roy-Camille and Magerl's methods seemed to be radiologically safe to normal persons. However, the authors recommend the reduced lateral angle ( $19.6 \pm 3.5^\circ$ ) of screw based on the Magerl's method more than an original Magerl's methods.

**Key Words:** Posterior cervical fusion, plate-screw system, lateral mass, facet joints, facet injury

## INTRODUCTION

The causes of instability of cervical spine include trauma, extensive laminectomy state, and destruction by tumor.<sup>1-6</sup> The purpose of treatment

for the instability is to maintain the anatomical alignment of cervical spine and induce the fusion of cervical spine and early rehabilitation management in consequence, and posterior fixation is one of commonly accepted surgical methods.<sup>3-7</sup> Out of the techniques of posterior fixation of cervical spine, interspinous wiring was once mainly used, but recently the fixation methods using plate-screw became popular.<sup>8</sup> The interspinous wiring method is impossible to apply when spinous process is compromised or absent because of fracture or postlaminectomy state.<sup>3,7,9,10</sup> Moreover, the fixation by using plate-screw is more useful when multi-level cervical spines need to be fixed.<sup>3,7,9-12</sup>

There have been many studies on the anatomical considerations in surgery or the techniques in the posterior screw fixation of cervical spine according to the technique of Roy-Camille and Magerl's methods,<sup>13-18</sup> however, both surgical methods have placed at risk for injury to the spinal cord,<sup>7,14,16</sup> vertebral artery,<sup>9,19</sup> cervical nerve root<sup>5,13,15</sup> and facet joint.<sup>15,20</sup>

The authors analyzed the radiological considerations in those two posterior fixation methods of cervical spine using plates and screws based on the radiographs and the CT scans of cervical spine, and examined whether both methods could be radiological safe to the normal persons.

## MATERIALS AND METHODS

After informed consent was obtained, the persons were asked to volunteer for the study. The

Received October 31, 2003

Accepted May 10, 2004

This work was supported by Inha University Research Grant.

Reprint address: requests to Dr. Seung-Hwan Yoon, Department of Neurosurgery, Inha University Hospital, 7-206, 3 Ga, Shinheung-dong, Jung-gu, Incheon 400-711, Korea. Tel: 82-32-890-3508, Fax: 82-32-890-2947, E-mail: nsysh@inha.ac.kr

ethical committee of the hospital approved the study. The subjects were normal persons who had neither neck pain nor neurological symptoms originated from cervical spine without abnormal findings in the plain cervical spine x-rays.

The mean age of randomized 40 persons was 38.8 years old and sex distributions were equal. While the cervical simple x-rays were taken in natural standing position, the CT scans (HiSpeed ADV, GE Medical Systems, USA) were taken in prone, neutral position in order to produce a similar condition to the operation. The CT scans were performed from the third (C3) to the seventh cervical spine (C7) at intervals of 1 mm, and two kinds of angles were selected for both Roy-Camille and Magerl's methods.

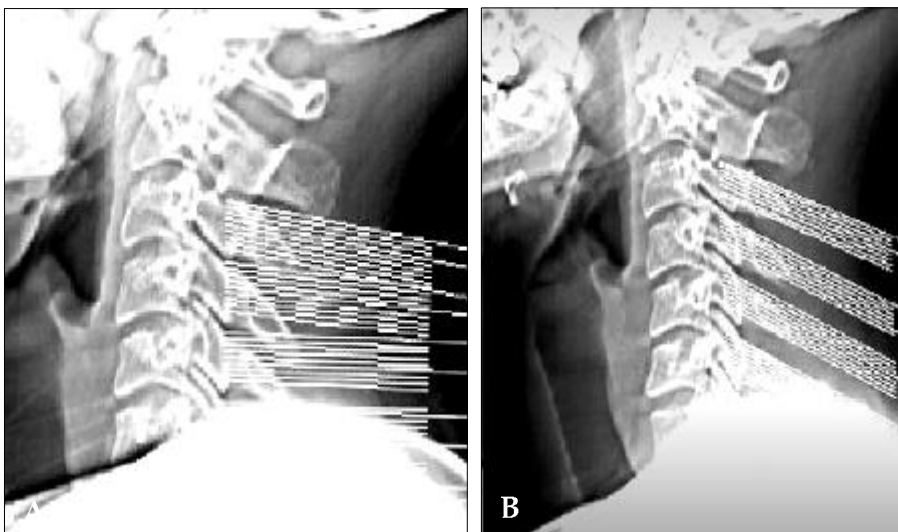
In Roy-Camille's method, the plane meeting perpendicularly with the line connecting the posterior margin of body was selected; in Magerl's method, the plane was taken which paralleled the superior articular surface (Fig. 1). The images were developed for the bone setting revealing bone tissue, and the size of lateral mass and the proper insertion point of screw were measured based on the below two methods. In Roy-Camille's method, the central point of the four boundaries of lateral mass was selected to be the insertion point of screw, and the entrance point of screw in Magerl's method was 1 mm medial to and 1 mm superior to the central point. The lateral angles for inserting screw were to be respectively 10° and 25° in both methods, and the real depths

of screws in bones were also measured in the CT scans. In addition, the ideal imaged angle, which would make the depth the screw deeper, was measured in Magerl's method. The anticipated locations of screws were confirmed in 200 simulated drawings on our cases ourselves in both methods, and were compared with the locations of vertebral artery and spinal canal. TALL statistical analysis was done using SPSS (version 8.0, SPSS Inc., Chicago, IL, USA).

The radiological data according to each levels and methods on the CT scans were analyzed using the Student T-test. Statistical significance was determined at *p* values less than 0.05.

## RESULTS

The mean sizes of the lateral mass were  $10.1 \pm 0.8$  mm in width and  $12.0 \pm 2.9$  mm in length (Table 1). The expected mean depths of screw were  $10.5 \pm 1.4$  mm in Roy-Camille's method, and  $11.9 \pm 1.5$  mm in Magerl's method, but there was not significant difference (Table 2). On the other hand, lateral mass of C7 was relatively thin and acute posterior angle (Fig. 2). Especially, the mean depths of screw in C7 in Roy-Camille's method was  $9.1 \pm 1.7$  mm, significant shorter than the mean depths in Magerl's methods ( $p=0.02$ ) ( $12.6 \pm 1.6$  mm), and one case out of 200 simulated drawings expected courses of screws in Roy-Camille's method was estimated to be injured facet joint



**Fig. 1.** The CT scans were performed from C3 to C7 at intervals of 1 mm, and two kinds of angles were selected for both Roy-Camille (A) and Magerl's (B) methods. In Roy-Camille's method, the plane meeting perpendicularly with the line connecting the posterior margin of body was selected; in Magerl's method, the plane was taken which paralleled the superior articular surface.

**Table 1.** Mean Data of Width and Length Of Lateral Mass Measured from 40 Normal Persons

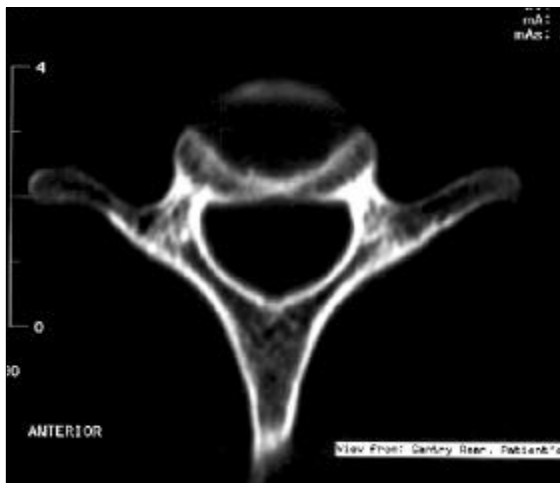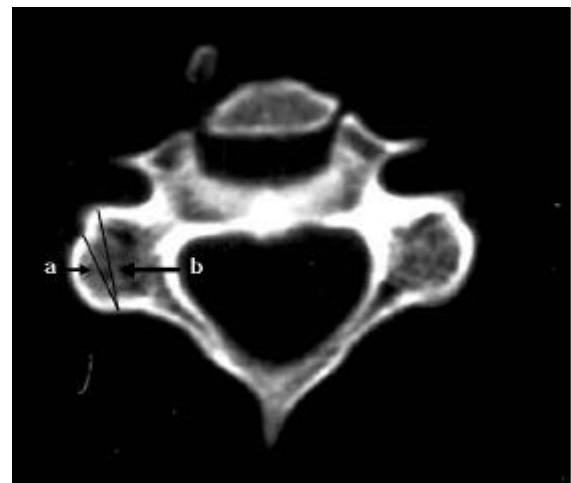Level	Width	Length
	Mean $\pm$ SD(mm)	Mean $\pm$ SD(mm)
C3	10.0 $\pm$ 0.5	12.1 $\pm$ 2.4
C4	9.9 $\pm$ 0.9	11.9 $\pm$ 2.6
C5	10.8 $\pm$ 1.1	13.4 $\pm$ 4.5
C6	10.4 $\pm$ 0.5	12.3 $\pm$ 3.5
C7	9.7 $\pm$ 1.1	10.5 $\pm$ 1.5

No significant difference of mean width and length of each level.

**Table 2.** Mean Depth of Screw Measured on Each Cervical Vertebrae as Roy-Camille or Magerl's Methods on the CT Scans

Level	Roy-Camille's method	Magerl's method
	Mean $\pm$ SD (mm)	Mean $\pm$ SD (mm)
C3	10.9 $\pm$ 1.2	11.0 $\pm$ 0.9
C4	11.3 $\pm$ 1.7	12.5 $\pm$ 1.9
C5	10.9 $\pm$ 1.2	11.4 $\pm$ 1.0
C6	10.2 $\pm$ 1.4	12.0 $\pm$ 1.8
C7	9.1 $\pm$ 1.7 <sup>†</sup>	12.6 $\pm$ 1.6

<sup>†</sup>Significant difference of mean depth of screw on C7 level ( $p$ -value: 0.02) between two methods. No other significant difference in another levels between two methods.

**Fig. 2.** The CT scans shows the characteristics of C7. Lateral mass is relatively thin and acute posterior angle.**Fig. 3.** (a) The theological trajectory of screw with lateral angle of 25 degrees based on Magerl's method. (b) The theological trajectory of screw with maximal depth (The lateral angle is smaller than 25 degrees).

(Table 2). The lateral angle of screw in Magerl's method was originally 25°, however, as an application of Magerl's method, an ideal lateral angle that maximized the depth and avoid injuring vertebral artery in CT scan was  $19.6 \pm 3.5^\circ$  and the maximal depth of screw like that was  $13.5 \pm$

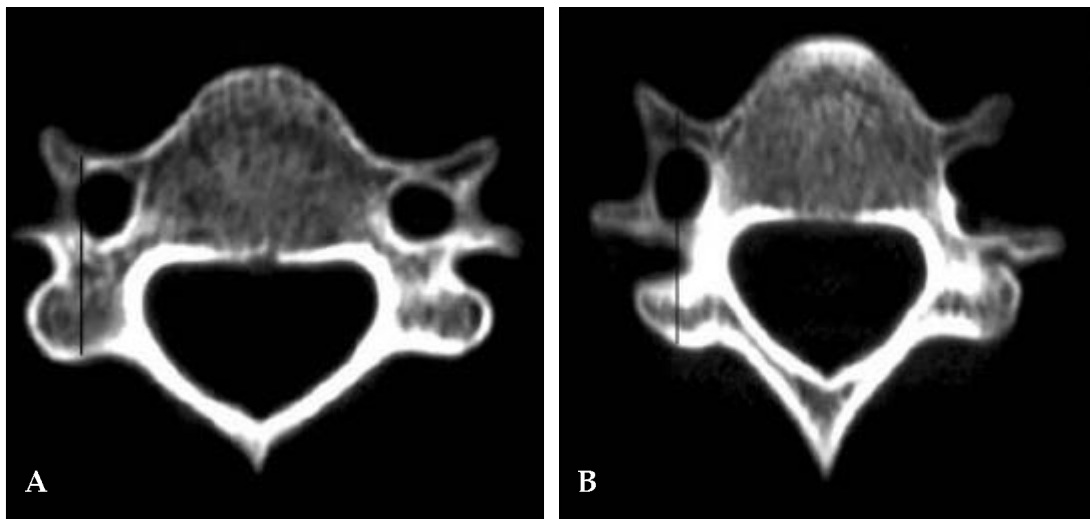
2.1 mm in this study, which was significantly deeper than the measurement based on the original method ( $11.9 \pm 1.5$  mm) ( $p$ -value: 0.044) (Fig. 3) (Table 3). The results of measuring the angles of screws against the sagittal plane differed in each

**Table 3.** Ideal Lateral Angle and Maximized Depth of Screw on Modified Magerl's Method and the Angles of Screws Against the Sagittal Plane in the Cervical Spine

Level	Ideal angle <sup>†</sup> Mean $\pm$ SD(angle)	Maximized depth Mean $\pm$ SD(mm)	Sagittal angle <sup>‡</sup> Mean $\pm$ SD(angle)
C3	19.4 $\pm$ 3.5	12.2 $\pm$ 1.2	41.0 $\pm$ 2.8
C4	19.0 $\pm$ 3.8	14.3 $\pm$ 2.1	39.0 $\pm$ 5.1
C5	20.2 $\pm$ 3.0	13.9 $\pm$ 2.0	42.8 $\pm$ 4.5
C6	18.1 $\pm$ 3.2	14.0 $\pm$ 3.6	46.8 $\pm$ 6.1
C7	21.1 $\pm$ 3.9	13.1 $\pm$ 1.6	50.2 $\pm$ 4.2

<sup>†</sup>Ideal angle: imaginary angle that maximized the depth and avoid injuring vertebral artery in CT scans.

<sup>‡</sup>Sagittal angle: according to the direction of screw in Magerl's method to be measured parallel superior articular surface.



**Fig. 4.** (A) Vertebral foramina of C4 are situated medial to the posterior center of lateral mass (screw entry point). (B) Vertebral foramina of C6 are situated anterior to the posterior mid-point of the lateral mass.

cervical spine ( $43.9 \pm 4.5^\circ$  in average value), and the lower cervical spine had the larger angle (Table 3). The angle was the direction of screw in Magerl's method parallel angle superior articular surface. The intervals between the insertion points of screw were  $15.9 \pm 1.6$  mm on C3-4,  $19.3 \pm 1.6$  mm on C4-5,  $16.7 \pm 2.0$  mm on C5-6,  $15.3 \pm 3.1$  mm, and the mean interval was  $16.8 \pm 2.0$  mm. All the insertion points of screws from the C3 to C7 were located on lateral side to spinal canal, and were situated more medial and ventral side than all the vertebral foramen in vertebral artery positioned, except for C7 (Fig. 4).

## DISCUSSION

The well-known techniques of the posterior fixation of cervical spine using plate and screw include Roy-Camille,<sup>1,11,16,21</sup> Magerl<sup>14,18,19</sup> have been reported. Both methods viewas little difference in postoperative infection, psuedoarthrosis, and system failure, and the occurrence rate was.<sup>20,22,23</sup> However, anatomical and clinical results have been warned surgeons to the risk of radiculopathy, facet violations, vertebral artery injury, and spinal cord.<sup>9,24-26</sup>

There were no serious complications associated with placement of the screws in this radiological study. Lateral mass plating was associated with

no vertebral artery or spinal cord injury. Because the spinal cord, as seen in our results, was located toward the medial side compared to the insertion point of screw and the direction of screw was supposed to be inserted toward the lateral side, theoretically, there could not injure in spinal cord and vertebral artery. The entry points of screw of C3, C4, C5, and C6 were located in the posterior side to the vertebral foramen in which vertebral artery was passed.<sup>17</sup> In addition, because all the screws used in the above methods were directed toward the lateral side, the results of this study can be sufficient evidence for the low probability of the injury in vertebral artery. However, it is difficult to say that the above conclusion can also apply for C7 without vertebral foramen, but as long as the inserted screw do not pierce the anterior portion of lateral mass, the occurrence of vertebral artery injury is also rare in C7. Xu et al. also reported the same results by cadaver study.<sup>17</sup>

The complications related to the anatomical structure adjacent to screws were shown differently between the Roy-Camille and Magerl's techniques, facet injury (especially C7) occurred when Roy-Camille's method was applied, and root injury was reported when Magerl's technique was used.<sup>13,15,18,25,27</sup> The authors could not show the cervical root in the Magerl's technique of this radiological study. The location of cervical root was expected to be the lateral-anterior side of the superior-lateral junction of the superior articular process, as mentioned by Xu et al.,<sup>17</sup> therefore, in even Magerl's method, the safety can be secured so long as the inserted screw is not exceedingly toward the lateral side and too deep to penetrate the anterior portion of the surface of the bone.<sup>15,25</sup> In this study, out of the total simulated 200 screws inserted in C7 by Roy-Camille's technique, only one screw (0.5%) was expected to injury facet joint on CT scans. Given that such a result is similar to those of other study (less than 1 - 2%).<sup>15</sup>

The results of comparing the values in this study with those in the other studies<sup>11,15,27</sup> when Roy-Camille's method was applied are the followings. Comparing the expected lateral angles of screws on CT scans with the depths of screws in lateral mass, we concluded that about 10° was the most appropriate angle for the lateral angle but could not find an ideal angle for deepening the

depth of screws. The depth of screw was  $10.2 \pm 1.6$  mm, showing a difference when compared to the report of Ebraheim et al.<sup>14</sup> stating 14-15 mm in C6 and 13.8 mm in C7. The results of comparing the values in this study with those in the studies<sup>14,18</sup> when Magerl's method was applied are the followings. While the paralleling angle with the superior articular process, or the angle of screw against sagittal profile, was reported to be about 45°, the angle in this study was  $43.9 \pm 4.5^\circ$  against the line which was perpendicular to the line connecting the posterior margin of vertebral body, and the lower the location of cervical spine was, the larger the angle was. In other words, the sagittal angle of screw should be larger in the lower cervical vertebrae. The lateral angle was originally 25°, and we additionally measured the ideal lateral angle which minimized the injury in vertebral artery in CT scans and maximized the depth of screw, as a modified Magerl method. The ideal lateral angle maximizing the depth was about 19.6° in average, showing a difference from 25° in original method. Similarly, the average depth of screw was different:  $11.9 \pm 1.5$  mm when the lateral angle was 25°, and  $13.5 \pm 2.1$  mm when the ideal lateral angle maximizing the depth of screw was applied. Therefore, it is safe to say that the lateral angle should be reduced about 20°. However, the mean depths of screw were short, compared to that in other report,<sup>14</sup> 15 - 17 mm. Also, there are other variables on such a surgery: firstly, the cervical vertebra of Asians are smaller than those of white man, and secondly, the values in this study are those in CT scans so that they may be different from those gained after measuring cadaver bones, given the soft tissue around lateral mass.

The characteristics of C7 were also determined in this study. Firstly, the length of the lateral mass was shorter than that of other cervical vertebra and the depth of screw in Roy-Camille's method was also shorter, indicating the comparatively high possibility of the injury in facet joint when a screw was inserted. Secondly, when compared at the sagittal profiles, the angle of the superior articular process was significantly larger than that of other cervical spines indicating the need of more sagittal angle when Magerl's method was used. Thirdly, the screw application might give

difficulty because of characteristics as followings, the border between the lateral mass and the lamina was not apparent, and the steep inclination of lateral mass was observed. Given the above considerations, the screw application on pedicle like the thoracic spine can be more effective or safe in C7 vertebrae.<sup>13,25</sup>

The distance between the insertional points of screws should be mentioned though it has been rarely considered importantly in other reports. The intervals of the screws were  $16.8 \pm 2.0$  mm, showing difference by individuals. The actual position of cervical spines could be different by patients, and there are studies reporting such differences based on individuals. Given the above differences and those shown in this study, the value cannot be stated as absolute one. However, the value should be considered in designing plates because the intervals of holes of plates should correspond to it.

Applying the Roy-Camille and Magerl's techniques in the posterior fixation of cervical spines is available based on the results of simple x-rays and CT scans. However, the facts such as that the actual depths of screws are shallower in Asians than those in white man and that the ideal lateral angle of the insertion direction is less than  $20^\circ$  in order to deepen the depth of screw when Magerl's method is applied should be considered.

## REFERENCES

1. Borne G, Bedou G, Pinaudeau M, el Omeiri S, Cristino G. Treatment of severe lesions of the lower cervical spine (C3-C7). A clinical study and technical considerations in 102 cases. *Neurochirurgia (Stuttg)* 1988;31: 1-13.
2. Cooper PR, Cohen A, Rosiello A, Koslow M. Posterior stabilization of cervical spine fractures and subluxations using plates and screws. *Neurosurgery* 1988;23: 300-6.
3. Ebraheim NA, An HS, Jackson WT, Brown JA. Internal fixation of the unstable cervical spine using posterior Roy-Camille plates: preliminary report. *J Orthop Trauma* 1989;3:23-8.
4. Fehlings MG, Cooper PR, Errico TJ. Posterior plates in the management of cervical instability: long-term results in 44 patients. *J Neurosurg* 1994;81:341-9.
5. Honnart F, Patel A, Furno P. Fractures of cervical spine with neurological lesion treated by reduction and fixation with plates. *Ann Acad Med Singapore* 1982; 11:186-93.
6. Nazarian SM, Louis RP. Posterior internal fixation with screw plates in traumatic lesions of the cervical spine. *Spine* 1991;16(3 Suppl):S64-71.
7. Anderson PA, Henley MB, Grady MS, Montesano PX, Winn HR. Posterior cervical arthrodesis with AO reconstruction plates and bone graft. *Spine* 1991;16(3 Suppl):S72-9.
8. Schlicke LH, Schulak DJ. Wiring of the cervical spinous processes. *Clin Orthop* 1981;154:319-20.
9. Wellman BJ, Follett KA, Traynelis VC. Complications of posterior articular mass plate fixation of the subaxial cervical spine in 43 consecutive patients. *Spine* 1998;23: 193-200.
10. Domenella G, Berlanda P, Bassi G. Posterior-approach osteosynthesis of the lower cervical spine by the R. Roy-Camille technique. (Indications and first results). *Ital J Orthop Traumatol* 1982;8:235-44.
11. Roy-Camille RSG, Mazel C. Internal fixation of the unstable cervical spine by a posterior osteosynthesis with plates and screws. In: Sherk HH, Dunn HJ, Eismont FJ, et al, editors. *The cervical spine*. 2nd ed. Philadelphia: JB Lippincott, Inc; 1989. p.390-404.
12. Savini R, Parisini P, Cervellati S. The surgical treatment of late instability of flexion-rotation injuries in the lower cervical spine. *Spine* 1987;12:178-82.
13. An HS, Gordin R, Renner K. Anatomic considerations for plate-screw fixation of the cervical spine. *Spine* 1991;16(10 Suppl):S548-51.
14. Ebraheim NA, Klausner T, Xu R, Yeasting RA. Safe lateral-mass screw lengths in the Roy-Camille and Magerl techniques. An anatomic study. *Spine* 1998;23: 1739-42.
15. Heller JG, Carlson GD, Abitbol JJ, Garfin SR. Anatomic comparison of the Roy-Camille and Magerl techniques for screw placement in the lower cervical spine. *Spine* 1991;16(10 Suppl):S552-7.
16. Roy-Camille R, Saillant G, Laville C, Benazet JP. Treatment of lower cervical spinal injuries--C3 to C7. *Spine* 1992;17(10 Suppl):S442-6.
17. Xu R, Ebraheim NA, Nadaud MC, Yeasting RA, Stanescu S. The location of the cervical nerve roots on the posterior aspect of the cervical spine. *Spine* 1995; 20:2267-71.
18. Xu R, Haman SP, Ebraheim NA, Yeasting RA. The anatomic relation of lateral mass screws to the spinal nerves. A comparison of the Magerl, Anderson, and An techniques. *Spine* 1999;24:2057-61.
19. Ebraheim NA, Hoeflinger MJ, Salpietro B, Chung SY, Jackson WT. Anatomic considerations in posterior plating of the cervical spine. *J Orthop Trauma* 1991;5: 196-9.
20. Coe JD, Warden KE, Sutterlin CE, 3rd, McAfee PC. Biomechanical evaluation of cervical spinal stabilization methods in a human cadaveric model. *Spine* 1989;14:1122-31.
21. Roy-Camille R. Methods of osteosynthesis with posterior screw plates. In: Laurin CA, Riley LH, Roy-

- Camille R, editors. Atlas of Orthopaedic Surgery. Chicago: Yearbook Medical Publishers; vol. 1, 1989. p.373-6.
22. Sutterlin CE, 3rd, McAfee PC, Warden KE, Rey RM, Jr., Farey ID. A biomechanical evaluation of cervical spinal stabilization methods in a bovine model. Static and cyclical loading. *Spine* 1988;13:795-802.
23. Ulrich C, Woersdoerfer O, Kalff R, Claes L, Wilke HJ. Biomechanics of fixation systems to the cervical spine. *Spine* 1991;16(3 Suppl):S4-9.
24. Chapman JR, Anderson PA, Pepin C, Toomey S, Newell DW, Grady MS. Posterior instrumentation of the unstable cervicothoracic spine. *J Neurosurg* 1996;84: 552-8.
25. Graham AW, Swank ML, Kinard RE, Lowery GL, Dials BE. Posterior cervical arthrodesis and stabilization with a lateral mass plate. Clinical and computed tomographic evaluation of lateral mass screw placement and associated complications. *Spine* 1996;21:323-8; discussion 329.
26. Heller JG, Silcox DH, 3rd, Sutterlin CE, 3rd. Complications of posterior cervical plating. *Spine* 1995;20: 2442-8.
27. Choueka J, Spivak JM, Kummer FJ, Steger T. Flexion failure of posterior cervical lateral mass screws. Influence of insertion technique and position. *Spine* 1996; 21:462-8.