

Intestinal and Multivisceral Transplantation

Jang Il Moon and Andreas G. Tzakis

Division of Liver and GI Transplant, Department of Surgery, University of Miami School of Medicine, Miami, FL, USA.

Intestinal transplantation has been established as a treatment option for patients that suffer from intestinal failure with complications from total parenteral nutrition. It is still rapidly evolving and just reached a landmark of 1,000 cases worldwide. Intestinal allografts can be transplanted as isolated, combined with the liver or as a part of a multivisceral allograft. Tacrolimus-based immunosuppression regimens have been used universally with improved outcomes. Clinical outcome in intestinal transplantation has improved significantly over time, impacted by refinement of surgical technique and novel immunosuppression. However rejection, infection, and technical complications still remain the most difficult barrier to improve patient and graft survival.

Key Words: Intestinal transplantation, multivisceral transplantation

INTRODUCTION

Total parenteral nutrition (TPN) has significantly prolonged survival and has been established as a main treatment option for the patients with intestinal failure.¹ However, TPN related complications such as central venous catheter infection leading to intractable sepsis, venous thrombosis causing loss of venous access, and cholestatic liver resulting in cirrhosis are not uncommon.² Intestinal transplantation is indicated in this group of patients to prolong life span and improve quality of life.³⁻⁷ Intestinal allografts are generally classified into three types: isolated intestinal graft, combined liver and intestinal graft, and multivisceral graft (Fig. 1). Each type of

graft can be modified by the patient's need and clinical situation. This article reviewed general principles of intestinal and multivisceral transplantation, which includes indication, surgical techniques, posttransplant management, and outcome.

INDICATIONS

Thus far, intestinal or multivisceral transplantation is only indicated when patients with intestinal failure develop TPN related complications, which results in life-threatening conditions. Intestinal failure, defined as inability of the intestine to maintain nutrition and/or positive fluid and electrolyte balance without parenteral support, develops secondary to either loss of absorptive surface or dysfunction of the native small intestine.⁸⁻¹⁰ Congenital anomalies and ischemic injury to the intestine are major causes of the intestinal failure in children. In adults, extensive bowel resection resulting from various diseases such as Crohn's disease, mesenteric vascular thrombosis, abdominal trauma, or desmoid tumor is the most common cause of intestinal failure. Congenital mucosal disorders and Intestinal motility disorders also contribute to intestinal failure.^{11,12} Table 1 summarizes the common causes of intestinal failure, leading to intestinal or multivisceral transplantation.¹³⁻¹⁸

Intestinal failure patients can maintain reasonable quality of life with TPN if the treatment is not complicated. Isolated intestinal transplantation could be indicated before liver failure occurs. If intestinal failure patients develop end stage liver disease, liver transplant is necessary in combination with the intestinal allograft. Sometimes the

Received October 2, 2004

Reprint address: requests to Dr. Jang Il Moon, Department of Surgery, University of Miami School of Medicine, Highland Professional Bldg., Suite 508, 1801 N.W., 9th Ave., Miami, Florida, 33136, U.S.A. Tel: 305-355-5020, Fax: 305-355-5124, E-mail: jmoon@med.miami.edu

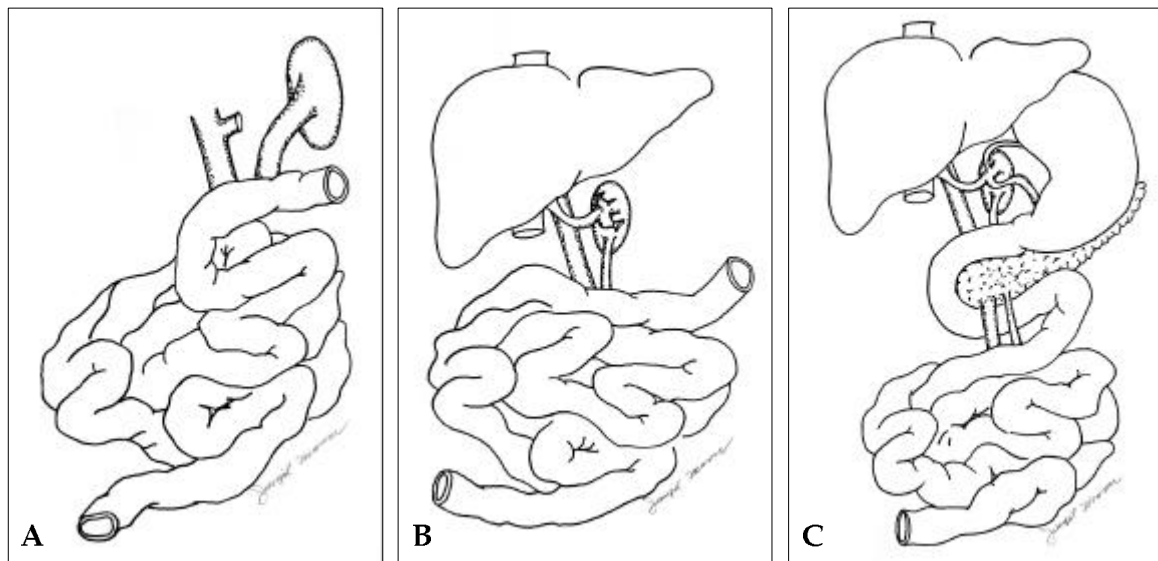


Fig. 1. General classification of intestinal allografts. (A) isolated intestinal allograft, (B) liver-intestinal allograft, (C) multivisceral allograft.

Table 1. Common Causes of Intestinal Failure in Recipients of Intestinal or Multivisceral Transplantation

Children	Adults
Midgut volvulus (malrotation)	Mesenteric thrombosis
Gastroschisis	Crohn's disease
Necrotizing enterocolitis	Intra-abdominal desmoid tumor
Intestinal atresia	Intestinal trauma
Chronic intestinal pseudo-obstruction	Pseudo-obstruction
Microvillus inclusion disease	Midgut volvulus
Intestinal polyposis	
Hirschsprung's disease	

pancreas is included in this composite graft to avoid difficult biliary anastomosis and/or graft portal vein complications.^{19,20} If the patients have severe adhesions or fistulas in the upper abdomen, the stomach and pancreas need to be removed. In this case, multivisceral transplantation including a liver and stomach/pancreas complex with the intestinal graft is indicated. This multivisceral transplantation can be modified without the liver allograft if there is no evidence of liver disease. Kidney(s) can also be included in a multivisceral graft depending on renal function.

TRANSPLANT SURGERY

Eviscerectomy

It is important to remove diseased organ and create proper space for the allograft. Most of intestinal failure patients have severe intra-abdominal adhesion due to extensive history of abdominal surgeries. Significant bleeding is expected during dissection before the surgeon obtains proper surgical field and removes the diseased organ. Clamping of the root of the celiac and superior mesenteric arteries can minimize bleeding when multivisceral transplantation is planned.^{21,22} Intra-luminal embolization of those

arteries immediate before transplant surgery would be an alternative option to reduce bleeding. Hepatectomy using a "piggyback" method can be performed without veno-venous bypass.

Vascular anastomosis. If the allograft contains the liver, there is no need for the graft portal reconstruction. This type of allograft only requires suprahepatic cava anastomosis into the recipient's vena cava (hepatic piggyback anastomosis). In the isolated intestinal allograft, the donor portal or superior mesenteric vein is anastomosed to the side of the recipient's main portal vein at the hepatic hilum (intestinal piggyback anastomosis)²³ or to the distal end of the superior mesenteric vein. In addition to this portal drainage, the donor vein can be drained into the recipient's cava (systemic drainage) without significant metabolic consequences.^{24,25} The arterial anastomosis is commonly performed with an arterial conduit into the supraceliac or infrarenal aorta of the recipient.²²

Gastrointestinal tract reconstruction

There are wide variations in reconstruction of the gastrointestinal tract. Depends on graft type, the proximal anastomosis is either a jejunojunction or esophagogastrostomy. A defunctionalized limb of the donor jejunum can be used for biliary reconstruction and/or tube jejunostomy if necessary. A pyloroplasty should be performed in the transplanted stomach. The distal anastomosis of the gastrointestinal tract can be flexibly adjusted to the recipient's condition. An end ileostomy with a side-to-end ileocolostomy (Bishop-Koop type), a double barrel ileostomy-colostomy (Mikulicz type), or a loop ileostomy are common types (Fig. 2, Table 2).

Abdominal wall closure

Patients with short gut syndrome often present with contracted small abdominal cavity, which leads to difficult abdominal wall closure. There are few alternatives to achieve this goal:²⁶ reduction of the size of the graft using partial resection of the liver or intestine,²⁷ closure with mesh and staged approximation, using abdominal wall stretcher (presented at 4th Annual Winter Symposium of ASTS, Scottsdale, AZ, Jan, 2004), or

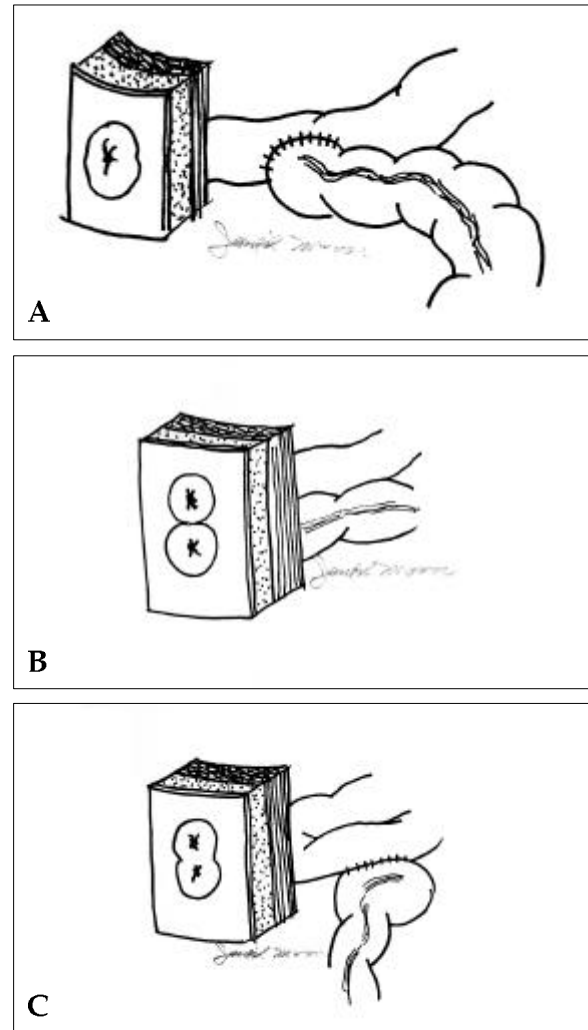


Fig. 2. Surgical options for the creation of end ostomy. (A) Bishop-Koop type, (B) Mikulicz type, (C) Loop ileostomy.

abdominal wall transplantation.²⁸

POSTTRANSPLANT MANAGEMENT

Immunosuppression

At the current time, most centers use tacrolimus based immunosuppression in intestinal and multivisceral transplant patients.²⁹ The initial doses are 0.02 - 0.03 mg/kg/day or 0.05 - 0.10 mg/kg/day for the intravenous or enteral preparation respectively. Target 12-hour trough whole-blood level is 15 - 20 ng/ml. There is no significant difference in the absorption of tacrolimus in a well-functioning

Table 2. Summaries of Various Anastomoses Based on Type of the Grafts

	Isolated intestine	Liver and intestine	Multivisceral
Venous outflow	PV (into IVC or PV)	Suprahepatic IVC (hepatic piggyback anastomosis)	
Arterial inflow	SMA	CA & SMA	
Biliary reconstruction	No need	R-Y hepatico-jejunostomy (no need if graft includes pancreas)	No need (R-Y hepaticojejunostomy if no liver)
Proximal GI tract	Jejunojejunostomy		Esophago- or gastro- gastrostomy
Distal GI tract	Ileocolostomy with various type of stoma (Bishop-Koop, Mikulicz, or Loop)		

PV, portal vein; IVC, inferior vena cava; SMA, superior mesenteric artery; CA, celiac axis; R-Y, Roux-en-Y; GI, gastrointestinal.

intestinal graft or native intestine. Typically, a bolus of intravenous methylprednisolone is given after revascularization of the graft. Total dose of steroids are tapered over a period time. Supplemental immunosuppression with azathioprine, cyclophosphamide, or mycophenolate mofetil has been used.³⁰ There are various protocols of induction immunosuppression using antilymphocyte regimens or IL-2 blocking agents.³¹ Most recently tacrolimus without steroid combined with alemtuzumab induction showed good graft survival with decreased rejection episode.³² More detailed strategies for the use of immunosuppressive agents are described elsewhere.³³

Acute rejection and graft monitoring

Acute rejection is the most common and serious complication in clinical intestinal transplantation.³⁴ Endoscopy with transplant intestine biopsy is essential to diagnose rejection.^{35,36} Protocol endoscopy with biopsy is strongly recommended even when graft function seems normal. If the patients develop clinical symptom of rejection such as fever or significant changes in ostomy output, including increasing volume, gross blood, or mucosal sloughing, endoscopy should be performed immediately. Endoscopic findings which include erythema, granularity, friable and hemorrhagic mucosa are highly suggestive of acute rejection. Recent technology, zoom endoscopy, allows magnifying endoscopic image up to 100 fold and actual villi and crypt can be observed in situ.^{37,38} There are preliminary studies which suggest serum citrulline levels may act as a marker for acute cellular rejection in small intestinal

transplant recipients.³⁹

Nutrition

The ultimate goal of intestinal and/or multivisceral transplantation is to establish autonomy of the intestine and stop TPN.^{40,41} The enteral feeds are started as soon as intestinal function resumes and anastomotic integrity is established. The TPN continues until the patient satisfies nutritional needs with adequate oral and/or enteral feeds. The general guide line of nutritional requirement is 1.5 gm protein/kg/day and 30-35 kcal/kg/day for adults. In children total calorie requirement is up to 100 kcal/kg/day.⁴⁰ Graft function is assessed clinically by monitoring the volume of ostomy output and the concentration of reducing substances in the ostomy fluid. The ostomy output is usually high in the early post-operative days and decreases over time as the graft function normalizes. Additional assessment of absorption can be performed with D-xylose absorption studies and serum concentration of plasma proteins, albumin, prealbumin, vitamins, minerals, and trace elements. The central line is taken out as soon as possible to avoid infection.

OUTCOMES AND PROSPECTS

Most recent International Intestinal Transplant Registry (ITR) was presented at VIII International small bowel transplant symposium in September 2003. There were 61 centers from 19 countries reporting. One year graft and patient survival for the recipients of transplants after 2001 were

ranged 60-70% and 60-80% depending on the types of graft. Data from individual centers, which performed more than 100 intestinal and/or multivisceral transplantations, showed better survival than ITR data.⁴²⁻⁴⁵ One year graft and patient survival reached up to 80% and 70% respectively. Intestinal or multivisceral transplantation is not being performed on regular base yet in most of the centers. Only 28 centers in ITR had performed one or more transplants within the past 2 years. Because of this scarcity, intestinal and multivisceral transplantation has not reached the levels of success yet seen with kidney or liver transplants. Diagnosis and treatment of acute rejection still plays a major role in determining clinical outcome.

In conclusion, intestinal and multivisceral transplantation has become a lifesaving procedure for the patients with intestinal failure who developed life threatening complication of TPN.^{46,47} Since the survival rate has cumulatively improved during the past decade, intestinal and multivisceral transplantation have the potential to become the standard of care for the patients with intestinal failure.^{48,49}

ACKNOWLEDGEMENT

The authors gratefully express their appreciation to Debbie Weppler, R.N. for her ongoing help with the preparation of this manuscript.

REFERENCES

1. Pironi L, Paganelli F, Labate AM, Merli C, Guidetti C, Spinucci G, et al. Safety and efficacy of home parenteral nutrition for chronic intestinal failure: a 16-year experience at a single centre. *Dig Liv Dis* 2003;35:314-24.
2. Sigalet DL. Short bowel syndrome in infants and children. *Semin Pediatr Surg* 2001;10:49-55.
3. Lillehei RC, Idezuki Y, Feemster JA, Dietzman RH, Kelly WD, Merkel FK, et al. Transplantation of stomach, intestine and pancreas: experimental and clinical observation. *Surgery* 1967;62:721-41.
4. Kirkman RT. Small bowel transplantation. *Transplantation* 1984;37:429-33.
5. Starzl TE, Rowe M, Todo S, Jaffe R, Tzakis AG, Hoffman AL, et al. Transplantation of multiple abdominal viscera. *JAMA* 1989;261:1449-57.
6. Grant D, Wall W, Mimeault R, Zhong R, Ghent C, Garcia B, et al. Successful small bowel/liver transplantation. *Lancet* 1990;335:181-4.
7. Todo S, Tzakis AG, Abu-Elmagd K, Reyes J, Nakamura K, Casavilla A, et al. Intestinal transplantation in composite visceral graft or alone. *Ann Surg* 1992;216:223-34.
8. Fleming CR, Remington M. Intestinal failure. In: Hill GL, editor. *Clinical Surgery International*. Edinburgh: Churchill Livingstone; 1981. p.219-35.
9. Sturm A, Layer P, Goebell H, Dignass AU. Short-bowel syndrome: an update on the therapeutic approach. *Scan J Gastroenterol* 1997;32:289-96.
10. Thompson JS. Management of the short bowel syndrome. *Gastroenterol Clin North Am* 1994;23:403-20.
11. Khan FA, Tzakis AG. Intestinal and multivisceral transplantation. In: Ginns LC, Cosimi AB, Morris PJ, editors. *Transplantation*. 1st ed. Malden: Blackwell Science; 1998. p.422-37.
12. Langnas A, Iyer K. Liver and small bowel transplantation. In: Maddrey WC, Schiff ER, Sorrell MF, editors. *Transplantation of the liver*. 3rd ed. Philadelphia: Lippincott Williams and Wilkins; 2001. p.111-20.
13. Mittal NK, Tzakis AG, Kato T, Thompson JF. Current status of small bowel transplantation in children: update 2003. *Pediatr Clin North Am* 2003;50:1419-33.
14. Kato T, Mittal N, Nishida S, Levi D, Yamashiki N, Miller B, et al. The role of intestinal transplantation in the management of babies with extensive gut resections. *J Pediatr Surg* 2003;38:145-9.
15. Kaufman SS, Atkinson JB, Bianchi A, Goulet OJ, Grant D, Langnas AN, et al. Indications for pediatric intestinal transplantation: a position paper of the American Society of Transplantation. *Pediatr Transplant* 2001;5:80-7.
16. Cahtzipetrou MA, Tzakis AG, Pinna AD, Kato T, Misiakos EP, Tsaroucha AK, et al. Intestinal transplantation for the treatment of desmoid tumors associated with familial adenomatous polyposis. *Surgery* 2001;129:277-81.
17. Vennarecci G, Kato T, Misiakos EP, Neto AB, Verzaro R, Pinna A. Intestinal transplantation for short gut syndrome attributable to necrotizing enterocolitis. *Pediatrics* 2000;105:E25.
18. Masetti M, Rodriguez MM, Thompson JF, Pinna AD, Kato T, Romaguera RL, et al. Multivisceral transplantation for megacystis microcolon intestinal hypoperistalsis syndrome. *Transplantation* 1999;68:228-32.
19. Kato T, Romero R, Verzaro R, Misiakos E, Khan FA, Pinna AD, et al. Inclusion of entire pancreas in the composite liver and intestinal graft in pediatric intestinal transplantation. *Pediatr Transplant* 1999;3:210-4.
20. Bueno J, Abu-Elmagd K, Mazariegos G, Madariaga J, Fung J, Reyes J. Composite liver-small bowel allografts with preservation of donor duodenum and hepatic biliary system in children. *J Pediatr Surg* 2000;35:291-5.
21. Kato T, Ruiz P, Thomson JF, Eskind LB, Weppler D, Khan FA, et al. Intestinal and multivisceral transplan-

- tation. *World J Surg* 2002;26:226-37.
22. Kato T, Tzakis AG, Selvaggi G, Madariaga JR. Surgical techniques used in intestinal transplantation. *Curr Opin Organ Transplant* 2004;9:207-13.
23. Tzakis AG, Todo S, Reyes J, Nour B, Fung JJ, Starzl TE. Piggyback orthotopic intestinal transplantation. *Surg Gynecol Obstet* 1993;176:297-8.
24. Berney T, Kato T, Nishida S, Tector AJ, Mittal NK, Madariaga JR, et al. Portal versus systemic drainage of small bowel allografts: comparative assessment of survival, function, rejection, and bacterial translocation. *J Am Coll Surg* 2002;195:804-13.
25. Shauraut WH, Abraham VS, Loe KK. Portal versus caval venous drainage of small bowel allografts: technical and metabolic consequences. *Surgery* 1986;99:193-8.
26. Alexandrides IJ, Liu P, Marshall DM, Nery JR, Tzakis AG, Thaller SR. Abdominal wall closure after intestinal transplantation. *Plastic Reconstr Surg* 2000;106:805-12.
27. Nery JR, Weppeler D, De Faria W, Liu P, Romero R, Tzakis AG. Is the graft too big or too small? Technical variations to overcome size incongruity in visceral organ transplantation. *Transplant Proc* 1998;30:2640-1.
28. Levi DM, Tzakis AG, Kato T, Madariaga JR, Mittal NK, Nery J, et al. Transplantation of the abdominal wall. *Lancet* 2003;361:2173-6.
29. Tzakis AG, Tryphonopoulos P, Kato T, Nishida S, Levi DM, Nery JR, et al. Intestinal transplantation: advances in immunosuppression and surgical techniques. *Transplant Proc* 2003;35:1925-6.
30. Tzakis AG, Nery JR, Khan FA, Phipps J, Raskin J, Thompson J, et al. Mycophenolate mofetil in combination with FK 506 and steroids for intestinal transplantation. *Transplant Proc* 1998;30:2677.
31. Pinna AD, Weppeler D, Nery JR, Khan FA, Ruiz P, Kato T, et al. Induction therapy for clinical intestinal transplantation: comparison of four different regimens. *Transplant Proc* 2000;32:1193-4.
32. Tzakis AG, Kato T, Nishida S, Levi DM, Tryphonopoulos P, Madariaga JR, et al. Alemtuzumab (Campath-1H) combined with tacrolimus in intestinal and multivisceral transplantation. *Transplantation* 2003;75:1512-7.
33. Tzakis AG, Nery J, Thompson J, Webb MG, Khan FA, Khan RT, et al. New immunosuppressive regimens in clinical intestinal transplantation. *Transplant Proc* 1997;29:683-5.
34. Kato T, Berho M, Weppeler D, Ruiz P, Pinna AD, Khan FA, et al. Is severe rejection an indication for retransplantation? *Transplant Proc* 2000;32:1201.
35. Lee RG, Nakamura K, Tsamandas AC, Abu-Elmagd K, Furukawa H, Hutson WR, et al. Pathology of human intestinal transplantation. *Gastroenterology* 1996;110:1820-34.
36. Kato T. New techniques for prevention and treatment of rejection in intestinal transplantation. *Curr Opin Organ Transpl* 2000;5:284-9.
37. Kato T, O'Brien CB, Berho M, Nishida S, Levi DM, Khan FA, et al. Improved rejection surveillance in intestinal transplant recipients with frequent use of zoom video endoscopy. *Transplant Proc* 2000;32:1200.
38. Sasaki T, Hasegawa T, Nakai H, Kimura T, Okada A, Musiaki S, et al. Zoom endoscopic evaluation of rejection in living related small bowel transplantation. *Transplantation* 2002;73:560-4.
39. Pappas PA, Tzakis AG, Gaynor JJ, Carreno MR, Ruiz P, Huijing F, et al. An analysis of the association between serum citrulline and acute rejection among 26 recipients of intestinal transplant. *Am J Transplant* 2004;4:1124-32.
40. Iyer K, Horslen S, Iverson A, Sudan D, Fox I, Shaw B, et al. Nutritional outcome and growth of children after intestinal transplantation. *J Pediatr Surg* 2002;37:464-6.
41. Nucci AM, Barksdale EM Jr., Beserock N, Yaworski JA, Iurlano K, Kosmach-Park B, et al. Long-term nutritional outcome after pediatric intestinal transplantation. *J Pediatr Surg* 2002;37:460-3.
42. Langnas AN. Advances in small-intestine transplantation. *Transplantation* 2004;77:S75-8.
43. Farmer DG, McDiarmid SV, Yersiz H, Cortina G, Amersi F, Vargas J, et al. Outcome after intestinal transplantation: results from one center's 9-year experience. *Arch Surg* 2001;136:1027-31.
44. Abu-Elmagd K, Reyes J, Bond G, Mazariegos G, Wu T, Murase N, et al. Clinical intestinal transplantation: a decade of experience at a single center. *Ann Surg* 2001;234:404-16.
45. Nishida S, Levi DM, Kato T, Nery JR, Mittal N, Hadjis N, et al. Ninety-five cases of intestinal transplantation at the University of Miami. *J Gastrointest Surg* 2002;6:233-9.
46. Niv T, Mor E, Tzakis AG. Small bowel transplantation: a clinical review. *Am J Gastroenterol* 1999;94:3126-30.
47. Starzl TE, Todo S, Tzakis AG, Alesseani M, Casavilla A, Abu-Elmagd K, et al. The many faces of multivisceral transplantation. *Surg Gynecol Obstet* 1991;172:335-44.
48. Fishbein TM, Kaufman SS, Florman SS, Gondolessi GE, Schiano T, Kim-Schluger L, et al. Isolated intestinal transplantation: proof of clinical efficacy. *Transplantation* 2003;76:636-40.
49. Abu-Elmagd K, Reyes J, Todo S, Rao A, Lee R, Irish W, et al. Clinical intestinal transplantation: new perspectives and immunologic considerations. *J Am Coll Surg* 1998;186:512-27.