

Revolution and Refinement of Surgical Techniques for Living Donor Partial Liver Transplantation

Ender Dulundu, Yasuhiko Sugawara, and Masatoshi Makuuchi

Department of Surgery, Graduate School of Medicine, University of Tokyo, Tokyo, Japan.

Living donor liver transplantation (LDLT) was first successfully performed on a child in 1990 and the Shinshu group performed the same procedure on an adult for the first time in 1994. Over the past few years adult LDLT has been increasing worldwide because of the severe shortage of cadaveric organs, especially in locations where the transplantation of organs from brain-dead donors is rarely practiced. The surgical procedures for LDLT are more technically challenging than those for cadaveric whole liver transplantation. LDLT requires a full understanding of hepatobiliary anatomy and continuous technical refinement of the procedure. The development of innovative techniques is a key factor for a successful LDLT. Some of the technical highlights include selective vascular occlusion techniques for donor hepatectomy, hepatic arterial reconstruction under the microscope, the introduction of intraoperative ultrasound, graft volume estimation, hepatic venous reconstruction using cryopreserved vascular grafts, and the use of the right lateral sector of the liver. These techniques have improved the success rate of LDLT over the past few years. This review focuses on the surgical techniques for LDLT on the basis of our experience with adult LDLT at the Tokyo University Hospital.

Key Words: Living donor liver transplantation, middle hepatic vein, right liver graft

INTRODUCTION

The use of live donors for liver transplantation was initiated more than a decade ago as a solution to the cadaveric donor shortage for pediatric recipients.¹ Since the first successful case of LDLT performed on an adult patient in 1994,² this pro-

cedure is now widely applied to adult recipients, especially in countries where the availability of brain-dead donors is severely restricted.³ This includes the United States and European countries where there is a critical shortage of cadaveric organs. In attempts to meet the growing needs of recipients, transplant surgeons have had to develop innovative techniques and appropriate algorithms to overcome deteriorating conditions and complications such as outflow and biliary complications.

In this review, several considerations of LDLT, including donor and graft selection criteria, technical highlights, and critical points necessary for successful patient outcome are discussed on the basis of our experience at the Tokyo University Hospital.

DONOR SELECTION CRITERIA

The first priority when performing LDLT is donor safety. Donor characteristics are the primary determinant of the outcome for both patients. Therefore, careful evaluation and selection of the donor are obligatory. In our department, a preoperative donor evaluation consists of three stages. In the first stage, patients and their families are given explanations about LDLT, including the risk of death for LDLT donors. After evaluating the medical and family history, social support system within the family, and psychological fitness, the donor's understanding of the risks involved with a liver resection and accompanying invasive tests must be confirmed for each donor candidate. The age of acceptable donors at our center is between 20 and 65 years with a

Received July 5, 2004

Reprint address: requests to Dr. Yasuhiko Sugawara, Artificial Organ and Transplantation Division, Department of Surgery, Graduate School of Medicine, University of Tokyo, 7-3-1 Hongo, Bunkyo-ku, Tokyo 113-8655, Japan. Tel: 81-3-3815-5411, Fax: 81-3-5684-3989, E-mail: yasusuga-tky@umin.ac.jp

relation to the recipient within the third degree of consanguinity.

The second phase involves performing liver function tests, ABO compatibility testing, lymphocyte cross matching; negative serology for hepatitis B and C, human immunodeficiency and adult T-cell leukemia viruses, cardiopulmonary function tests, the determination of tumor markers of donors over 40 years old, and a pregnancy test for female donors. ABO blood group incompatibility and positive lymphocyte cross matching are not definite exclusion criteria.

If there is no anomaly, the donor candidate can proceed to the third stage; a Doppler ultrasound should be performed for hepatic artery, portal vein, and hepatic vein evaluation. Computed tomography (CT) is used to measure graft volume. Hepatic angiography can be performed to evaluate vessel anatomy. The donor's own blood and plasma are banked preoperatively. Throughout the course of the donor evaluation, the spontaneous willingness of the donor candidate is repeatedly confirmed.⁴ Signed informed consent is obtained before the surgery.⁵

Preoperative liver biopsy and steatosis in graft

Preoperative determination of the extent of hepatic steatosis is important to ensure both donor and recipient safety. Donors with significant steatosis may not tolerate surgery as well as those with nonsteatotic livers and they tend to have increased postoperative morbidity, mortality, transfusion requirements, and surgical time.⁶ A liver biopsy must be performed for a secure evaluation of the liver. The indications for a liver biopsy, however, must be determined carefully and some patients may require hospitalization after the procedure (5% frequency) or experience serious complications (1%).⁷⁻⁹

The degree of steatosis acceptable for LDLT remains controversial. Marcos et al. reported no impairment of function in either the donor or recipient when using grafts containing less than 30% steatosis.¹⁰ Fan et al. do not use a right liver graft with steatosis of 20% or more,¹¹ whereas other groups use liver grafts with steatosis of less than 50% if the graft volume-to-standard liver volume (SLV) of the recipient ratio is 40% or

more.¹² At our center, when hepatic steatosis is suspected by computed tomography and biochemical data (i.e., aspartate aminotransferase < alanine aminotransferase), a liver biopsy for evaluating steatosis is considered. If time permits, the potential donor should undergo a period of prescribed diet and exercise. Livers with less than 10% hepatic macrosteatosis are preferred.⁷

Estimation of the liver graft

A major concern for the application of LDLT to adults is graft size disparity. Small-for-size grafts are defined as functionally insufficient grafts for satisfying the recipient's metabolic demand, which will predispose the recipient to injuries characterized by cholestasis and histologic features of ischemia after implantation.¹³ On the other hand, harvesting a larger graft puts the donor at higher risk.¹⁴ The right liver is not indicated as a graft when the estimated volume in donors is over 70%, according to the criteria of Fan et al.¹¹ We established a method for estimating graft volume using CT and the following formula to calculate the SLV (optimal liver mass) in recipients from their body surface area:^{15,16}

$$\text{SLV (ml)} = 706.2 \times (\text{body surface area [m}^2\text{]}) + 2.4.$$

The volume of each sector of the donor liver is evaluated by CT. The predicted graft volume/SLV ratio is then calculated.¹⁷

Principally, grafts with a weight/recipient SLV ratio of 40% are preferred for use in adult patients. In low-risk patients, a right liver graft with or without the middle hepatic vein (MHV) are considered. In other words, grafts with an SLV ratio of 40% or less may suffice only in the ideal situation of a good-risk patient as proposed by Lo and associates.¹⁸ Our data indicate that¹⁹ 96% of patients survive with a graft weight ratio of over 40%, while only 80% of patients survive with a graft weight ratio of 40% or less. High-risk patients include those with primary biliary cirrhosis with a Mayo risk score²⁰⁻²² of less than,¹⁰ metabolic disease, and fulminant hepatic failure. For higher risk patients, a left liver with or without a caudate lobe should be evaluated by CT volumetric analysis.^{23,24} If the volume of the right

lateral sector is greater than that of the left liver, the right lateral sector segments VI and VII, according to Coinaud's nomenclature for liver segmentation, should be considered for the graft.^{5,22,23}

Objection against routine use of right liver graft

A right liver graft was first used for a pediatric case by Yamaoka et al.²⁵ It is now commonly used for adult patients. This procedure was followed by the introduction of an extended right liver graft, which includes the trunk of the MHV. This trend has grown rapidly.²⁶⁻²⁸ At the same time, however, important ethical issues were raised regarding the execution of an extended hepatectomy on live donors.³ Although graft size in living donors may be safely expanded, a multidisciplinary approach and meticulous donor evaluation are always necessary. We do not agree with the recent tendency to use a right liver graft routinely for almost all adult patients.²⁸ Based on our experience, the number of patients who inevitably need a right liver graft with the MHV is limited; we found that less than 10% of the recipients in our series required an extended right liver graft.

Evaluation of donor hepatic arterial anatomy

When planning a donor resection, a preoperative arteriography is necessary to assess the anatomy and quality of the vasculature of the resulting graft.²⁹ For example, upon performing a right liver LDLT, it is first necessary to determine which of the varied origins of the artery to segment IV is important for defining the optimal points for transection of the artery.³ Although an angiography is a relatively invasive study with the potential for complications, the information it provides is essential for surgical planning and donor safety. Unfortunately, non-invasive techniques, such as magnetic resonance angiography or CT, are limited in their ability to demonstrate small vessels such as the accessory hepatic arterial branches.^{28,30} The techniques for non-invasive imaging of smaller vascular structures are still under evaluation and are not yet sufficiently reliable for these purposes.

Intermittent inflow occlusion technique

In our department, a donor hepatectomy is routinely performed under Pringle's maneuver without any side effects. We postulate that the intermittent inflow occlusion acts as a preconditioning step and reduces blood loss during the hepatectomy.³¹

RECIPIENTS

During an evaluation of a liver transplant candidate for LDLT, there needs to be a balance between the severity of the liver disease and the adequacy of a partial graft for transplantation. Most of the complications associated with acute hepatic failure are reversible if the transplantation can be performed in the early stage.³² Stable patients with chronic liver disease also benefit from living donors. Transplantation can be performed electively before decompensatory (i.e. fulminant hepatic failure with irreversible encephalopathy) complications occur.

Recipient surgery

The operative technique for recipients is based on the technique of whole liver resection with preservation of the inferior vena cava used for orthotopic liver transplantation.³³ A J-shape incision is made to open the abdominal space as is done for a right thoracotomy. Electrocautery is effective, time-saving, and useful for sharp dissection. An argon beam coagulator is useful to stop bleeding from the hepatic serosa. Each step of this operation requires meticulous maneuvers and great care to achieve an uneventful resection of the whole liver, while avoiding injury to the other visceral organs. It is important to make a large and long opening along the sides of the hepatic veins, and to maintain satisfactory portal, biliary, and hepatic arterial sources for the reconstruction. The right and left hepatic arteries should be dissected out as distally as possible, the left portal vein should be dissected up to the umbilical portion, which is just distal to the point of origin of the branch to segment², and the right portal vein should be dissected up to its bifurcation into

the anterior and posterior branches.

In recipients with little portosystemic collateral circulation (i.e., familial amyloid polyneuropathy, citrullinemia, acute hepatic failure), the prevention of portal congestion is necessary during the anhepatic phase. A temporary shunt between the portal vein and the inferior vena cava should be made.³⁴ Briefly, the portal vein branch, which will not be used for reconstruction, is anastomosed end-to-side or connected by a tube to the inferior vena cava. Blood flow through this shunt is maintained until portal venous reperfusion to the graft is achieved by portal vein anastomosis.

HEPATIC VENOUS RECONSTRUCTION

The provision of an adequate outflow is indispensable for graft function, thus, it is necessary to obtain a wide ostium and a sufficient length of the hepatic vein for anastomosis.

Left liver

Early cases of LDLT entailed an end-to-side anastomosis for hepatic vein reconstruction. A longitudinal cavotomy was made along the anterior aspect, and the hepatic venous branches, which were joined on the bench, were anastomosed end-to-side to the caval window.^{3,35} Takayama et al. cautioned,³⁶ however, that a direct anastomosis of the hepatic veins to a thin inferior vena cava can cause a bend in the inferior vena cava at the anastomotic side, which can result in outflow occlusion.

Currently, an end-to-end anastomosis³⁷ is preferred. In such cases, size matching is important. The left hepatic vein (LHV) and MHV in the recipient can be joined into one.³⁸ If the diameter of the joined veins is smaller than the left liver graft's hepatic vein, a wider orifice can be constructed by venoplasty of three hepatic veins³⁹ in the recipient (Fig. 1).

In the first method for venoplasty, the neighboring walls were simply sutured together. The second method involves the use of the pantaloon technique. The parenchyma around the venous branches is aspirated using an ultrasonic dissector, resulting in elongation of the venous

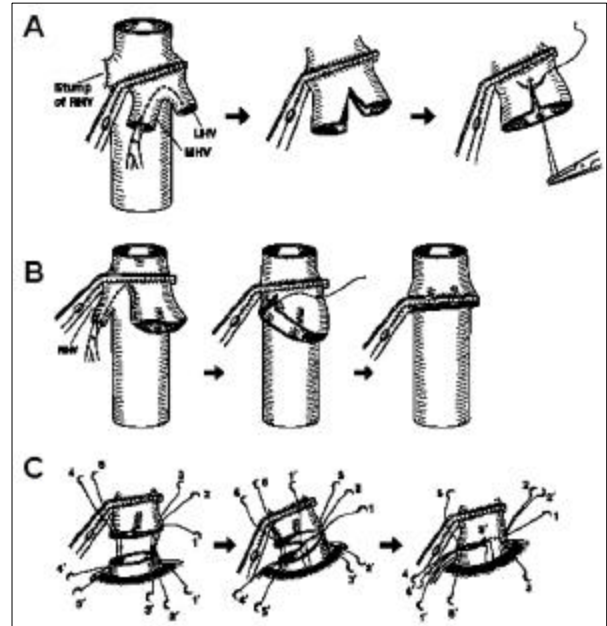


Fig. 1. Recipient venoplasty of the left hepatic vein (LHV) and middle hepatic veins (MHV) (A) or triple hepatic veins (B). (C) The anastomosis was made with continuous sutures (1-5).

branches. The branches are then cut longitudinally and sutured together. In the third method, the hepatic vein of the liver graft is cut in a perpendicular direction, and then a venous patch is anastomosed to the incised graft hepatic veins. De Villa et al.⁴⁰ detailed another venoplasty technique. They reported that when two hepatic veins are connected by a longer intervening septum, a venoplasty is made by an incision perpendicular to the septum by first removing the directly underlying liver parenchyma using a Cavitron ultrasonic surgical aspirator (CUSA).

Caudate vein reconstruction

Reconstruction of the caudate vein is technically demanding.⁴¹ In the initial LDLT cases,²³ the drainage vein of the caudate lobe was not reconstructed. Takayama and associates²⁴ emphasized the importance of short hepatic vein reconstruction. According to the cast study by Couinaud, 91% (115/126) of the caudate veins entered directly to the vena cava,⁴² thus indicating that one or two veins of the caudate lobe should be reconstructed to prevent venous congestion of the caudate lobe. The hepatic vein of the caudate lobe

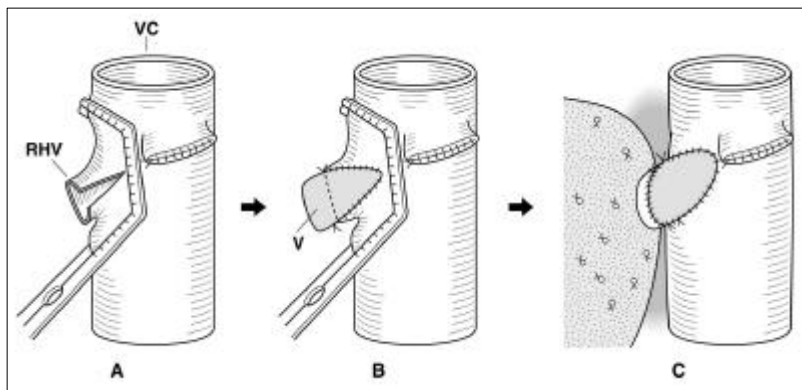


Fig. 2. (A, B) The V-shaped venous patch (V) was anastomosed to the incised anterior wall of the RHV of the recipient. (C) End-to-end anastomosis between the recipient and graft RHVs with continuous sutures.

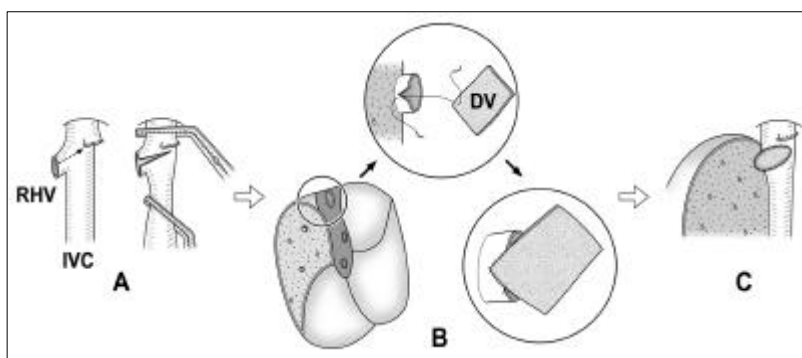


Fig. 3. (A) The anterior wall of the recipient right hepatic vein (RHV) was cut under cross-clamping of the inferior vena cava (IVC). (B) The diamond shaped venous patch (DV) was anastomosed to the incised anterior wall of the recipient's RHV. (C) End-to-end anastomosis was done between the recipient and graft RHV with continuous sutures.

can be resected with a cuff of the vena cava, which resembles a Carrel's patch. In the recipient operation, reconstruction of the caudate hepatic vein is performed and then the trunk of the left and middle hepatic vein of the recipient and the graft are anastomosed. When the orifice of the short hepatic vein is located near those of the LHV and MHV, the caudate vein with a cuff of the inferior vena cava can be sutured to the common orifice of the LHV and MHV (Fig. 4 and 5).⁴³

Right liver

To overcome a size discrepancy between the right liver graft and the recipient's hepatic veins, the patch technique can be used. A vascular patch graft can be sutured separately or to both the RHV of the liver graft and the RHV of the recipient (Fig. 2 and 3). Three hepatic veins of the recipient can be joined to create a wide orifice for anastomosis.

The appropriate length for the reconstructed hepatic vein is still controversial and size match-

ing between the liver graft and the recipient's hepatic veins is crucial.⁴⁴ Regeneration of the liver graft may compress the venous anastomotic site. Ghobrial et al. suggested that a short hepatic vein places undue tension on the anastomosis⁴⁴ and they cautioned that a long vein is predisposed to kinking after reperfusion. In contrast, we believe that it is necessary to obtain a wide ostium and sufficient length of the hepatic vein anastomosis to ensure adequate hepatic venous flow. We usually use a vein graft and make a long and wide anastomosis during the reconstruction.⁴⁵

MHV reconstruction and cryopreserved vascular graft

An extended right liver graft is beneficial with regard to venous drainage of the graft because the MHV is the major draining vein of the right paramedian sector, and its role in the left paramedian sector is limited.²⁷ On the other hand, a right liver graft without the trunk of the MHV can cause severe congestion of the right paramedian sector (segments V and VIII) without MHV

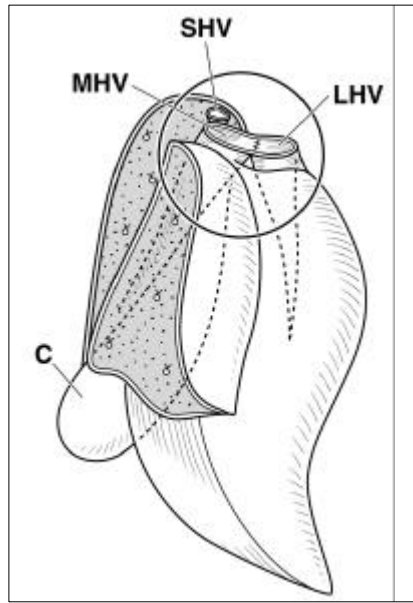


Fig. 4. The thickest hepatic vein (SHV) of the caudate lobe (C) was preserved, which was located near the orifice of the left hepatic vein (LHV) and middle hepatic vein (MHV).

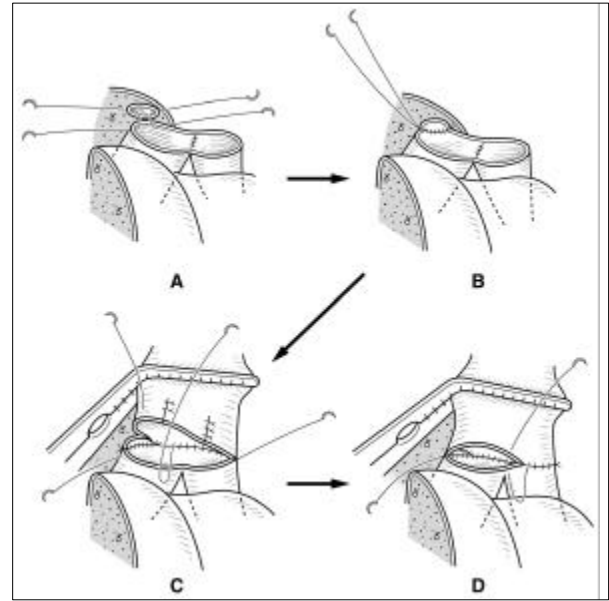


Fig. 5. Short hepatic vein of the caudate lobe sutured to the common orifice of the left and middle hepatic vein of the liver graft from the neighboring wall (A, B) End-to-end anastomosis between the common orifice of the left and middle hepatic vein and newly created hepatic venous orifices of the liver graft (C, D).

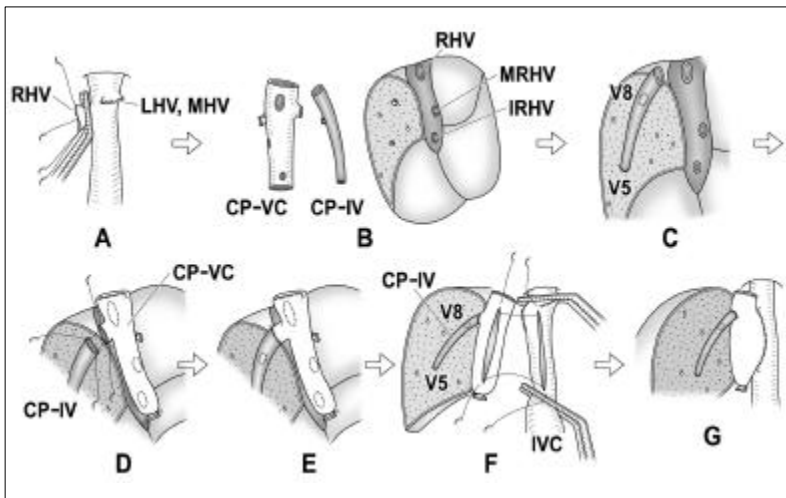


Fig. 6. (A) Left hepatic vein (LHV), middle hepatic vein (MHV) and right hepatic vein (RHV) of the recipient's liver were sutured at their roots. (B) Three side holes were created in the wall of the cryopreserved vena cava graft (CP-VC) for anastomosis with the RHV and the short hepatic veins [inferior right hepatic vein (IRHV) or middle right hepatic vein (MRHV)] of the graft. (C, D) Another cryopreserved vein graft (CP-IV) can be used for middle hepatic vein reconstruction. (E) The stump of the venous branch was anastomosed with a jumping vein graft for middle hepatic vein reconstruction. (F, G) Side-to-side anastomosis between the recipient's inferior vena cava (IVC) and CP-VC with continuous sutures was performed.

reconstruction. To provide a functioning liver mass comparable to an extended right liver, several methods have been devised for MHV reconstruction.^{45,46} When a right liver graft has multiple short hepatic veins, use of a cryopreserved vena cava is recommended (Fig. 6).

The major concern in venous reconstruction using cryopreserved vein grafts is vein graft

obstruction or the possibility of vein narrowing over the long-term. Mills et al.⁴⁷ reported a 51% complication rate after using cryopreserved vascular grafts. Kuang et al.⁴⁸ reported complications including an aneurysm, thrombosis, and stricture in 8 of 9 cryopreserved vein grafts that were used for portal vein and hepatic arterial interpositions. To date, we have not experienced any compli-

cations using cryopreserved vascular grafts, but previous discouraging results indicate that long-term follow-up is necessary to confirm the feasibility of their use.

Indication for MHV reconstruction

There is no consensus regarding the optimal strategy for MHV reconstruction. Some authors⁴⁹ claim that donor liver parenchyma transection without MHV tributary ligation is dangerous and that the reconstruction might increase the warm ischemia time. The development of the collateral circulation that drains the ligated MHV tributaries may occur in approximately 1 week,⁵⁰ but there is no evidence that these collaterals always occur or already exist in all patients.^{51,52} Nakamura et al. clearly⁵³ demonstrated that the congestive area, which is due to hepatic vein ligation in the remnant liver, cannot be expected to function with the available parenchyma in the early postoperative period. They established that the congestive area resulted in histologic necrosis of the hepatic parenchyma approximately 24 hours after the ligation, although intrahepatic venous collaterals for draining the congestive area were observed through the sinusoids for 7 days after the ligation.⁵³

A careful examination of the preoperative CT scan is useful to detect the number and diameter of the thick MHV tributaries draining the right paramedian sector of the donor liver. Anatomic variations, such as a venous variant type of small RHV with a large MHV might indicate the necessity for MHV reconstruction.⁴⁴ The indications for reconstruction of MHV tributaries can be determined based on our objective criteria.^{54,55} First, discoloration of the liver surface should be observed after concomitant clamping of the MHV tributary and relevant hepatic artery for 5 minutes. Thereafter, only the hepatic artery is declamped and Doppler ultrasonography is performed. When hepatofugal portal flow is observed, the relevant area of the liver is confirmed to be congested. If the liver volume, excluding the area discolored by occlusion of the artery, is estimated to be insufficient for postoperative metabolic demand, (estimated graft volume less than 40% of the recipient's SLV), the MHV

tributaries are reconstructed.

It is not rare to find thick, short hepatic veins during harvesting of a right liver graft (i.e., inferior right hepatic vein, middle right hepatic vein). Reconstruction of these vessels can be determined using the same criteria as for MHV reconstruction.

PORTAL VENOUS ANASTOMOSIS

In the preoperative evaluation of the donor, dynamic CT, visceral angiography, and dynamic CT with three-dimensional reconstruction provide detailed information about portal vein anatomy. Producing an anastomosis that is tension-free with wide enough orifices is a key determinant for successful portal vein anastomosis. Therefore, the portal vein on the recipient side should be dissected at the longest length possible during removal of the liver. On the donor side, a transverse portion of the portal vein has to have a long extrahepatic course to make it easier to obtain a longer portal vein in the left liver grafts than in the right liver grafts.

Portal venous thrombosis, sclerosis, and a size discrepancy between the graft and the recipient's portal vein are other issues that make it difficult or impossible to perform standard end-to-end anastomosis. These problems are usually overcome by use of an interposition vascular graft, vascular patch graft, or portal venoplasty.⁵⁶

Trifurcation of portal vein

A common anomaly that requires attention during the donor operation is trifurcation of the portal vein in which the right lateral and right paramedian sectors are supplied separately. In this anatomic anomaly, the transverse portion of the portal vein is shorter than usual, and this necessitates a complete division of the portal vein tributaries to the caudate lobe when harvesting a left liver graft.

A right liver graft will have two portal branches. Some investigators excise the right paramedian and lateral portal vein with a side wall of the remaining donor portal veins as a patch. Defects in the remaining portal vein on the

donor side are repaired with a venous patch, by direct suturing of the defect, or with segmental resection and end-to-end anastomosis. These procedures add to donor risk and result in unsatisfactory portal reconstruction.⁵⁷ This anatomic variation can be overcome by one of three ways. First, venoplasty of these portal veins can be performed on the bench and anastomosed as one common orifice to the recipient's portal vein. Second, these branches can be separately anastomosed to the recipient's portal vein. Third, a cryopreserved vascular graft can be used.

ARTERIAL RECONSTRUCTION

The information provided by preoperative angiography is essential for surgical planning and donor safety.⁵⁸ Hepatic arteries are subject to many variations.^{59,60} Basically, these variations can be summarized as follows: (1) an aberrant left hepatic artery originating from the left gastric artery; (2) an aberrant right hepatic artery originating from the superior mesenteric artery; and (3) aberrant accessory arteries, in addition to the original left (or original middle) hepatic artery, or in addition to the original or replaced right hepatic artery. Division and dissection of the hepatic artery should be planned and meticulously performed according to the preoperative and operative findings.

Hepatic arterial reconstruction in LDLT is technically difficult due to the existence of short and thin hepatic arteries on a liver graft. Marcos et al. reported that anastomosis under a microscope is usually unnecessary in adult recipients, especially with a right liver graft.²⁸ Hepatic artery thrombosis is a serious complication that occurs after orthotopic liver transplantation, and it might result in hepatic necrosis, biliary leakage, bacteremia, or mortality.⁶¹ Mazzaferro et al.⁶² reported a significant association between hepatic arterial thrombosis and the presence of hepatic arteries less than 3 mm in diameter. In LDLT, the median diameter of the arterial branch, especially in a left-sided graft, is less than 3 mm.⁶⁰ Thus, microsurgery has an inevitable and indispensable place in LDLT.^{63,64}

Is reconstruction of all hepatic arterial branches necessary?

In the early series of LDLT, left liver grafts were mainly used, which had thin, short, and sometimes multiple arterial branches. Broelsch et al.⁶³ suggested that a double arterial supply to the liver graft is unsuitable for LDLT after two of three of their patients experienced hepatic artery thrombosis. To resolve this problem, Mori et al.⁶⁴ reconstructed all hepatic arteries of a liver graft. The Shinshu group,⁶⁵ however, demonstrated that reconstruction of all hepatic arterial branches was not necessary in their left liver graft series. Furthermore, Sakamoto revealed that the existence of aberrant hepatic arteries, especially in left liver grafts, allows the physician to obtain a thicker and larger hepatic artery for reconstruction.⁶⁰ An additional important note regarding the left liver is that dissection of the perivascular connective tissue around the umbilical portion of the portal vein must be avoided to maintain the collateral circulation among the segmental arteries.⁶⁵

In our previous series, the frequency of multiple arterial orifices was 1% for right-sided liver grafts and 9% for left-sided liver grafts.⁵⁹ Whereas recent data from Marcos et al.⁶⁶ revealed that 12% (11/95) of consecutive right liver grafts have double arteries. Marcos et al. proposed that reconstruction of all arterial branches of right lobe liver grafts is necessary, claiming that no portion of right liver grafts is supplied by secondary arterial perfusion.⁶⁷ In their recent series, they anastomosed double arterial orifices with auto Y-shaped arterial grafts on the bench.⁶⁶ It is still controversial, however, whether all arterial stumps must be anastomosed in LDLT. We reported successful results with only one hepatic arterial reconstruction in both a left and right liver graft with multiple arterial stumps.^{59,60,65} Redman⁶⁸ demonstrated that accessory hepatic arteries usually communicate with the original lobar arteries in the hepatic hilum, but they are not visualized on angiograms unless they actually function as collaterals.

Checking arterial communication in grafts

When multiple hepatic arteries exist, the largest

one should be used for reconstruction, and an adequate arterial flow to the nonanastomosed arterial branches should be confirmed using the following criteria. First, during the completion of a donor hepatectomy, when smaller branches of the hepatic artery are cut, pulsatile back-bleeding is observed. Second, on the bench, when perfusion fluid is flushed through the largest artery, it should be observed to flow out from the smaller arterial branches.⁶⁹ Third, arterial flow can be confirmed during the recipient's operation following the reconstruction of the largest hepatic artery by the presence of pulsatile back-bleeding from the stump of the other graft's arteries. Finally, the hepatic arterial signal can be checked by Doppler ultrasonography of each segment of the liver graft.

BILIARY RECONSTRUCTION

The current standard for biliary reconstruction in whole cadaveric liver transplantation is a duct-to-duct choledochocholedochostomy. The preferred technique in adult LDLT is currently shifting from a hepaticojejunostomy to duct-to-duct anastomosis.

Duct-to-duct biliary reconstruction

Duct-to-duct biliary reconstruction has been presented in some institutions.⁷⁰⁻⁷² These reports advocate the advantages of duct-to-duct biliary reconstruction over a hepaticojejunostomy, i.e., the procedure might preserve physiologic bilioenteric and bowel continuity, thus preventing a delayed bowel movement. Duct-to-duct reconstruction allows for easy endoscopic access to the biliary tree for diagnostic and therapeutic instrumentation and management, and it prevents ascending cholangitis.

The rationale for using a hepaticojejunostomy in LDLT is based on the small size of the recipient's bile duct and the inadequate length of the donor's bile duct. Although size and length are not restriction factors for adult patients, as they are for pediatric patients, an underlying liver disease (e.g., biliary atresia) often mandates the use of a hepaticojejunostomy. Since 2000, we have used

duct-to-duct anastomosis in patients without diseases involving the bile duct, such as biliary atresia or primary sclerosing cholangitis. However, long-term postoperative observations and technical modification are still necessary,^{70,73} to determine the success rate.

Devices used during the operation

The rate of biliary complications after LDLT is approximately 40%, suggesting that biliary reconstruction remains a technically demanding and challenging problem in LDLT.^{70,74,75} An intraoperative cholangiography is essential for visualizing biliary anatomy and anomalies (i.e., a right lateral sector bile duct originating from the left bile duct), and identifying the precise site of division.^{29,76} To avoid narrowing of the common bile duct of the donor, there should be no attempt to obtain a single duct orifice in the graft. It is very important to maintain an adequate blood supply from the hepatic arteries and gastroduodenal artery to the bile duct.⁷⁷ Thus, meticulous and sharp dissection of the recipient's bile duct, preserving as much surrounding tissue as possible,⁷⁰ is indispensable for the safety of duct-to-duct reconstruction.

The existence of multiple bile duct orifices on the graft side is common. Intermittent suturing or tying them off during the donor operation, or on the bench, may be performed.⁷⁸ To identify the orifice of the bile duct to each hepatic segment, a surgical probe can be inserted individually into each bile duct under the guidance of ultrasonography.⁷⁹

Postoperative complications

A surgical revision of bile duct stenosis is technically demanding if the endoscopic approach is not possible or unsuccessful. In repairs using a T-tube, an intraoperative cholangiography should be used for appropriate localization, which allows for sufficient bile juice drainage. Converting duct-to-duct anastomosis to a hepaticojejunostomy is another option.⁷⁰

The raw surface of the liver graft or biliary anastomosis is a common site of bile leakage, which can result in fluid collection or an abscess. Careful ligation of all bile ducts on the raw

surface and placing a closed suction drain along the cut surface of the liver graft is important.

Scatton⁸⁰ reported an increase in the biliary complication rate in a T-tube group. In LDLT, a T-tube helps to decompress the bile duct, but it will not prevent stenosis at the anastomotic site. Additionally, there are often multiple duct orifices in the graft and a size difference between the common bile duct and the duct orifice in the graft, so it is difficult to put the tip of a T-tube across the anastomotic site. A transanastomotic external tube can theoretically help decrease the intrahepatic biliary pressure caused by edema and the consequent partial obstruction of the anastomosis.⁸¹ The transanastomotic external tube will also facilitate a postoperative imaging study. The advantage over not stenting, however, has not been established.⁷⁰

UNIVERSITY OF TOKYO EXPERIENCE

Between 1996 and September 2003, 167 adult patients underwent LDLT at the Tokyo University Hospital. Donor candidates consisted of 71 children, 34 siblings, 23 parents, 23 spouses, 11 who composed of aunts, uncles, nieces and nephews and 5 others. Their ages ranged from 20 to 65. The LDLT donors underwent a left hepatectomy (n=16), a left liver with caudate lobectomy (n=59), and a right hepatectomy (n=76), a right lateral sector (n=16). The actual graft weight ranged from 289g to 924g (median 534g), and its ratio to the recipient's SLV ranged from 31% to 88% at the time of the transplantation. All the LDLT donors recovered well and returned to normal lives with a mean hospital stay of 15 days (11-56 days). Only minor donor complications occurred. Seven donors (3%) underwent a reoperation with good results. The indications for the reoperation were bile leakage in six donors and peritonitis in one. None of the donors required a banked-blood transfusion.

As for the recipients, three patients required re-transplantation and there were nine early deaths. Primary biliary cirrhosis, primary sclerosing cholangitis, and autoimmune hepatitis were the most common indications (33%), followed by hepatocellular carcinoma with hepatitis (24%). The

most common complication was acute rejection (45%), followed by biliary complications (25%). Patient and graft survival were 91% and 90%, respectively. Several considerations and techniques for performing LDLT and the experiences at Tokyo University were reviewed. The results confirmed that LDLT was satisfactory in adult patients with 3-year accumulated survival rates of 90%, and it can be performed with a low incidence of complications.

CONCLUSION

Taking into account the worldwide shortage of cadaveric organ donations, LDLT offers hope to patients with end-stage liver disease and its use will become increasingly more important. This procedure should be performed by an expert surgical team only after careful consideration of donor safety and recipient outcome. The long-term success of LDLT requires careful, thoughtful application of this procedure, as well as accumulated technical improvements in the field of hepatobiliary surgery.

REFERENCES

1. Strong RW, Lynch SV, Ong TH, Matsunami H, Koido Y, Balderson GA. Successful liver transplantation from a living donor for her son. *N Engl J Med* 1990;322: 1505-7.
2. Hashikura Y, Makuuchi M, Kawasaki S, Matsunami H, Ikegami T, Nakazawa Y, et al. Successful living-related partial liver transplantation to an adult patient. *Lancet* 1994;343:1233-4.
3. Sugawara Y, Makuuchi M. Technical advances in living-related liver transplantation. *J Hepatobiliary Pancreat Surg* 1999;6:245-53.
4. Hashikura Y, Kawasaki S, Miyagawa M, Terada M, Ikegami T, Nakazawa Y, et al. Donor selection for liver-related-liver transplantation. *Transplant Proc* 1997;29: 3410-1.
5. Sugawara Y, Makuuchi M, Takayama T, Imamura H, Kaneko J. Right lateral sector graft in adult living-related liver transplantation. *Transplantation* 2002;73: 111-4.
6. Behrns KE, Tsiotos GG, DeSouza NF, Krishna MK, Ludwig J, Nagorney DM. Hepatic steatosis as a potential risk factor for major hepatic resection. *J Gastrointest Surg* 1998;2:292-8.
7. Rinella ME, Alonso E, Rao S, Whittington P, Fryer J,

- Abecassis M, et al. Body mass index as a predictor of hepatic steatosis in living liver donors. *Liver Transpl* 2001;7:409-14.
8. Van Ness MM, Diehl AM. Is liver biopsy useful in the evaluation of patients with chronically elevated liver enzymes? *Ann Intern Med* 1989; 11:473-8.
 9. Goddard CJ, Warnes TW. Raised liver enzymes in asymptomatic patients: Investigation and outcome. *Dig Dis* 1992;10:218-26.
 10. Marcos A, Fisher RA, Ham JM, Shiffman ML, Sanyal AJ, Luketic VA, et al. Liver regeneration and function in donor and recipient after right lobe adult to adult living donor liver transplantation. *Transplantation* 2000;69:1375-9.
 11. Fan ST, Lo CM, Liu CL, Yong BH, Chan JK, Irene OL. Safety of donors in live donor liver transplantation using right lobe grafts. *Arch Surg* 2000;135:336-40.
 12. Soejima Y, Shimada M, Suehiro T, Kishikawa K, Yoshizumi T, Hashimoto K, et al. Use of steatotic graft in living-donor liver transplantation. *Transplantation* 2003;76:344-8.
 13. Emond JC, Renz JF, Ferrell LD, Rosenthal P, Lim RC, Roberts JP, et al. Functional analysis of grafts from living donors. Implications for the treatment of older recipients. *Ann Surg* 1996;224:544-52.
 14. Lo CM, Fan ST, Liu CL, Yong BH, Chan JK, Wong J. Increased risk for living donors after extended right lobectomy. *Transplant Proc* 1999;31:533-4.
 15. Kawasaki S, Makuuchi M, Matsunami H, Hashikura Y, Ikegami T, Chisuwa H, et al. Preoperative measurement of segmental liver volume of donors for living related liver transplantation. *Hepatology* 1993;18:1115-20.
 16. Urata K, Kawasaki S, Matsunami H, Hashikura Y, Ikegami T, Ishizone S, et al. Calculation of child and adult standard liver volume for liver transplantation. *Hepatology* 1995;21:1317-21.
 17. Kawasaki S, Makuuchi M, Matsunami H, Hashikura Y, Ikegami T, Nakazawa Y, et al. Living related liver transplantation in adults. *Ann Surg* 1998;227:269-74.
 18. Lo CM, Fan ST, Liu CL, Chan JK, Lam BK, Lau GK, et al. Minimum graft size for successful living donor liver transplantation. *Transplantation* 1999;68:1112-6.
 19. Sugawara Y, Makuuchi M, Takayama T, Imamura H, Dowaki S, Mizura K, et al. Small-for-size grafts in living-related liver transplantation. *J Am Coll Surg* 2001;192:510-3.
 20. Sugawara Y, Makuuchi M, Imamura H, Kaneko J, Ohkubo T, Matsui Y, et al. Living donor liver transplantation in adults: Recent advances and results. *Surgery* 2002;132:348-52.
 21. Dickson ER, Grambsch PM, Fleming TR, Fisher LD, Langworthy A. Prognosis in primary biliary cirrhosis: model for decision making. *Hepatology* 1989;10:1-7.
 22. Sugawara Y, Makuuchi M, Takayama T, Imamura H. Living related liver transplantation for primary biliary cirrhosis. *Transplantation* 2001;72:1087-91.
 23. Myagawa S, Hashikura Y, Miwa S, Ikegami T, Urata K, Terada M, et al. Concomitant caudate lobe resection as an option for donor hepatectomy in adult living related liver transplantation. *Transplantation* 1998;66:661-3.
 24. Takayama T, Makuuchi M, Kubota K, Sano K, Harihara Y, Kawarasaki H. Living-related transplantation of left liver plus caudate lobe. *J Am Coll Surg* 2000;190:635-8.
 25. Yamaoka Y, Washida M, Honda K, Tanaka K, Mori K, Shimahara Y, et al. Liver transplantation using a right lobe graft from a living related donor. *Transplantation* 1994;57:1127-30.
 26. Lo CM, Fan ST, Liu CL, Wei WI, Lo Ronald JW, Lai CL, et al. Adult-to-adult living donor liver transplantation using extended right lobe grafts. *Ann Surg* 1997;226:261-70.
 27. Lo CM, Fan ST, Liu CL, Lo RJW, Lau GK, Wei WI, et al. Extending the limit on the size of adult recipient in living donor liver transplantation using extended right lobe graft. *Transplantation* 1997;63:1524-8.
 28. Marcos A. Right lobe living donor liver transplantation: A review. *Liver Transpl* 2000;6:3-20.
 29. Takayama T, Makuuchi M, Kawarasaki H, Harihara Y, Kubota K, Hirata M, et al. Hepatic transplantation using living donors with aberrant hepatic artery. *J Am Coll Surg* 1997;184:525-8.
 30. Matoba M, Tonami H, Kuginuki M, Yokota H, Takashima S, Yamamoto I. Comparison of high-resolution contrast-enhanced 3D MRA with digital subtraction angiography in the evaluation of hepatic arterial anatomy. *Clin Radiol* 2003;58:463-8.
 31. Imamura H, Takayama T, Sugawara Y, Kokudo N, Aoki T, Kaneko J, et al. Pringle's manoeuvre in living donors. *Lancet* 2002;360:2049-50.
 32. Lo CM, Fan ST, Liu CL, Wei WI, Chan JK, Lai CL, et al. Applicability of living donor liver transplantation to high-urgency patients. *Transplantation* 1999;67:73-7.
 33. Tzakis A, Todo S, Starzl TE. Orthotopic liver transplantation with preservation of the inferior vena cava. *Ann Surg* 1989;210:649-52.
 34. Kawasaki S, Hashikura Y, Matsunami H, Ikegami T, Nakazawa Y, Watanabe M, et al. Temporary shunt between right portal vein and vena cava in living related liver transplantation. *J Am Coll Surg* 1996;183:74-6.
 35. Egawa H, Inomata Y, Uemoto S, Asonuma K, Kiuchi T, Okajima H, et al. Hepatic vein reconstruction in 152 living-related donor liver transplantation patients. *Surgery* 1997;121:250-7.
 36. Takayama T, Makuuchi M, Kawarasaki H, Kawasaki S, Matsunami H, Yasuhiko H, et al. Venocavaplasty to overcome outflow block in living related liver transplantation. *Transplantation* 1994;58:116-8.
 37. Takayama T, Makuuchi M, Kawasaki S, Ishizone S, Matsunami H, Iwanaka T, et al. Outflow Y-reconstruction for living related partial hepatic transplantation. *J Am Coll Surg* 1994;179:226-9.
 38. Makuuchi M, Sugawara Y. Living-donor liver transplantation using the left liver, with special reference to vein reconstruction. *Transplantation* 2003;75:S23-4.

39. Kubota K, Makuuchi M, Takayama T, Harihara H, Watanabe M, Sano K, et al. Successful hepatic vein reconstruction in 42 consecutive living related liver transplantations. *Surgery* 2000;128:48-53.
40. De Villa VH, Chen CL, Chen YS, Wang CC, Wang SH, Chiang YC, et al. Outflow tract reconstruction in living donor liver transplantation. *Transplantation* 2000;70:1604.
41. Lee SG, Park KM, Hwang S, Lee YJ, Choi DN, Kim KH, et al. Congestion of right liver graft in living donor liver transplantation. *Transplantation* 2001;71:812-7.
42. Couinaud C. The paracaval segments of the liver. *J Hepatobiliary Pancreat Surg* 1994;2:145.
43. Sugawara Y, Makuuchi M, Kaneko J, Ohkubo T, Matsui Y, Imamura H. New venoplasty technique for the left liver plus caudate lobe in living donor liver transplantation. *Liver Transpl* 2002;8:76-7.
44. Ghobrial R, Hsieh CB, Lerner S, Winters S, Nissen N, Dawson S, et al. Technical challenges of hepatic venous outflow reconstruction in right lobe adult living donor liver transplantation. *Liver Transpl* 2001;7:551-5.
45. Sugawara Y, Makuuchi M, Akamatsu N, Kishi Y, Niiya T, Kaneko J, et al. Refinement of venous reconstruction using cryopreserved veins in right liver grafts. *Liver Transpl* 2004;10:541-7.
46. Sugawara Y, Makuuchi M, Sano K, Imamura H, Kaneko J, Ohkubo T, et al. Vein reconstruction in modified right liver graft for living donor liver transplantation. *Ann Surg* 2003;237:180-5.
47. Millis JM, Seaman DS, Piper JB, Alonso EM, Kelly S, Hackworth CA, et al. Portal vein thrombosis and stenosis in pediatric liver transplantation. *Transplantation* 1996;62:748-54.
48. Kuagn A, John FR, Linda DF, Ernest JR, Rosenthal P, Lim RC, et al. Failure patterns of cryopreserved vein grafts in liver transplantation. *Transplantation* 1996;62:742-7.
49. Marcos A, Orloff M, Miele L, Olzinski AT, Renz JF, Sitzmann JV. Functional venous anatomy for right-lobe grafting and techniques to optimize outflow. *Liver Transpl* 2001;10:845-52.
50. Tetsuya K, Kenichiro K, Hiroyuki S, Soichiro I, Tsuyoshi H, Kenro S, et al. Intrahepatic anastomosis formation between the hepatic veins in the graft liver of the living related liver transplantation: observation by doppler ultrasonography. *Transplantation* 2000;70:982-5.
51. Elias H, Petty D. Gross anatomy of the blood vessels and ducts within the human liver. *Am J Anat* 1952;90:59-111.
52. Widman WD, Hales MR, Greenspan RH. The effects of hepatic vein occlusion. *Am J Pathol* 1962;41:439-54.
53. Nakamura S, Sakaguchi S, Hachiya T, Suzuki S, Nishiyama R, Konno H, et al. Significance of hepatic vein reconstruction in hepatectomy. *Surgery* 1993;114:59-64.
54. Sano K, Makuuchi M, Takayama T, Sugawara Y, Imamura H, Kawarasaki H. Technical dilemma in living-donor or split-liver transplant. *Hepato-Gastroenterology* 2000;47:1208-9.
55. Sano K, Makuuchi M, Miki K, Maema A, Sugawara Y, Imamura H, et al. Evaluation of hepatic venous congestion: Proposed indication criteria for hepatic vein reconstruction. *Ann Surg* 2002;236:241-7.
56. Harihara Y, Makuuchi M, Kawarasaki H, Takayama T, Kubota K, Hirata M, et al. Portal venoplasty for recipients in living-related liver transplantation. *Transplantation* 1999;68:1199-200.
57. Lee SG, Hwang S, Kim KH, Ahn CS, Park KW, Lee YJ, et al. Approach to anatomic variations of the graft portal vein in right lobe living-donor liver transplantation. *Transplantation* 2003;75:S28-S32.
58. Sugawara Y, Kaneko J, Akamatsu N, Makuuchi M. Arterial anatomy unsuitable for a right liver donation. *Liver Transpl* 2003;9:1116-7.
59. Kishi Y, Sugawara Y, Kaneko J, Akamatsu N, Imamura H, Asato H, et al. Hepatic arterial anatomy for right liver procurement from living donors. *Liver Transpl* 2004;10:129-33.
60. Sakamoto Y, Takayama T, Nakatsuka T, Asato H, Sugawara Y, Sano K, et al. Advantage in using living donors with aberrant hepatic artery for partial liver graft arterialization. *Transplantation* 2002;74:518-21.
61. Stewens LH, Emond JC, Piper JB, Heffron TG, Thistlethwaite JR, Whittington PF, et al. Hepatic artery thrombosis in infants-a comparison of whole livers, reduced-size grafts, and grafts from living donors. *Transplantation* 1992;53:396.
62. Mazzaferro V, Esquivel CO, Makowka L, Belle S, Kahn D, Koneru B, et al. Hepatic artery thrombosis after pediatric liver transplantation: a medical or surgical event? *Transplantation* 1989;47:971-7.
63. Broelsch CE, Whittington PF, Emond JC, Heffron TG, Thistlethwaite JR, Stevens L, et al. Liver transplantation in children from living-related donors: surgical techniques and results. *Ann Surg* 1991;214:428-39.
64. Mori K, Nagata I, Yamagata S, Sasaki H, Nishizawa F, Takada Y, et al. The introduction of microvascular surgery to hepatic artery reconstruction in living-donor liver transplantation: its surgical advantages compared with conventional procedures. *Transplantation* 1992;54:263-8.
65. Ikegami T, Kawasaki S, Matsunami H, Hashikura Y, Nakazawa Y, Miyagawa S, et al. Should all hepatic arterial branches be reconstructed in living-related liver transplantation? *Surgery* 1996;119:431-6.
66. Marcos A, Killackey M, Orloff MS, Miele L, Bozorgzadeh A, Tan HP. Hepatic arterial reconstruction in 95 adult right lobe living donor liver transplants: evolution of anastomotic technique. *Liver Transpl* 2003;9:570-4.
67. Marcos A, Orloff M, Miele L, Olzinski A, Sitzmann J. Reconstruction of double hepatic arterial and portal venous branches for right-lobe living donor liver transplantation. *Liver Transpl* 2001;8:673-9.
68. Redman HC, Reuter SR. Arterial collaterals in the liver

- hilus. *Radiology* 1970;94:575-9.
69. Kubota K, Makuuchi M, Takayama T, Harihara Y, Hasegawa K, Aoki T. Simple test on the back table for justifying single hepatic-arterial reconstruction in living related liver transplantation. *Transplantation* 2000;70: 696-7.
 70. Dulundu E, Sugawara Y, Sano K, Kishi Y, Akamatsu N, Kaneko J, et al. Duct-to-duct biliary reconstruction in adult living donor liver transplantation. *Transplantation* in press.
 71. Soejima Y, Shimada M, Suehiro T, Kishikawa K, Minagawa R, Hiroshige S, et al. Feasibility of duct-to-duct biliary reconstruction in left-lobe adult-living-donor liver transplantation. *Transplantation* 2003;75: 557.
 72. Ishiko T, Egawa H, Kasahara M, Nakamura T, Oike F, Kaihara S, et al. Duct-to-duct biliary reconstruction in living donor liver transplantation utilizing right lobe graft. *Ann Surg* 2002;236:235.
 73. Sugawara Y, Makuuchi M, Sano K, Ohkubo T, Kaneko J, Takayama T. Duct-to-duct biliary reconstruction in living-related liver transplantation. *Transplantation* 2002;73:1348.
 74. Icoz G, Kilic M, Zeytunlu M, Celebo A, Ersoz G, Killi R, et al. Biliary reconstructions and complications encountered in 50 consecutive right-lobe living donor liver transplantations. *Liver Transpl* 2003;9:575-80.
 75. Settmacher U, Steinmuller TH, Schmid SC, Heise M, Pascher A, Theruvath T, et al. Technique of bile duct reconstruction and management of biliary complications in right lobe living donor liver transplantation. *Clin Transplant* 2003;17:37.
 76. Makuuchi M, Kawasaki S, Noguchi T, Hashikura Y, Matsunami H, Hayashi K, et al. Donor hepatectomy for living related partial liver transplantation. *Surgery* 1993;113:395-402.
 77. Stapleton GN, Hickman R, Terblanche J. Blood supply of the right and left hepatic ducts. *Br J Surg* 1998;85: 202-7.
 78. Nagasue N, Kohno H, Matsuo S, Yamanoi A, Uchida M, Takemoto Y, et al. Segmental (partial) liver transplantation from a living donor. *Transplant Proc* 1992; 24:1958.
 79. Harihara Y, Makuuchi M, Sakamoto Y, Sugawara Y, Inoue K, Hirata M, et al. A simple method to confirm patency of the graft bile duct during living-related partial liver transplantation. *Transplantation* 1997;64: 535-7.
 80. Scatton O, Meunier B, Cherqui D, Boillot O, Sauvanet A, Boudjema K, et al. Randomized trial of choledochocholangiostomy with or without a T tube in orthotopic liver transplantation. *Ann Surg* 2001;233:432.
 81. Testa G, Malago M, Valentin GC, Lindell G, Broelsch CE. Biliary anastomosis in living related liver transplantation using the right liver lobe: techniques and complications. *Liver Transpl* 2000;6:710.