

# Acute Myocardial Infarction Caused by Coronary Artery Dissection Following Blunt Chest Trauma

Se Jung Yoon, Hyuck Moon Kwon, Dongsoo Kim, Bum Kee Hong, Dong-Yeon Kim, Yun-Hyeong Cho, Byung Seung Kang, and Hyun-Seung Kim

*Department of Internal Medicine, Yonsei University College of Medicine, Seoul, Korea.*

Chest trauma can lead to various cardiac complications ranging from simple arrhythmias to myocardial rupture. An acute myocardial infarction (AMI) is a rare complication that can occur after chest trauma.

We report a case of 66-year-old male who suffered a blunt chest trauma from a traffic accident resulting in an AMI. The coronary angiography revealed an eccentric 50% narrowing of the ostium of left anterior descending artery (LAD) by a dissection flap with calcification. Intravascular ultrasonography (IVUS) revealed eccentric calcified plaque (minimal luminal diameter [MLD]=3.5 mm) with a dissection flap. Intervention was not performed considering the MLD and calcified flap, and he has been conservatively managed with aspirin and losartan for 2 years. The follow-up coronary angiography showed an insignificant luminal narrowing of the proximal LAD from the ostium without evidence of a dissection.

An early coronary evaluation including an IVUS study should be considered for managing patients who complain of ongoing, deep-seated chest pain with elevated cardiac enzyme levels and an abnormal electrocardiogram (ECG) after a blunt chest trauma. Based on this case, some limited cases of traumatic coronary artery dissections can be healed with conservative management and result in a good prognosis.

**Key Words:** Trauma, myocardial infarction, coronary artery dissection

## INTRODUCTION

An acute myocardial infarction (AMI) is a rare complication that can occur after a blunt chest trauma.<sup>1,2</sup> A blunt chest trauma can lead to cardiac

complications ranging from non-significant arrhythmias to a myocardial rupture.<sup>1</sup>

A variety of injuries to the coronary arteries, including lacerations, thrombosis, intimal dissection, arteriovenous fistula and pseudoaneurysm formation are rare sequela occurring after a blunt trauma.<sup>1</sup>

We report a case of a 66-year-old male who had a blunt chest trauma from a traffic accident resulting in an AMI due to a dissection of the LAD and ostium with calcification. After two years of medical treatment, the following coronary angiography of the patient showed an improved luminal narrowing of the lesion, and complete healing of the previous dissection.

## CASE REPORT

A 66-year-old man with no known medical problems was admitted to hospital because of dyspnea and deep-seated chest pain. Approximately 20 hours earlier, he had suffered blunt chest trauma as a result of a traffic accident.

He had none of the risk factors for ischemic heart disease. On a physical examination, his blood pressure was 110/60 mmHg, heart rate 70 beats per minute, and respiration rate 20 per minute. He had a decreased breathing sound in both lung fields and an asymmetric respiratory movement of the chest wall.

The chest film demonstrated a slight enlarged heart size with multiple fractures in the bilateral ribs (from the 8th to 9th of right and from the 6th to 7th of left ribs) and a pleural effusion (Fig. 1). In addition, the ECG showed a ST segment

Received October 21, 2002

Accepted March 14, 2003

Reprint address: requests to Dr. Hyuck Moon Kwon, Department of Internal Medicine, Yonsei University College of Medicine, 134 Shinchon-dong, Seodaemun-gu, Seoul 120-752, Korea. Tel: 82-2-3497-3334, Fax: 82-2-573-0112, E-mail: hmkwon@yumc.yonsei.ac.kr

elevations in the lead V2 - V5, and Q waves in the lead V1 - V5 (Fig. 2).

The serum creatinine kinase level was 6,550 U/L with a positive MB fraction (443.8 ng/ml), and an elevated serum Tn-T level (6.96 ng/ml) was noted.

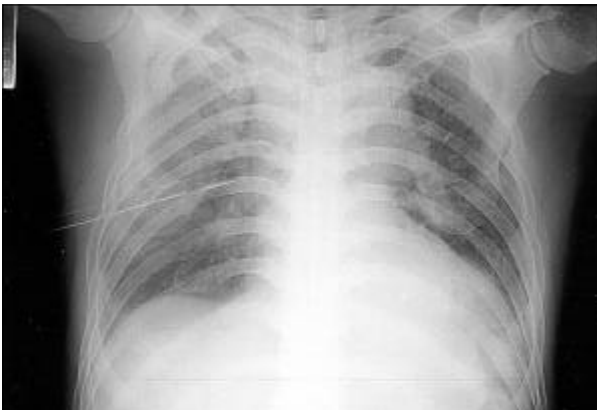On admission, the bedside echocardiography revealed normal sized cardiac chamber dimensions with a reduced left ventricular systolic function (ejection fraction=40%) and akinesia of the anterior and anteroseptal segments from the base to the apex without thinning. The results of the thallium-201 perfusion scan were consistent with the presence of an anterior wall infarct. Coronary angiography revealed an eccentric and discrete 50% narrowing of the ostium of the LAD that

appeared to have resulted from a dissected flap (Fig. 3). IVUS was performed, which showed eccentric calcified plaque with a dissection at the ostium of the LAD (MLD=3.5 mm) (Fig. 4).

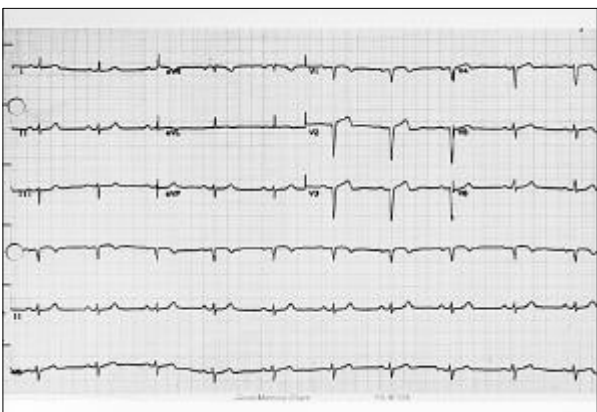
He remained hemodynamically stable without chest pain or dyspnea during admission and had been given losartan 50 mg and aspirin 100 mg daily for 2 years.

Two years later, a follow-up coronary angiography revealed tubular eccentric 20% luminal narrowing of the proximal LAD from the ostium with severe calcification and complete healing of a previous dissection (Fig. 5).

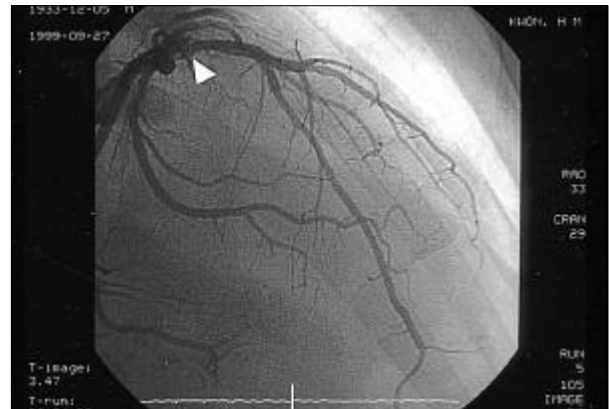
The echocardiography showed a slightly improved left ventricular systolic function (ejection



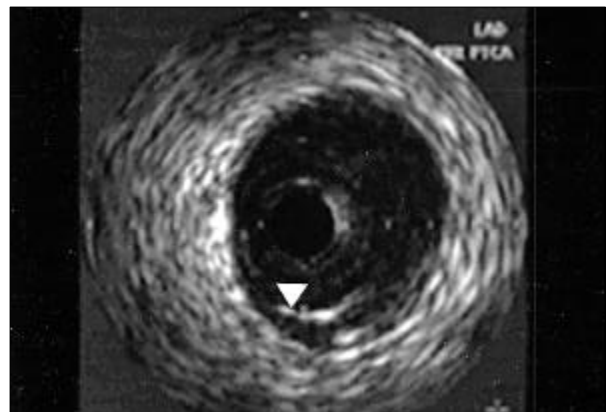
**Fig. 1.** The initial chest film demonstrated a slight enlarged heart size with multiple fractures in bilateral ribs and pleural effusion, so chest tube was inserted at emergency department.



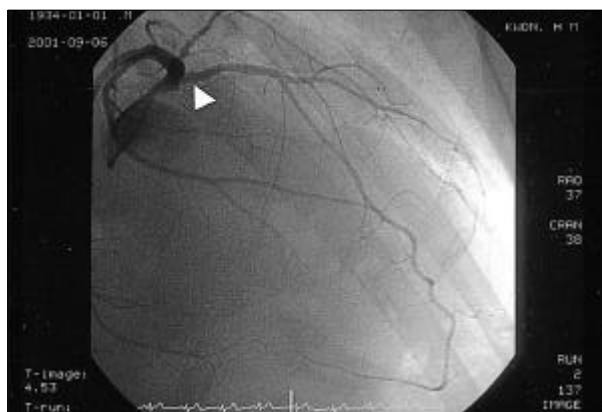
**Fig. 2.** The initial electrocardiogram showed ST segment elevation in lead V1-V3 and Q wave in lead V1-V3, which suggested acute myocardial infarction.



**Fig. 3.** Coronary angiography revealed eccentric and discrete 50% narrowing of ostium of the left anterior descending artery (LAD) that seemed to be resulted from dissected flap.



**Fig. 4.** Intravascular ultrasonography (IVUS) showed eccentric calcified plaque with dissection at the ostium of LAD (MLD=3.5 mm). Arrow head: dissecting flap.



**Fig. 5.** Follow up coronary angiography revealed tubular eccentric 20% luminal narrowing of proximal LAD from ostium with severe calcification and complete healing of previous dissection.

fraction=45%) without an improvement in the regional wall motion abnormalities (akinesia of the anterior and the anteroseptal wall from the mid LV to apex with thinning).

## DISCUSSION

Blunt chest trauma can cause cardiac complications ranging from supraventricular arrhythmia to a valvular and myocardial rupture.

Injuries to the coronary arteries are rare, but they can significantly increase the risk of mortality from AMI.<sup>1-3</sup> The proposed causes of an AMI following a blunt chest trauma include a variety of injuries to the coronary arteries, such as laceration, thrombosis, intimal dissection, arteriovenous fistula and pseudoaneurysm.<sup>1</sup> Thrombosis is the main suspect in the pathogenesis of a coronary occlusion following trauma.<sup>1,4</sup>

The mechanism leading to a myocardial infarction after a blunt chest trauma is a shear force applied to the coronary artery, which causes intimal tearing. The intimal injury in turn precipitates platelet aggregation and an intracoronary thrombosis.<sup>5</sup>

Compression of the anterior chest wall and the shear forces in the arterial wall generated by the sudden deceleration during impact are presumed to be for the cause of the arterial injury.<sup>6</sup>

The LAD is the most frequently injured, fol-

lowed by the right coronary, and the circumflex artery being the least involving lesion.<sup>4,7,8</sup> The higher incidence of a left anterior descending artery involvement may be due to its proximity to the chest wall. The possibility that preexisting atherosclerotic plaque may predispose the vessel wall to a traumatic disruption at that site has been suggested.<sup>5</sup>

IVUS provides a cross-sectional view of a specific portion of the vasculature. It is useful for detecting mild coronary atherosclerotic disease, assessing an angiographically intermediate lesion, and a coronary stenosis before and after the catheter-based coronary artery intervention. Left main coronary artery lesions, which are often difficult to quantify using angiography because of the overlapping branches, diffuse diseases, or the ostial location of the disease, are ideally suited for a study with IVUS. It provides a method for describing and classifying the morphological characteristics of the coronary vessels, and the effects of coronary angioplasty.<sup>9,10</sup>

This information could be used to determine the most suitable strategy for treating the dissection.<sup>8</sup>

Moreover, it is possible to overcome the limited ability of angiography in assessing the disease mechanism using IVUS. In this case, the IVUS findings suggest that the intimal dissection in the ostium of LAD with a preexisting intermediate lesion resulted from a chest trauma can cause the thrombotic occlusion and myocardial infarction.

In several cases, a coronary artery dissection can heal spontaneously with few exceptions such as this case.<sup>8,11,12</sup> In this case, intervention was not recommended because of the so far enough MLD (3.5 mm) and the calcified flap. In addition, the management of patients with multiple blunt chest trauma in the acute phase using thrombolytic therapy is contentious, because it may worsen the dissection itself and increase the risk of hemorrhage.<sup>13</sup> Emergency coronary artery bypass surgery also has been reported to have good results in some adequate cases, but such a major operation can be accompanied by much higher risk of post-operative complications in multiple traumatic patients.<sup>14</sup> Myocardial scintigraphy, which reveals the viability of the myocardium, can help in making the decision for intervention.

In conclusion, when patients with chest trau-

ma have symptoms and electrocardiographic changes suggesting an AMI, immediate coronary angiography should be considered. Further management may depend on the angiographic findings.

## REFERENCES

1. Barton EN, Henry R, Martin AS, Ince W, Bartholomew C. Acute myocardial infarction following blunt chest trauma due to the kick of a cow. *West Indian Med J* 1988;37:236-9.
2. Tengler ML. The spectrum of myocardial trauma. *J Trauma* 1985;25:620-7.
3. Salmi AI, Blank M, Slomski C. Left anterior descending artery occlusive after blunt chest trauma. *J Trauma* 1996;40:832-4.
4. Vlay SC, Blumenthal DS, Shoback D, Fehir K, Bulkley BH. Delayed acute myocardial infarction after blunt chest trauma in a young woman. *Am Heart J* 1980;100: 907-16.
5. Marcum J, Booth D, Sapin P. Acute myocardial infarction caused by blunt chest trauma : Successful treatment by direct coronary angioplasty. *Am Heart J* 1996; 132:1275-7.
6. Neiman J, Hui WKK. Posteromedial papillary muscle rupture as a result of right coronary artery occlusion after blunt chest trauma. *Am Heart J* 1992;123:1694-7.
7. Goulah RD, Rose MR, Strober M, Haft JL. Coronary dissection following chest trauma with systemic emboli. *Chest* 1988;93:887-8.
8. Chun JH, Lee SC, Gwon HC, Lee SH, Hong KP, Seo JD, et al. Left main coronary artery dissection after blunt chest trauma presented as acute anterior myocardial infarction: assessed by intravascular ultrasound. *J Korean Med Sci* 1998;13:325-7.
9. Waller BF, Pinkerton CA, Slack JD. Intravascular ultrasound: a historical study of vessels during life. The new 'gold standard' for vascular imaging. *Circulation* 1992;85:2305-10.
10. Honye J, Mahon DJ, Jain A, White CJ, Ramee SR, Wallis JB, et al. Morphological effects of coronary balloon angioplasty *in vivo* assessed by intravascular ultrasound imaging. *Circulation* 1992;85:1012-25.
11. Marik PF. Coronary artery dissection after a rugby injury. *S Afr Med J* 1990;77:586-7.
12. Kahn JK, Buda A. Long-term follow-up of coronary artery occlusion secondary to blunt chest trauma. *Am Heart J* 1987;113:207-10.
13. Anto J, Cokinos S, Jonas E. Acute anterior wall myocardial infarction secondary to blunt chest trauma. *Angiology* 1984;35:802-4.
14. Gaspard P, Clermont A, Villard J. Noniatrogenic trauma of coronary arteries and myocardium: a contribution of angiography. *Cardiovasc Intervent Radiol* 1983; 6:20-4.