

## Bilateral Sternalis with Unusual Left-Sided Presentation: A Clinical Perspective

Hitendra Kumar<sup>1</sup>, Gayatarti Rath<sup>1</sup>, Mahesh Sharma<sup>2</sup>, Mangala Kohli<sup>1</sup>, and Bidya Rani<sup>1</sup>

<sup>1</sup>Department of Anatomy, Lady Hardinge Medical College, New Delhi, India;

<sup>2</sup>Department of Anatomy, Pt. B. D. S. Post Graduate Institute of Medical Sciences, Rohtak, Haryana, India.

An unusual variation creates interest among anatomists, but is a cause of concern among clinicians when it mimics a pathology. The sternalis muscle is one such variant of the anterior chest wall located subcutaneously over the pectoralis major, ranging from a few short fibers to a well-formed muscle. We observed a bilateral case, which was accompanied by an atypical presentation on the left side where a huge, bulky sternalis muscle was associated with the absence of the sternal fibers of the pectoralis major. The fibers arose as a lateral strip from the upper two-thirds of the body of the sternum and costal cartilages 2 through 6 with the intervening fascia and aponeurosis of the external oblique. The right sternalis was strap-like and was placed vertically over the sternal fibers of the pectoralis major, arising from the underlying fascia and aponeurosis of the external oblique. The sternalis muscles, on each side, converged into an aponeurosis over the manubrium that was continuous with the sternal heads of the right and left sternocleidomastoid muscle, respectively. This rare anomaly has puzzled radiologists and surgeons in confirming diagnosis, missing it all together or mistaking it for a tumor on mammography or CT scan. These findings prompted us to review its topography, development, and application in relation to the anterior chest wall.

**Key Words:** Sternalis, pectoralis major, aponeurosis, radiologists, surgeons, mammography

### INTRODUCTION

The finding of the sternalis muscle is a rare entity of the anterior chest wall that challenges

our understanding of the anatomy of the parasternal region. Though described by Turner,<sup>1</sup> its development, nerve supply, and function are debatable. It has been reported in either sex, and in blacks, whites, as well as, in Asians.<sup>2-4</sup> The incidence varies in the different ethnic groups, and ranges from less than 0.5% in the Taiwanese population to 17.3% in the Chinese.<sup>4</sup> When present, it lies superficial to the pectoralis major and parallel to the sternum, and extends from the jugular notch to the costal region. Kitamura, et al.,<sup>5</sup> however, reported an isolated case of a partially defective pectoralis major accompanied by the sternalis muscle of an enormous size. In clinical practice, it is essential for radiologists and surgeons to acknowledge this anomaly as it may pose a diagnostic dilemma, mimicking a malignant breast mass on mammography, CT scan, or MR imaging, and an unnecessary exploratory surgery can be avoided.<sup>6,7</sup>

### CASE REPORT

The sternalis muscle was present bilaterally in an adult male, formalin-preserved cadaver, situated on either side of the sternum, extending from the manubrium to the costal region (Fig. 1).

#### Left side

The sternalis on this side was exceptionally large and bulkier, extending from the jugular notch to the 6<sup>th</sup> costochondral junction. It measured 13.5 cm in length and 5.5 cm at the broadest part. The fibers were arranged in superficial and

Received October 22, 2002

Accepted January 30, 2003

Reprint address: requests to Dr. Hitendra Kumar, J-974, Ansals Palam Vihar, Gurgaon, Haryana, India-122017. Tel: 0091-0124-2369823, E-mail: drhitendra3@yahoo.com, gayatrirath@hotmail.com

deeper strata. The superficial fibers arose from the lateral aspect of the sternum, extending up to the 6<sup>th</sup> costal facet and the aponeurosis of the external oblique. The deeper fibers arose from costal cartilages 2 through 6, their respective costochondral junctions, and the intervening anterior intercostal membranes. Both the superficial and the deep fibers ran obliquely upwards and medially towards the manubrium and became aponeurotic over its surface. This aponeurosis was common for the left and the right sternalis muscles, and continued with the sternal fibers of the left and right sternocleidomastoid muscles, respectively (Fig. 1). Surprisingly, on this side the pectoralis major had no sternal origin. In spite, these fibers arose from ribs 3 through 7 near the costochondral junctions and the aponeurosis of the external oblique (Fig. 2). The sternalis muscle on this side replaced the sternal fibers of the pectoralis major. Due to the presence of the sternalis muscle, the costal fibers remained separated from the clavicular fibers by a triangular gap. The medial pectoral nerve traversed through this gap and supplied the sternalis from its deeper aspect. The clavicular heads of the pectoralis major and minor

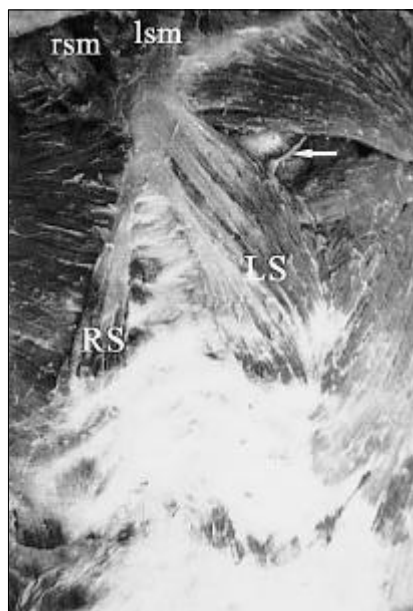
were normal.

### Right side

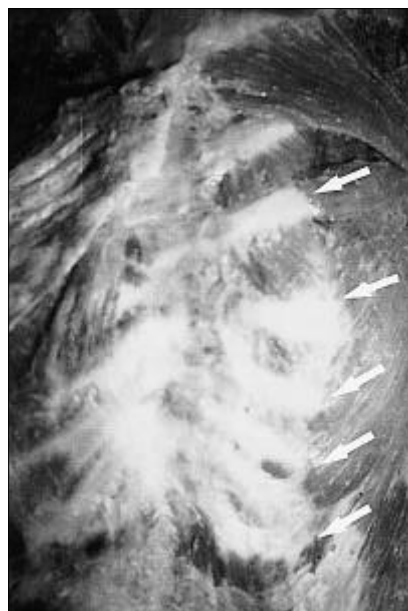
The right sternalis muscle was strap-like, flattened anteroposteriorly and positioned over the pectoralis major. It measured 11.0cm in length and 2.5cm at its broadest part. The upper and lower ends were aponeurotic; and the former converged over the manubrium while the latter merged with the aponeurosis of the external oblique (Fig. 1). It was supplied by the medial pectoral nerve, as was the case on the left side. The sternocostal and clavicular attachments of the pectoralis major were found to be normal on this side.

### DISCUSSION

The origin and nerve supply of the sternalis muscle have been a conundrum for anatomists. Bannister, et al.<sup>8</sup> view this muscle as a misplaced pectoralis major. Embryologists,<sup>9-11</sup> however, describe it as a derivative of myotomic hypomeres,



**Fig. 1.** Anterior chest wall showing enlarged left sternalis (LS) and strap-like right sternalis (RS) muscles. The upper aponeurotic attachment of both muscles is continuous with the sternal heads of the left and right sternocleidomastoid (lsm and rsm). Note the medial pectoral nerve (arrow) supplying the left sternalis.



**Fig. 2.** Left sternalis removed to view the absence of sternal fibers of left pectoralis major. These fibers arise from ribs 3 to 7 (arrows).

which form muscles of the ventral and lateral body walls in the thorax and abdomen. These muscles include the three intercostals of the thorax, the homologous three layers of the abdominal musculature (the external oblique, internal oblique, and transverses abdominis), and the rectus abdominis that flank the ventral midline. The rectus column is usually limited to the abdominal region, but sometimes may persist onto either side of the sternum as the sternalis muscle. In the cervical region, hypomeres form the strap muscles of the neck. O'Neill and Folan-Curran<sup>12</sup> highlighted differing views on the origin of this muscle, namely, pectoralis major, rectus abdominis, sternomastoid, and panniculus carnosus. Most authors opined its derivation from pectoralis major. Kida, et al.<sup>13</sup> worked on 40 cases over 15 years and discovered that the sternalis muscle is supplied by the pectoral nerves. Branches of the intercostal nerves may pierce the muscle to become cutaneous, but do not directly supply the sternalis. In our finding, the medial pectoral nerve supplied the sternalis from the deep surface after supplying the pectoralis major muscle. Though Kitamura<sup>5</sup> observed an enlarged sternalis with partial absence of the pectoralis major, its attachments were not clear. In our study, the sternalis was present bilaterally with the left showing hypertrophy and absence of the sternal fibers of the pectoralis major, and the right being strap-like with no bony origin. Thus, it is presumed that in this case, the left sternalis may be the remnant of the ventral tip of the hypomeres in the thoracic region considered as derivative of the rectus column, whereas the right sternalis may be a derivative of panniculus carnosus, as described by Barlov<sup>2</sup> and Shen, et al.<sup>4</sup>

### Clinical perspective

With the use of sophisticated diagnostic and therapeutic tools, there is a need to record and discuss unusual anatomical variants. They may appear pathological, making the diagnosis difficult for the radiologist or surgeon. The sternalis muscle can be easily overlooked during breast surgeries, and often cause a diagnostic dilemma on mammography or CT scan. Bailey<sup>14</sup> conducted a survey among physicians, medical students, sur-

gery and plastic surgery residents, and faculty from other disciplines. Surprisingly, the results revealed a near-total unfamiliarity with this muscle. This may not be due to a lesser incidence, but to a lack of encounter during surgery and imaging. With improved radiological imaging procedures, the sternalis muscle will be noted more frequently than in previous years.<sup>6</sup>

The sternalis muscle can mimic a malignant breast mass on mammography. Bradley, et al.<sup>6</sup> gave the first description of this muscle in breast imaging literature but could establish the fact only after an open biopsy for a suspected breast tumor. Afterwards, they found 4 sternalis muscles in 32,000 mammograms done over a period of 15 years. Bailey<sup>14</sup> noted this muscle in 3 patients undergoing mastectomy over 15 years. The medial side of the breast is considered a potential blind spot on mammography in the mediolateral projection. Radiologists must visualize this area in the craniocaudal projection with adequate positioning and traction of the breast to maximize the volume of the tissue and to include the mobile margins.<sup>6</sup> The mammographic appearance of pectoralis major is variable. It may appear as a slight bulge centrally or be eccentrically located in the field of view, and take the form of a small asymmetric density projecting into the medial side of the breast. This is described as a bulge in the pectoralis major; and radiologists can misinterpret it as a focal parenchymal lesion.<sup>6</sup> In fact, this focal bulge may not be pectoralis major but rather the sternalis muscle. Thus, a proper diagnosis depends upon its location, orientation, and absence of corresponding abnormality on lateral views. In case of any confusion, CT scan or MR imaging can aid in establishing the diagnosis.

### REFERENCES

1. Turner W. On the musculus sternalis. *J Anat Physiol* 1867;1:246-53.
2. Barlow RN. The sternalis muscle in American whites and Negroes. *Anat Rec* 1935;61:413-26.
3. Kida MY, Kudoh H. Innervation of the sternalis muscle accompanied by congenital partial absence of pectoralis major muscle. *Okajimas Folia Anatomica Japonica* 1991; 67:449-55.
4. Shen CL, Chien CH, Lee SH. A Taiwanese with a pair

- of sternalis muscles. *Acta Anatomica Nipponica* 1992;67:625-54.
5. Kitamura S, Yoshioka T, Kaneda M, Matsuoka K, Chen KL, Sakai A. A case of the congenital partial defect of the pectoralis major accompanied by the sternalis with enormous size. *Kaibogaku Zasshi J Anat* 1985;60:728-32.
  6. Bradley FM, Hoover HCJ, Hulka CA, Whitman GJ, McCarthy KA, Hall DA, et al. The sternalis muscle: An unusual normal finding seen on mammography. *Am J Roentgenol* 1996;166:33-6.
  7. Britton CA. Subpectoral mass mimicking a malignant breast mass on mammography (letter). *Am J Radiol* 1992;159:221.
  8. Bannister L H, Berry M, Collins P, Dyson M, Dussek JE, Ferguson MWJ. *Grays Anatomy*. 38th ed. New York: Churchill Livingstone; 1995. p.838.
  9. Hamilton WJ, Mossman HW. *Human embryology*. 4<sup>th</sup> ed. London: The McMillan press Ltd.; 1976. p.552.
  10. Larsen WJ. *Essentials of human embryology*. 1st ed. New York: Churchill Livingstone; 1998. p.49-51.
  11. Sadler TW. *Muscular system. Langman's Medical Embryology*. 7<sup>th</sup> ed. Baltimore: Williams and Wilkins; 1995. p.68.
  12. O'Neill MN, Folan-Curran J. Case report: bilateral sternalis muscles with a bilateral pectoralis major anomaly. *J Anat* 1998;193:289-92.
  13. Kida M Y, Izumi A, Tanaka S. Sternalis muscle: topic for debate. *Clin Anat* 2000;13:138-40.
  14. Bailey PM, Tzarnas CD. The sternalis muscle: a normal finding encountered during breast surgery. *Plast Reconstr Surg* 1999;103:1189-90.