

# Spinal Epidural Metastasis of Cerebral Oligodendroglioma

Jin Gyun Kim, Chong Oon Park, Dong Keun Hyun, and Young Soo Ha

*Department of Neurosurgery, College of Medicine, Inha University, Sungnam, Korea.*

A 50-year-old male patient with right frontal oligodendroglioma underwent subtotal resection on three separate occasions and, 10 months later, exhibited right frontal oligodendroglioma and extracranial metastasis. Spinal magnetic resonance imaging (MRI) demonstrated the existence of an enhancing mass lesion with evidence of posterior epidural compression at the 10th-11th thoracic level, not involving the vertebrae. A bone scan of the spine appeared normal, but showed evidence of hot uptake in the pelvis and femur. This report concerns a patient who developed a fatal and clinically unexplained, pancytopenia 3 months after the removal of a spinal epidural oligodendroglioma. Oligodendroglioma with metastasis outside the central nervous system is extremely rare, and only a few cases have previously been reported. A brief review of the literature with an emphasis on the mechanisms of tumor cell dissemination is presented.

**Key Words:** Oligodendroglioma, magnetic resonance imaging, spinal epidural metastasis

## INTRODUCTION

### Extracranial metastasis originating from the central nervous system (CNS) is rare

Several reports<sup>1-5</sup> have reviewed the occurrence of this disorder. In 1969, Smith and co-workers<sup>6</sup> reported an incidence of 0.4% among cases of 8000 primary CNS tumors registered at the Armed Forces Institute of Pathology (AFIP). Liwnicz and Rubinstein<sup>3</sup> analyzed 116 cases recorded in the literature up until that time and found that the commonest metastasizing tumor type was glioma (41.4%), followed by medulloblastoma (26.7%), ependymoma (16.4%), astrocytoma (10.3%) and lastly oligodendroglioma (5.25%). The low metastasis rate of oligodendroglioma may be due in part to the relatively low incidence of this type of tumor (4.2% of primary brain tumors), however it must also be partly due to the essential nature of the tumor, since medulloblastoma and ependymoma have a similarly low incidence (6.2% each), yet their metastasis rates are considerably higher.

The organs affected by the distant spread of gliomas are the lungs (about 50%), skeleton (43%), mediastinal and cervical lymph nodes (25% each), liver (17%), as well as the skin, pleura, and kidneys (9%, 5%, and 8%, respectively). This phenomenon is primarily in patients with gliomas who have undergone a previous craniotomy and indeed this phenomenon rarely occurs unless procedures directly affecting the brain have previously been performed, e.g., surgery, ventriculoperitoneal shunt or radiation treatment.<sup>3,4,6,7</sup>

We report on an additional case in which MRI was a critical factor in evaluating the extracranial metastasis of the oligodendroglioma. To our knowledge, this is the first case in our country in which MRI demonstrated the presence of a metastatic spinal epidural mass impinging upon the spinal cord. We report on this case of oligodendroglioma with extraneural metastasis as well as providing a brief review of the literature.

We report on an additional case in which MRI was a critical factor in evaluating the extracranial metastasis of the oligodendroglioma. To our knowledge, this is the first case in our country in which MRI demonstrated the presence of a metastatic spinal epidural mass impinging upon the spinal cord. We report on this case of oligodendroglioma with extraneural metastasis as well as providing a brief review of the literature.

## CASE REPORT

A 50-year-old male patient was admitted to our hospital with a 1-month history of headache, nausea, and seizure in January 1992. Computed

Received July 3, 2002  
Accepted July 25, 2002

Reprint address: requests to Dr. Chong Oon Park, Department of Neurosurgery, Inha Hospital, 7336, Tae Pyung-4 dong, Sujung-gu, Sungnam, Kyungkido 461-712, Korea. Tel: 82-31-720-5391-2, 5836, Fax: 82-31-753-1363, E-mail: nspco@inha.ac.kr

tomographic scanning (Fig. 1A) revealed the presence a right frontal low density lesion, and the patient was radiologically diagnosed as suffering from a low-grade glioma. He was closely followed up until January 1995, at which time he presented symptoms of nausea, and frequent headache, and experienced a seizure attack (Fig. 1B). A stereotactic biopsy was performed. Histologically, the tumor was found to have increased cellularity, being composed of cells with relatively round, elongated and pleomorphic nuclei, suggestive of a benign glioma (Fig. 3A). In June 1997, he was readmitted to the hospital with a headache, nausea, and more frequent seizure attacks. MRI showed the presence of an enlarging mass invading the biopsy site (Fig. 1C). A craniotomy was performed with a near-total resection of the right frontal tumor, which showed the classical morphological features of oligodendroglioma with round nuclei and clear cytoplasm (Fig. 3B). Immunohistochemical staining showed that most tumor cells were negative for glial fibrillary acidic protein (GFAP), but some tumor cells were posi-

tive for S-100 protein. In June 2000, an increase in the seizure frequency was noted. MRI revealed the existence of a large ring enhancing tumor at the same site (Fig. 1D). He underwent a second craniotomy with near-total resection. Microscopically, the primary tumor showed numerous large cells with abundant cytoplasm and eccentric nuclei with frequent mitotic figures and vascular endothelial proliferation, representing an anaplastic oligodendroglioma (Fig. 3C). In February 2001, the patient was readmitted to the hospital because of memory difficulties, auditory hallucinations, diplopia, and left hemiparesis with grade IV. MRI revealed the presence of a large irregular ring enhancing tumor at the same site (Fig. 2A). The tumor and its cystic wall were totally removed surgically. Following surgery, the patient received radiotherapy at a daily dose of 180 cGy in 8 fractions to a total of 5940 cGy from April 4 to May 18, 2001. Histologically, the tumor showed the same pathologic findings as the previous tumors (Fig. 3D). The patient's clinical condition improved progressively and he was discharged

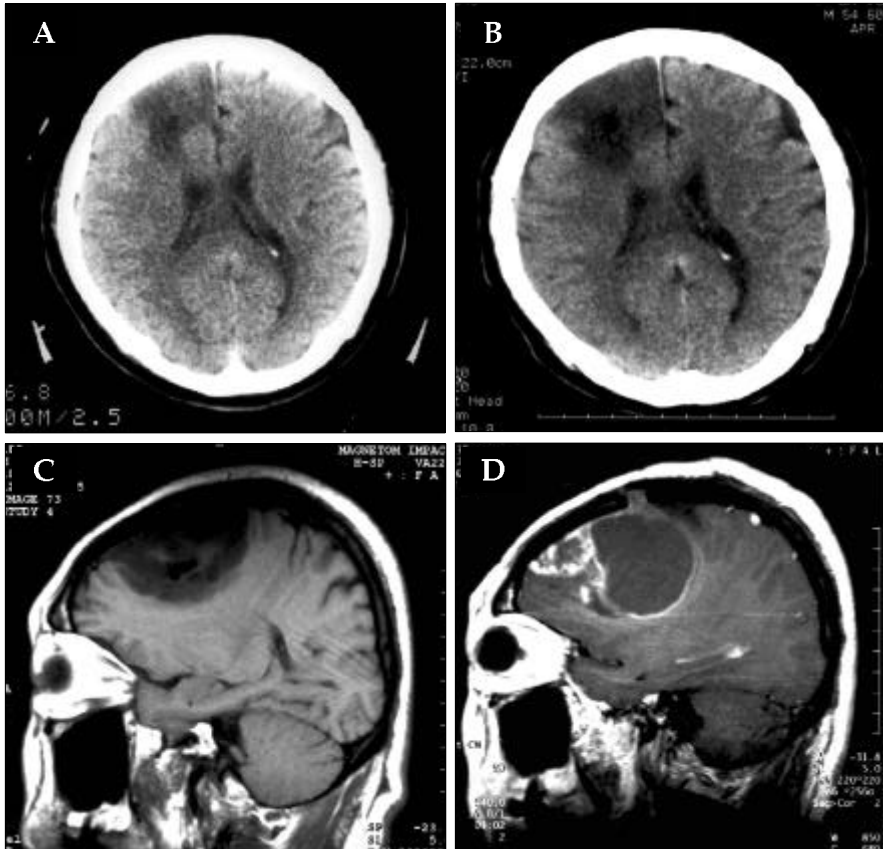
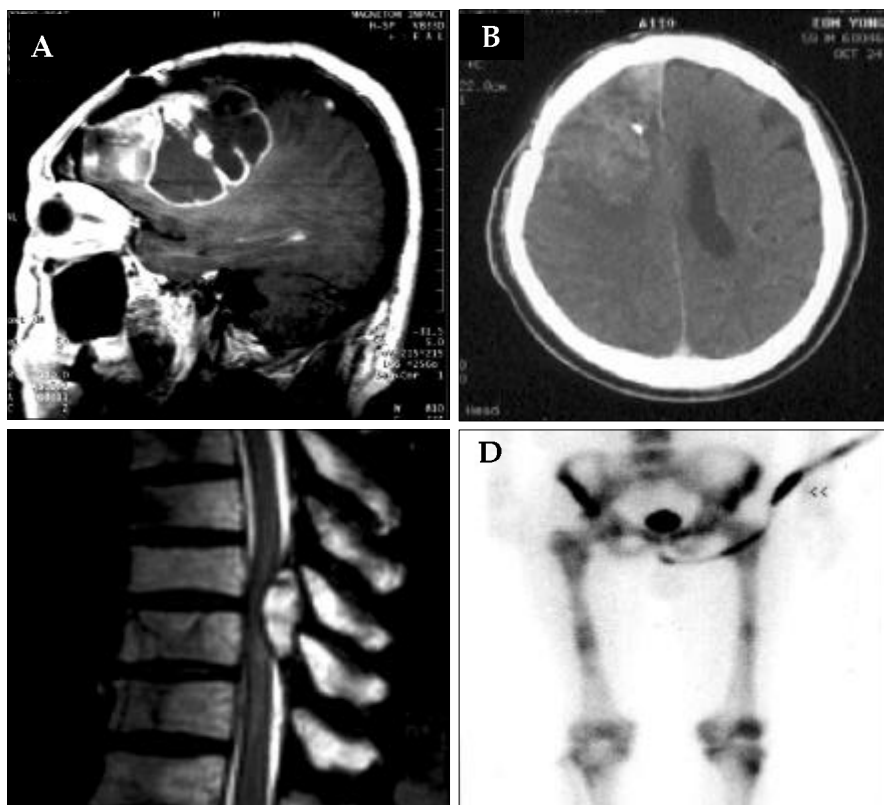


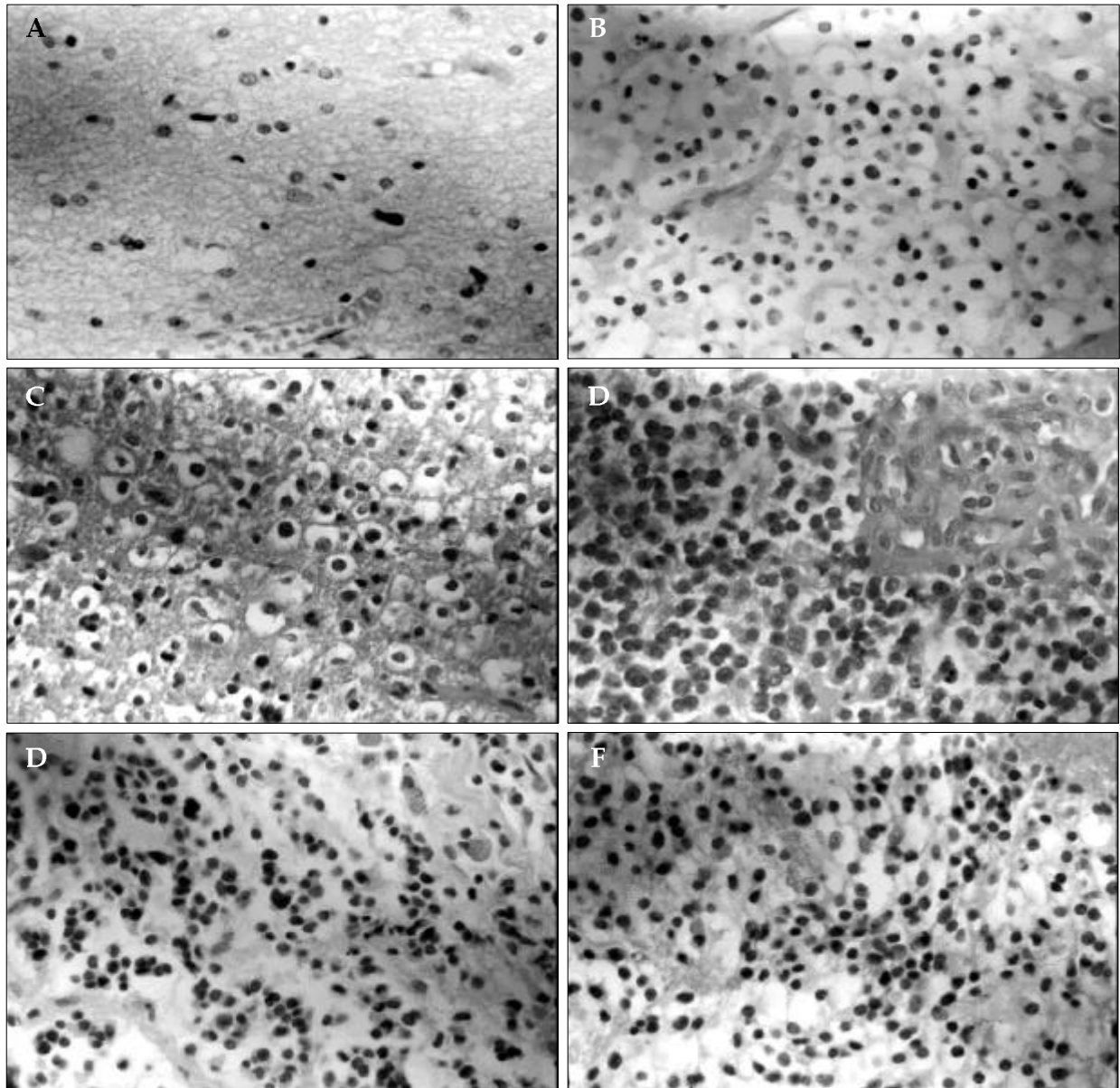
Fig. 1. CT scan images of the brain taken in January '92 (A) and '95 (B) demonstrate the existence of a mass with an irregular margin in the right frontal lobe, representing a low-grade glioma. MRI's taken in June '97 (C) and June '00 (D) show a large ring enhancing mass with a cystic change.

without specific neurological deficits. In October 2001, he complained of a left hemiparesis with grade IV, seizure and low back pain, with some numbness and pain in both legs. However, the plain radiographs of the spine failed to demonstrate the existence of any bone abnormality, except for spondylolysis without listhesis, which was present at the 5th lumbar vertebra. The brain CT scan showed a right frontal mass with high density and calcification (Fig. 2B). The tumor was resected totally, and showed the same features of anaplastic oligodendroglioma (Fig. 3E). Forty-five days later, he complained of weakness in both legs, sensory change below the T11 dermatome, and urinary difficulty. MRI of the spinal cord demonstrated a posterior epidural mass impinging upon the spinal cord at the T10-T11 level (Fig. 2C). In January 2002, A T9-T12 laminectomy was performed. The lamina was removed far enough laterally to adequately expose the neoplasm. Following the removal of a ligamentum flavum, an extradural dark-red mass measuring 4.5 cm in vertical length and 2 cm in transverse length was found, and dissected away from the

dura under the microscope. The tumor was very friable and bloody. Hemostasis was achieved in the bone margins with bone wax, and the epidural veins were cauterized with bipolar cautery (Fig. 4). Histological examination revealed the characteristic features of an oligodendroglioma (Fig. 3F). At that time, no enlarged lymph nodes were detected in either the occipital, cervical, or the inguinal regions. One month later, he complained of buttock and thigh pain. A bone scan was performed, which showed an abnormally increased bony uptake in the pelvis and both femurs (Fig. 2D). Over the course of the following month, the leukocyte and platelet counts steadily declined toward a state of profound pancytopenia (a markedly abnormal hemogram including a hemoglobin of 7.3 g/dl, a hematocrit of 24.7%, a white blood count of 3,900/ul, an erythrocyte count of 2,590,000/ul, and a platelet counts of 56,000/ul), and an adverse drug reaction was suspected. Despite supportive therapy and transfusion, the patient's clinical condition deteriorated progressively and he died 3 months after the laminectomy.



**Fig. 2.** (A) MRI before the 3rd operation shows a mass lesion with an irregular ring enhancing cystic lesion in the right frontal lobe. (B) Post-contrast CT scan before the 4th operation demonstrates an irregular mass with calcification. (C) Post-contrast sagittal T2-weighted image of the spinal cord demonstrates the existence of a posterior epidural enhancing mass measuring 3.5 cm  $\times$  1.1 cm at T10-T11 vertebral level. (D) Bone scan shows an abnormally increased bony uptake in the pelvis and both femurs.

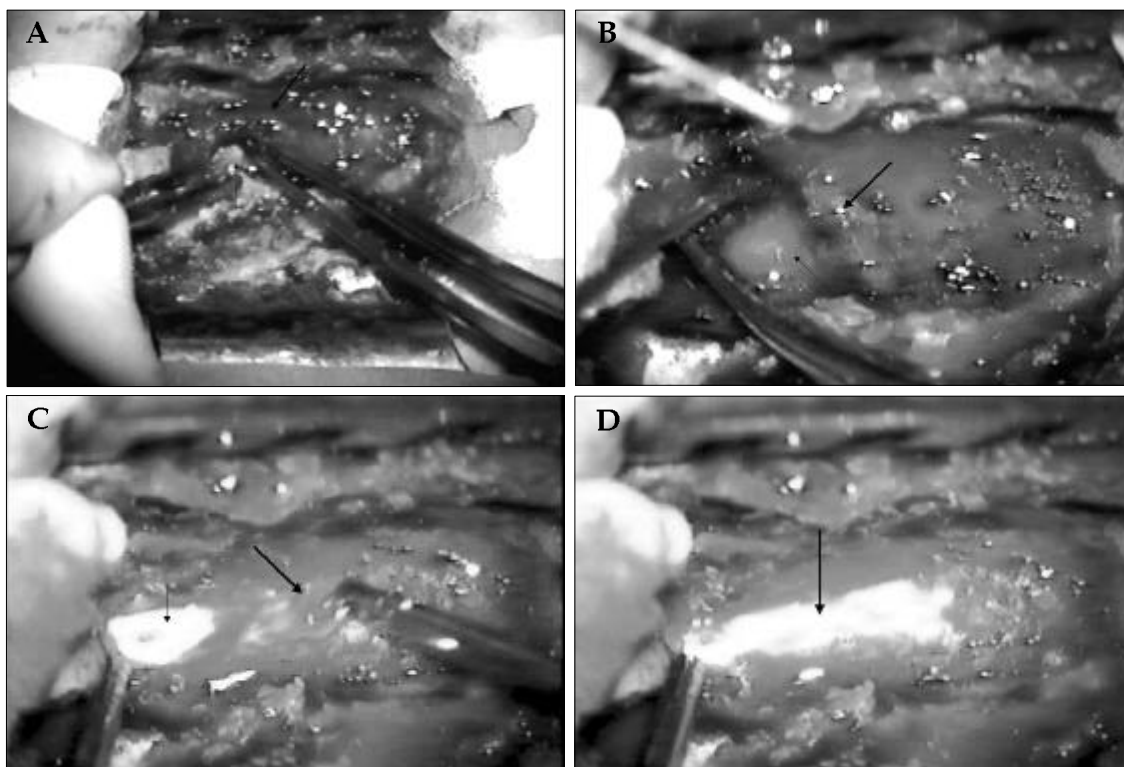


**Fig. 3.** Microphotograph of the primary tumor: (A) the specimen taken by the stereo-tactic biopsy reveals an increased cellularity and cells with relatively round, elongated and pleomorphic nuclei, suggesting a benign glioma; (B) the specimen taken from the 1st operation shows the classical morphological features of oligo-dendroglioma, with round nuclei and clear cytoplasm (Hematoxylin and Eosin stain,  $\times 400$ ). The specimens taken from the 2nd (C), 3rd (D), and 4th (E) operation show numerous large cells with abundant cytoplasm and eccentric nuclei with frequent mitotic figures and vascular proliferation representing an anaplastic oligo-dendroglioma; (F) the specimen taken from the spinal epidural mass reveals many round tumor cells with round nuclei and a small amount of eosinophilic cytoplasm and a focus of endothelial proliferation, which represent oligodendrocytes (H & E stain,  $\times 400$ ).

## DISCUSSION

Neoplasms of the CNS were formerly believed to be unable to metastasize extracranially. However, in 1928, Davis<sup>8</sup> first reported on the case of a 31-year-old woman with spongioblastoma mul-

tiforme that had spread to the soft tissues and lungs following a craniotomy. Subsequently, other case reports described extraneural metastatic diseases, all of which followed neurosurgical procedures. In 1959 Rubinstein<sup>7</sup> documented a case in which the extracranial spread of a medulloblas-



**Fig. 4.** Intraoperative photograph of the spinal epidural oligodendroglioma. (A) The bipolar forceps are used to coagulate the epidural veins and tumor tissue are gently elevated from dura, the dark bloody color tumor (large arrow) and dura (small arrow), (B) the tumor is dissected with micro-dissector (large arrow) and the normal dura is seen (small arrow), (C) the tumor is removed with micro-pituitary forceps (large arrow) and white color is normal dura (small arrow), (D) the tumor mass has been successfully removed from the dura, the normal dura (arrow) is well exposed.

toma occurred independently of any previous craniotomy. In 1967, Rubinstein<sup>9</sup> also reported a case of astrocytoma with extracranial metastasis in the absence of any previous neurosurgical intervention. Spontaneous extracranial metastasis (i.e., without previous neurosurgical intervention) is far less common than the occurrence of such metastasis after surgery. Hoffman and Duffner,<sup>2</sup> in their review in 1985, found only 24 (8.5%) cases of spontaneous metastasis among a total of 282 reported cases of extracranial spread. Spontaneous extraneural metastasis may be even more rare in children (4%) than in adults (11%).<sup>2,4</sup> Dawson<sup>10</sup> reported that the more operations the patient undergoes, the greater the likelihood of local metastatic involvement. Any form of operative intervention physically opens the vascular compartment in the region of the tumor, as well as allowing the recurrent growth a direct access to the extrameningeal tissues. Extraneural metastasis of oligodendroglioma is extremely rare. In a

review of 8000 cases of primary neuroectodermal CNS tumors from the files of the AFIP, Smith et al.<sup>6</sup> found only one case of extraneural metastatic oligodendroglioma. In 1981, Ordoñez et al.<sup>11</sup> reported that only 12 cases had been documented worldwide in the literature. Roberta and German<sup>12</sup> found that 48% of 50 patients with oligodendroglioma without metastasis died within 5 years of their initial symptoms manifesting themselves, with an average survival time of 8.5 years, but that the median survival time of the metastatic oligodendroglioma group was only 32 months.

Primary tumors in the brain, spinal cord, and their coverings spread in three ways: (a) local invasion, (b) seeding via the cerebrospinal fluid pathways, and (c) remotely by the lymphatic and vascular channels.<sup>13</sup> There are no lymphatics in the brain or spinal cord.<sup>14,15</sup> CNS tumors cannot disseminate via the lymphatic pathways while confined to the substance of the brain and spinal cord. However, once the covering membranes are

attained by tumor cells, a lymphatic permeation becomes possible. Blood vessels are rarely invaded by tumors of the brain or spinal cord. This observation has been attributed by some researchers to easy compressibility of the poorly supported, thin-walled blood vessels. In essence, it is postulated that the enlarging, concentrically expanding tumor flattens and effectively obliterates the lumens of the vessels in the normal adjoining periphery, so as to invade a patent channel. This mechanical concept is given some credence when one considers that the primary neoplasm, in many cases of tumors of the CNS with remote metastases, has been found to lie in close apposition to one of the large dural sinuses and to have actually penetrated the lumen. Further, one of the tumors frequently implicated in the production of remote metastases in adults is the glioblastoma multiforme, known for its tendency to proliferate and infiltrate into other areas of the body. Thus, this tumor is perhaps less prone than other more spherical, solid tumors to compress the blood vessels. Finally, it is clear that remote metastases often arise in tumors originating near or within the dura and pia arachnoid. These tumors grow in a richly vascular zone, well equipped with lymphatics.<sup>15-17</sup> Anzil's observation<sup>17</sup> that spontaneous metastasis of primary CNS neoplasms may spread through the venous system, after having gained entrance into it either at the dural or intracerebral level, appears to be applicable to the case reported herein.

In 1955 Weiss<sup>5</sup> established four rigid criteria for the diagnosis of extracranial metastasis from primary CNS lesions. These included the presence of a single histologically characteristic CNS tumor, a clinical history indicating a primary CNS lesion, the carrying out of a complete postmortem examination to exclude the possibility of peripheral primary lesions, and there being similar histologic findings between the CNS and peripheral lesions. Our patient fulfilled these criteria with the exception of the autopsy. Our patient had a long history of headache and seizure attacks, histologic findings typical of an anaplastic oligodendroglioma, and consistent histologic findings in both the CNS and spinal epidural lesions, all of which attested to the tumors having a common origin in the CNS.

Surgery appears to break down the barrier to metastasis.<sup>6,7,17</sup> Thus, it is supposed that vascular channels are opened and become accessible to tumor cells as a result of surgery. The tumor cells gain access to meningeal surfaces by seeding or by reparative ingrowth of the membranes. It is also possible that the proliferation of capillaries as part of the reparative process provides the access for metastatic cells. Another possibility is that the vessels in the glial scar tissue are less readily compressed than those of the parent tumor bed itself. They are thus more likely to remain patent, while being infiltrated by a recurrent tumor, thereby providing portals for metastatic dissemination. Abbott and Love<sup>16</sup> have also proposed that the negative pressure in the lumen of the cerebral veins, induced by craniotomy, could cause suction of tumoral cells.

Zimmerman<sup>15</sup> reported that an inadequate or incomplete dose of roentgen radiation had the effect of stimulating the growth of the animal experimental glioma. On the other hand, one of the prominent effects observed, when conducting radiotherapy in experimental animals, is a decrease in the number and caliber of vessels within tumors and their beds.<sup>18</sup> Both surgery and radiation therapy have been implicated in encouraging metastasis.<sup>19</sup>

The time interval between the primary diagnosis at surgery and the appearance of the distant metastasis varies from months to years.<sup>13</sup> Most, however, occur within one to two years. In our case, the spinal epidural metastasis occurred 10 years after the biopsy.

The positivity against GFAP, in both the CNS and epidural specimens, further substantiated the conclusion that the tumor was of CNS origin, with peripheral metastasis. This method of premortem identification of a peripheral metastasis was previously described by Yung and his co-workers.<sup>20</sup> They concluded that such positive findings were indicative of CNS origin, whereas a negative result did not necessarily rule this out. In our case, the positive histologic findings, in addition to the fact that three of the four criteria were met, allowed for the identification of extracranial metastasis of CNS origin, even without an autopsy being performed. It seems that, in this patient, the metastasis occurred via the blood

stream, since neither local tissue metastasis nor lymph node enlargement were observed.

In spite of recent progress in the field of cancer immunology, which has helped to clarify the immunological reactions to glioma and the role of immunological factors in metastasis formation, further studies are required before their mechanisms are fully understood.

## REFERENCES

1. Duffner PK, Cohen ME. Extraneural metastasis in childhood brain tumors. *Ann Neurol* 1981;10:261-5.
2. Hoffman HJ, Duffner PK. Extraneural metastasis of central nervous system tumors. *Cancer* 1985;56:1778-82.
3. Liwnicz BH, Rubinstein LJ. The pathways of extraneural spread in metastasizing gliomas: a report of three cases and critical review of the literature. *Hum Pathol* 1979;10:453-67.
4. Pasquier B, Pasquier D, Ngolet A, Panh MH, Couder P. Extraneural metastases of astrocytoma and glioblastomas: clinicopathological study of two cases and review of literature. *Cancer* 1980;45:112-25.
5. Weiss L. A metastasizing ependymoma of the cauda equina. *Cancer* 1955;8:161-71.
6. Smith DR, Hardman JM, Earle KM. Metastasizing neuroectodermal tumors of the central nervous system. *J Neurosurg* 1969;31:50-8.
7. Rubinstein LJ. Extracranial metastases in cerebellar medulloblastoma. *J Pathol Bacteriol* 1959;78:187-95.
8. Davis L. Spongioblastoma multiforme of the brain. *Ann Surg* 1928;87:8-14.
9. Rubinstein LJ. Development of extracranial metastases from a malignant astrocytoma in the absence of previous craniotomy. *J Neurosurg* 1967;26:542-7.
10. Dawson TP. Pancytopenia from a disseminated anaplastic oligodendro glioma. *Neuropathol Appl Neurobiol* 1997;23:516-20.
11. Ordóñez NG, Ayala AG, Leavens ME. Extracranial metastasis of oligodendro-glioma: report of a case and review of the literature. *Neurosurgery* 1981;8:391-6.
12. Roberts M, German WJ. A long-term study of patients with oligodendroglioma. *Acta Neurochir (Wien)* 1976;35:247-59.
13. Gyepes MT, D'Angio J. Extracranial metastasis from central nervous system tumors in children and adolescents. *Radiology* 1966;87:55-63.
14. Winkelman NW, Jr. Cassell C, Achlesinger B. Intracranial tumors with extra-cranial metastasis. *J Neuropathol Exp Neurol* 1952;11:149-68.
15. Zimmerman HM. In explanation of certain glioma problems. *J Mt. Sinai Hosp., New York* 1957;24:1357-62.
16. Abbott KH, Love JG. Metastasizing intracranial tumors. *Ann Surg* 1943;118:343-52.
17. Anzil AP. Glioblastoma multiforme with extracranial metastasis in the absence of previous craniotomy. Case report. *J Neurosurg* 1970;33:88-94.
18. McAlister WH, Margulis AM. Angiography of malignant tumors in mice following irradiation. *Radiology* 1963;81:664-74.
19. Parkinson D, Ross RT, Shields CB. Metastatic medulloblastoma. *Can J Neurol Sci* 1974;1:253-4.
20. Yung WK, Tepper SJ, Young DF. Diffuse bone marrow metastases by glioblastoma: premortem diagnosis by peroxidase-antiperoxidase staining for glial fibrillary acidic protein. *Ann Neurol* 1983;14:581-5.