

## A Case of Pulmonary *Microsporidiasis* in an Acute Myeloblastic Leukemia (AML) - M3 Patient

Süleyman Yazar<sup>1</sup>, Bülent Eser<sup>2</sup>, Şaban Yalçın<sup>1</sup>, İzzet Şahin<sup>1</sup>, and A. Nedret Koç<sup>3</sup>

Departments of <sup>1</sup>Parasitology, <sup>2</sup>Haematology, <sup>3</sup>Microbiology, Erciyes University, Medical Faculty, Kayseri-Turkey.

Reported here is a case of microsporidiasis that occurred in an acute myeloblastic leukemia (AML)-M3 patient who underwent chemotherapy. Fever, cough, expectorate and dyspnea were observed during the therapy. Since this case was considered as adult respiratory distress syndrome due to the chest X-ray and arterial blood gas findings, the male patient was bounded to a mechanical ventilator. As coagulation tests showed compatible findings with disseminate intravascular coagulation (DIC), it was thought to be a case of sepsis originating from the lungs and DIC. *Pseudomonas aeruginosa* and *Staphylococcus aureus* were found in the sputum of the patient. Although he was given combined antibiotic therapy, there was no reduction in the fever. A bronchoalveolar lavage (BAL) sample was taken and *Microsporidia* sp. was found upon staining with Giemsa. The patient died due to sepsis and DIC just before receiving therapy for microsporidiasis. Pulmonary infection with *Microsporidia*, although classically occurring in patients with HIV infection, may occur rarely in leukemia patients, especially if previously treated with systemic immune suppression. This case reinforces the need to consider *Microsporidia* as a possible pathogen in immunocompromised patients with pulmonary infections.

**Key Words:** *Microsporidia*, immunosuppression, leukemia

### INTRODUCTION

*Microsporidia* are small, oval, obligate intracellular, eukaryotic, protozoan parasites that belong to the phylum Microspora. Microsporidiosis has been recognized in both vertebrates and inverte-

brates. More than 1000 species have been classified into approximately 100 genera, and at least 13 species have been reported to infect mammals.<sup>1,4</sup> Phylogenetically, the *Microsporidia* are early eukaryotic organisms because they have a true nucleus, possess prokaryote-like ribosomes and lack mitochondria.<sup>3</sup> Five genera (*Enterocytozoon* species, *Septata* species, *Pleistophora* species, *Encephalitozoon* species and *Nosema* species) as well as unclassified *Microsporidia* (collectively referred to as *Microsporidium*) have been associated with human diseases occurring mostly in immunocompromised patients.<sup>1,4</sup> The affected patients may exhibit broad clinical manifestations including intestinal, pulmonary, ocular, muscular and renal disease. We report herein a case of pulmonary microsporidiasis in an acute myeloblastic leukemia (AML)-M3 immunocompromised patient.

### CASE REPORT

In October 2000, a 48 year-old male visited a dentist because of gum bleeding, and although he received medication the complaints continued, followed by the onset of weakness and fatigue. Two months later, after collapsing due to dizziness and losing conscious for a while, he applied to the emergency service of our hospital. Biochemical and haematological findings were as follows: Hb, 7.9 g/dl; leucocytes,  $1.5 \times 10^9$ /L; thrombocytes,  $16 \times 10^9$ /L; blood glucose, 96 mg/dl; BUN, 13 mg/dl; creatinine, 0.7 mg/dl; uric acid, 13 mg/dl; AST, 12 U/L; ALT, 12 U/L; LDH, 507 U/L; total bilirubin, 2.8 mg/dl; and indirect bilirubin, 2.2 mg/dl. In peripheric smear test, leu-

Received April 23, 2002

Accepted June 5, 2002

Reprint address: requests to Dr. Süleyman Yazar, Department of Parasitology, Erciyes University Medical Faculty, Kayseri-Turkey. Tel: 90-352-4374937/23401, Fax: 90-352-4375285, E-mail: syazar@erciyes.edu.tr

cocytes consisted of 70% promyelocytes and 20% blastic cells. The patient was transferred to haematology service.

At the end of the examinations, this case was diagnosed as AML-M3. Treatment of cytosine arabinoside 20/mg/day/sc and ATRA 30mg/day/ oral was commenced immediately, continuing for 12 days. Red blood cell and platelet counts were monitored daily but no recovering was evident.

We decided to apply PETHAMA protocol (idarubicin 12 mg/m<sup>2</sup>/I.V., on the 2<sup>nd</sup>, 4<sup>th</sup>, 6<sup>th</sup> and 8<sup>th</sup> days; ATRA 45 mg/m<sup>2</sup>/day/oral constantly). Fever (38°C), cough, expectorate, and dyspnea began within two weeks. On physical examination, there were widespread crepitan ralls in both lungs and on PA chest X-ray disseminated, bilateral, reticulonodular appearance was determined. The patient was neutropenic; meropenem 3 × 1 g and TMP-SMX 160/800 mg. Administration of 3 × 2 was started after sputum, blood and urine cultures, ATRA treatment was stopped, and dexamethasone 3 × 8 mg/IV and furosemid 2 × 20 mg/IV were applied. On the 4th day of antibiotic therapy, a daily dose of amphotericin B 50 was also added to the regime in the absence of any reduction in the findings of the lungs.

In the later chest X-ray, the opacity, which began from the bilateral hilar regions and extended to the peripheral region, was observed in conjunction with hypoxia in the arterial blood gas in spite of 2 L/min nasal oxygen. The patient's breathing distress increased. On the basis of these symptoms, a diagnosis of adult respiratory distress syndrome was made and the patient was bounded to a mechanical ventilator. In the coagulation tests, there was an increase in aPTT, INR, and D-Dimer, and a decrease in fibrinogen values. We considered it to be a case of sepsis originating from the lungs and disseminated intravascular coagulation (DIC). Since we found meropenem resistant, ceftazidime and amikacine sensitive *Pseudomonas aeruginosa*, and methicillin resistant *Staphylococcus aureus*, in the sputum of the patient, the meropenem treatment was replaced by ceftazidime 3 × 2 g/day/IV, amikacine 1 × 1 g/day/IV and Vancomycin 4 × 500 mg/day/IV. There was no decline in the patient's fever, and a bronchoalveolar lavage (BAL) sample

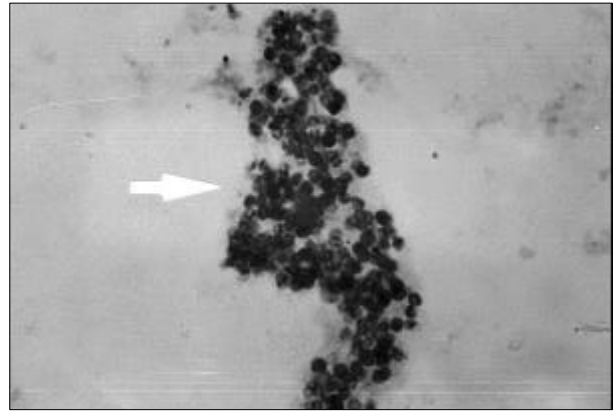


Fig. 1. Spores of *Microsporidia* in the bronchoalveolar lavage sample of a patient with AML-M3 (Giemsa stain; magnification × 1000).

was taken for parasitological examination which revealed *Microsporidia* sp. upon staining with Giemsa (Fig. 1). The patient died due to sepsis and DIC just before the introduction of therapy for microsporidiasis. We could not identify the species of *microsporidia* by electron microscope because we could not take another new BAL specimen.

## DISCUSSION

We report a rare case of pulmonary microsporidiasis, confirmed by Giemsa staining of BAL sample, that occurred in an AML-M3 patient. *Microsporidia*, well recognized as opportunistic pathogens, have been described classically to cause infections in the growing population of patients with AIDS. Such infections among persons without AIDS are rare. Weber et al. reported in their review on human microsporidial infections that as of 1994, only 10 cases of microsporidial infections had been described among persons not infected with HIV.<sup>4,5</sup> To our knowledge, this is the first reported case of pulmonary microsporidiosis in an AML-M3 patient without HIV infection.

The typical size of *Microsporidia* that has been recognised in a variety of animals ranges from 1.5 to 5 µm in width and 2 to 7 µm in length. Unfortunately, the organisms found in humans tend to be quite small, ranging from 1.5 to 2 µm

long. Until recently, awareness and understanding of human infections have been marginal, and it is only with increased understanding of AIDS within the immunosuppressed population that attention has been focused on these organisms.<sup>6</sup>

The organism has been isolated using special tissue culture techniques, which are available only in a few specialized laboratories, making this method impractical for routine diagnosis.<sup>7</sup> Tissue examination by electron microscopy (EM) techniques is still considered to be the best approach; however this option is not available to all laboratories. Hence, with the introduction of newer diagnostic methods, the ability to identify these parasites has definitely improved. The organisms are characterised by having spores containing a polar tubule, which is an extrusion mechanism for injecting the infective spore contents into host cells. Spores can occasionally be seen very well by using the periodic acid Schiff (PAS) stain, silver stain or acid-fast stain. The spores are acid fast variable. Techniques that do not require tissue embedding are now becoming more popular. Touch preparations of fresh biopsy material that are dried, methanol fixed, and Giemsa stained have been used; however, screening must be performed at  $\times 1000$  magnification.<sup>6</sup>

The source of infection for humans and the routes of transmission are unknown; however, they are thought to be orofecal, resulting from direct inoculation, or occurring after trauma.<sup>8</sup> Direct inoculation may occur with close contact with domestic animals such as cats and birds; it may also spread from other infected persons.<sup>9-12</sup> The presence of infective spores in human clinical specimens suggest that precautions when handling body fluids and personal hygiene measures such as hand washing may be important in preventing primary infections in the health care setting. However, comprehensive guidelines for disease prevention will require more definitive information regarding sources of infection and modes of transmission.

Microsporidiasis occurs worldwide, and is exacerbated by immunosuppression.<sup>13,14</sup> Our patient had been diagnosed as AML-M3 and he was receiving immunocompromise therapy including

antineoplastic and steroid. The immunosuppression from the use of these drugs may have predisposed him to a super infection from *Microsporidia*.

In conclusion, this case reinforces the need to consider *Microsporidia* as a possible pathogen in immunocompromised patients with pulmonary infections. When more sensitive diagnostic techniques are developed we may find that this infection is not uncommon in the immunocompromised host.

## REFERENCES

1. Shadduck JA, Greely E. *Microsporidia* and human infections. Clin Microbiol Rev 1989;2:158-65.
2. Shadduck JA. Human microsporidiosis and AIDS. Rev Infect Dis 1989;11:203-7.
3. Didier ES, Snowden KF, Shadduck JA. Biology of microsporidian species infecting mammals (revive). Adv Parasitol 1998;40:283-320.
4. Weber R, Bryan RT, Schwartz DA, Owen RL. Human microsporidiosis infections. Clin Microbiol Rev 1994;7: 426-61.
5. Theng J, Chan C, Ling ML, Tan D. Microsporidial keratoconjunctivitis in a healthy contact lens wearer without HIV infection. Ophthalmology 2000;108:976-8.
6. Garcia SL, Bruckner AD. Intestinal protozoa (Coccidia and Microsporida) and Algae in Diagnostic Medical Parasitology. 3rd ed. Washington, D.C: American Society for Microbiology; 1997. p.54-89.
7. Didier ES, Didier PJ, Friedberg DN, Stenson SM, Orenstein JM, Yee RW, et al. Isolation and characterization of a new human microsporidian, *Encephalitozoon hellum* (n.sp.) from three AIDS patients with keratoconjunctivitis. J Infect Dis 1991;163:617-21.
8. Ashton N, Wirasinha PA. Encephalitozoonosis (nematosis) of the cornea. Br J Ophthalmol 1973;57:669-74.
9. Botha WS, vanDellen AF, Stewart CG. Canine Encephalitozoonosis in South Africa. J S Afr Vet Assoc 1979; 50:135-44.
10. Gannon J. A survey of *Encephalitozoon cuniculi* in laboratory animal colonies in United Kingdom. Lab Anim 1980;14:91-4.
11. Shadduck JA, Meccoli RA, Davis R, Font RL. Isolation of a microsporidian from a human patient. J Infect Dis 1990;162:773-6.
12. Schwartz DA, Bryan RT, Visvesvara GS. Diagnostic approaches for encephalitozoon infections in patients with AIDS (revive). J Eukaryot Microbiol 1994;41:59-60.
13. Bretagne S, Foulet F, Alkassoun W, Fleury-Feith J, Develougs M. Prevalence of enterocytozoon bienersi spores in the stool of AIDS patients and African

children not infected by HIV. Bulletin de la Societe de Pathologie Exotique 1993;86:351-7.

14. Enríguez FJ, Taren D, Cruz-Lopez A, Muramoto M,

Palting JD, Cruz P. Prevalence of intestinal encephalitozoonosis in Mexico. Clin Infect Dis 1998;26:1227-9.