

## Piriformis Syndrome —A case report—

Hui Wan Park, Jun Seop Jahng and Woo Hyeong Lee

*Piriformis syndrome, a term applied to an abnormal condition of the piriformis muscle, is characterized by symptoms and signs due to sciatic nerve entrapment at the greater sciatic notch. Recently we reviewed a case of unusual low back pain, radiating to the left lower extremity with tenderness particular in the left buttock. The patient was successfully treated by sectioning the piriformis tendon. We described the clinical features of a case of piriformis syndrome and reviewed the foreign literature.*

**Key Words:** Piriformis syndrome

In 1928 Yeoman reported the first case relating the piriformis muscle to sciatic pain. The piriformis muscle syndrome has been described as an abnormal condition of the piriformis muscle characterized by signs and symptoms due to sciatic nerve entrapment at the greater sciatic notch (Solheim 1981).

The etiology of this syndrome is thought to be an injury of the piriformis muscle resulting in spasm, edema, and contracture of the muscle and subsequent compression and entrapment of the sciatic nerve (Julsrud 1989).

Solheim (1981) reported excellent results in two patients, Brown (1988) in one patient and Julsrud (1989) in one patient, all treated by sectioning the piriformis muscle.

This report presents one patient treated by division of the piriformis tendon. This procedure may relieve pressure on the structure that accompanies the piriformis muscle through the greater sciatic notch.

### CASE REPORT

A 62-year-old male farmer presented with a his-

tory of blunt trauma of the left buttock caused 18 months earlier by the fender of a motorcycle. During the 18 months prior to admission, he suffered persistent, radiating pain extending from the sacrum to the left buttock/hip and the dorsolateral aspect of the thigh. There was paresthesia and a burning sensation on the skin in the same region. He limped on his left side and complained of severe tenderness of the left buttock. He had shown only transitory improvement with physiotherapy as well as several series of acupuncture in the lower back involving the left buttock and herb medication.

On examination he had persistent external rotation of the left leg, slight atrophy of the left gluteal muscles and a positive straight leg raising test with Lasegue's sign on the affected side. Distinct tenderness over the piriformis muscle was elicited. Frieberg's sign was positive, and combined adduction-flexion-internal rotation of his left hip produced pain. There was an excellent range of motion of the lumbar spine and no tenderness. The lumbo-sacral and pelvic skeletal roentgenogram showed degenerative change and sciatic scoliosis of the lumbar spine (Fig. 1).

An operation was performed with the patient in the prone position. An oblique incision was made from the greater sciatic notch to the greater trochanter. The fibers of the gluteus maximus were separated by blunt dissection, and the left piriformis tendon was sectioned at its tendinous insertion site.

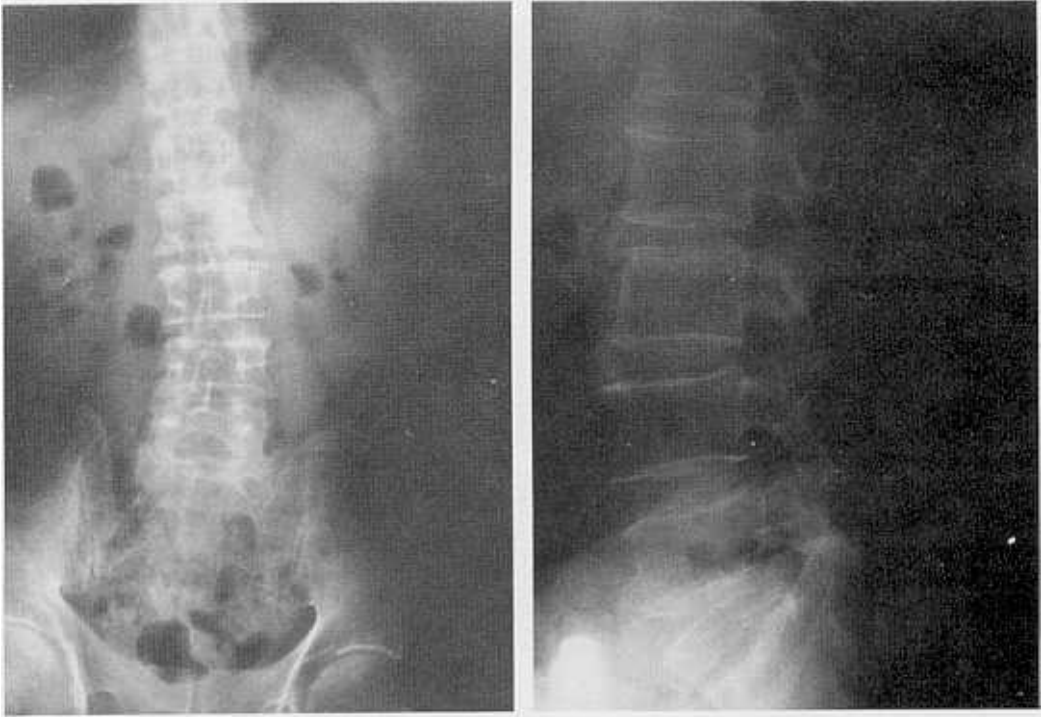
Light hypertrophied fasciae of the piriformis muscle and adhesions between the sciatic nerve and

Received June 26, 1990

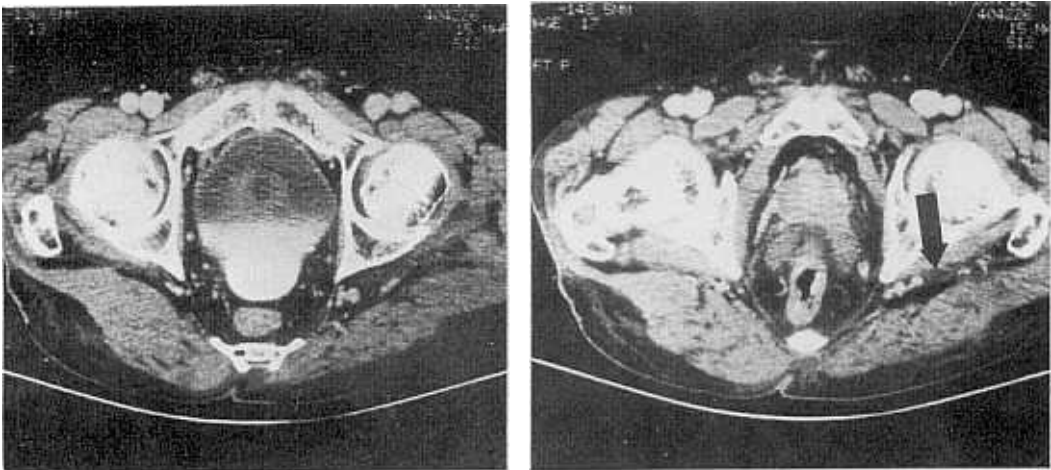
Accepted September 19, 1990

Department of Orthopedic Surgery, Yonsei University College of Medicine, Seoul Korea.

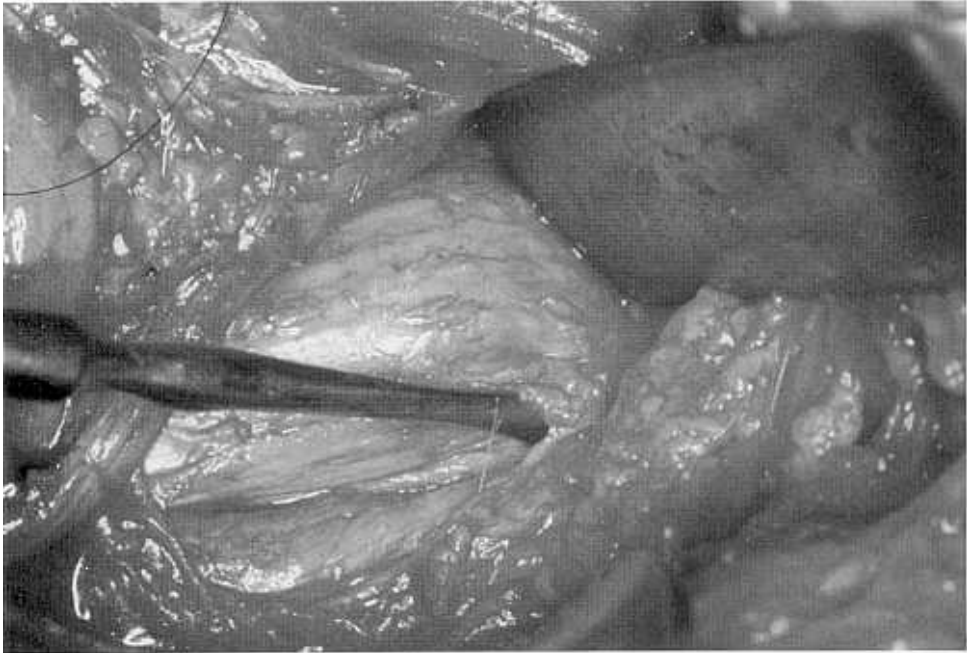
Address reprint requests to Dr. H W Park, Department of Orthopedic Surgery, Yonsei University College of Medicine, C.P.O. Box 8044, Seoul, Korea, 120-752



**Fig. 1.** Plain X-rays of 62-year-old male for lumbar spine with A-P and lateral projection show the degenerative change and spondylosis of lumbar spine.



**Fig. 2.** Computed tomography of the gluteal region shows atrophied gluteus muscles and the hypertrophied sciatic nerve (arrow) in the left compared to the right.



**Fig. 3.** Photograph of the operating field shows hypertrophied fasciae of the piriformis muscle and adhesions between the sciatic nerve and the piriformis muscle and surroundings.

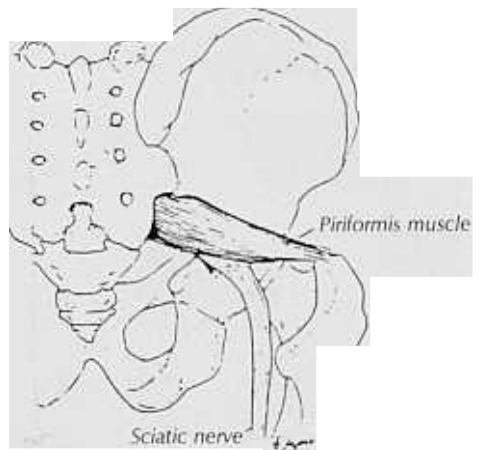
the piriformis muscle and surroundings were noted and loosened (Fig. 2, 3).

Complete relief was obtained immediately after the operation.

## DISCUSSION

Entrapment of the proximal sciatic nerve occurs infrequently, but the piriformis syndrome is caused by peripheral entrapment of the sciatic nerve.

Yeoman (1928) was the first to refer to piriformis muscle's relationship to sciatic pain. The piriformis (Fig. 4) is the abductor and external rotator of the hip and is a flexor of the hip in the walking. It arises from the pedicles of the second, third and fourth sacral vertebrae and adjacent portion of the bone lateral to the sacral foramina. The muscle passes the greater sciatic foramen, and coursing laterally, is inserted by a rounded tendon into the superior border of the greater trochanter. It is, therefore, in contact with the anterior ligament of the sacroiliac joint and the root of the first, second and third sacral nerves. Its lower border is closely related to the whole trunk of the sciatic nerve (Clements 1985).



**Fig. 4.** Line drawing shows the relationship of the sciatic nerve to the piriformis muscle (redrawn from Brown JA, Braun MA, Namey TC: Piriformis Syndrome in a 10-year-old boy as a complication of operation with the patient in sitting position. *Neurosurgery* 23; 117-119, 1988).

Yeoman (1928) stated that any lesion of the sacroiliac joint may cause inflammatory reaction of the piriformis muscle and its fascia.

The term, piriformis syndrome, is applied to that type of sciatica which is due to an abnormal condition of the piriformis muscle, and which is usually traumatic in origin. Other pathologic conditions of the lumbar, sacral and hip joint area should be ruled out by examination and X-ray (Robinson 1947).

Two mechanisms have been proposed to explain the cause of the piriformis syndrome. The classic explanation was Robinson's in 1947. He noted that the sciatic nerve exits from the pelvis beneath the piriformis muscle. If the piriformis muscle and fascia become inflamed, usually from trauma, the sciatic nerve can become compressed between the swollen muscle fiber and the bony pelvis, leading to an entrapment neuropathy. Robinson found that the piriformis muscle was stretched after a few degrees of leg raising; so that, with muscular spasm or inflammation, the sciatic nerve may be directly compressed by the piriformis muscle. An alternative explanation was proposed by Pecina (1979). He found that the sciatic nerve passed between the muscular fibers of the piriformis muscle in 21% of 130 cadavers. Even when contracted, however, muscle fibers could not exert enough pressure on the nerve to cause neuropathy. It was in only 15% of the ca-

davers, when the nerve passed through the tendinous portion of the muscle, that the nerve could be compressed during internal rotation of the thigh. On external rotation of the thigh, the nerve was free of compression by the tendon.

The cause of the piriformis syndrome in our case was thought to be the blunt trauma of the piriformis muscle 18 months previously by the fender of the motorcycle. This resulted in spasm, edema, and contracture of the piriformis muscle and its fascia, adhesions between the sciatic nerve and the piriformis muscle and surrounding, and subsequent compression and entrapment of the sciatic nerve.

The diagnosis of piriformis syndrome is entirely clinical. The cardinal feature of piriformis syndrome are as follows; (1) a history of trauma to the sacroiliac and gluteal region; (2) pain in the region of the sacroiliac joint, greater sciatic notch and piriformis muscle, extending down the leg and causing difficulty in walking; (3) acute exacerbation of chronic pain brought on usually by stooping or lifting, which can be greatly relieved by traction of the affected leg; (4) the presence of a palpable sausage-shaped mass over the piriformis muscle during acute exacerbation of the pain and tenderness to pressure, is almost a pathognomic sign; (5) a positive Lasague's sign; (6) gluteal atrophy may be present depending on the duration of the condition (Robinson 1947); (7) pain and weakness on resisted

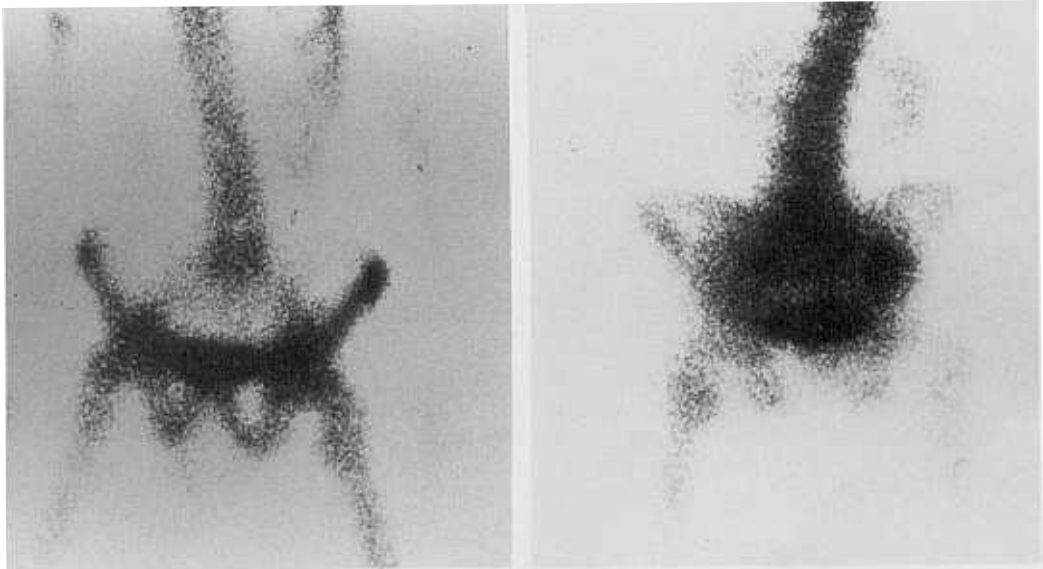


Fig. 5. Posterior and anterior scans show no abnormal uptake in the gluteal region.

abduction-external rotation of the thigh; (8) pain on forced internal rotation of the extended thigh (positive Frieberg's sign). Thiele (1937) reported that this maneuver tightens the piriformis muscle and causes pressure on the sciatic nerve at the sacrospinous ligament. And (9) diagnostic injection of local anesthetics or cortisone in the piriformis muscle relieves the pain (Solheim 1981).

Scintigraphic visualization of damaged muscle was started in 1974 and has been described frequently since then. Karl et al. (1985) stated, "the previous emphasis on the diagnosis of piriformis syndrome by clinical criteria had led to the underutilization of nuclear medicine scanning with bone seeking agents. The pattern of abnormal uptake in the piriformis muscle on a nuclear medicine bone scan is diagnostic and, when recognized, will lead to the correct diagnosis, eliminating the need for further diagnostic testings."

But our scanning with Tc-99m revealed nothing. This was thought to be due to the delay of 18 months in our case. Karl et al. had a delay of only 3 days (Fig. 5).

Thiele (1937) reported treatment of this syndrome by transrectal massage of the piriformis muscle. Reports of successful surgical treatment (Robinson 1947; Solheim 1981; Brown 1988; Jul-srud 1989) encourage us to section the piriformis tendon. The functional loss is minimal, since this muscle is the fourth strongest of the short external rotators of the hip (Solheim 1981). The procedure

proved to be beneficial in our patient.

## REFERENCES

- Brown JA, Braun MA, Namey TC: Piriformis syndrome in a 10-year-old boy as a complication of operation with the patient in sitting position. *Neurosurgery* 23: 117-119, 1988
- Cameron HU, Noptal F: The piriformis syndrome. *The Canadian J Surgery* 31: 210, 1988
- Clemente CD: *Gray's Anatomy* 30th ed. Philadelphia, Lea and Febiger, 568, 1985
- Julsrud ME: Piriformis syndrome. *J Am Podiatr Med Asso* 79: 128-131, 1989
- Karl RD, Yedinak MA, Hartshorne MF, Cawthon MA, Bauman JM, Howard WH, Bunker SR: Scintigraphic appearance of the piriformis muscle syndrome. *Clin Nucl Med* 10: 361-363, 1985
- Pecina M: Contribution to the etiological explanation of the piriformis syndrome. *Acta Anat(Basel)* 105: 181-187, 1979
- Robinson DR: Piriformis syndrome in relation to sciatic pain. *Am J Surgery* 73: 355-358, 1947
- Solheim LF, Siewers P, Paus B: The piriformis muscle syndrome-Sciatic nerve entrapment treated with a section of the piriformis muscle. *Acta Orthop Scand* 52: 73-75, 1981
- Thiele GH: Coccygodynia and pain in the superior gluteal region. *J Am Med Asso* 109: 1171-1175, 1937
- Yeoman W: The relation of arthritis of the sacroiliac joint to sciatica. *Lancet* 2: 119, 1928