

Cystic Meningiomas in Infancy

Vivek Sharma and Goodwin Newton

A suprasellar meningioma with multiple intratumoral cysts in a 6-month-old boy is reported. A review of literature disclosed only 11 cases so far. They showed a characteristic predominance in males and predominance of fibroblastic type on pathological examination. Intratumoral cysts are less common than peritumoral cysts. The various hypothesis regarding cyst formation are discussed.

Key Words: Meningioma, infant, cyst, congenital tumor, cystic meningioma

Although meningiomas are usually solid and benign, they may be occasionally associated with cysts. They are rare in infancy and those associated with cysts are rarer still. There were only 20 histologically confirmed case reports of meningiomas within the first year of life in the world literature; and cysts were found in 11 of them (French 1959; Florin and Reid 1961; Taptas 1961; Mendiratta *et al.* 1975; Endo and Airhara 1978; Numaguchi *et al.* 1978; Dong *et al.* 1980; Amano *et al.* 1980; Katayama *et al.* 1986). Herz *et al.* (1980) and Sano *et al.* (1981) have pointed that there is significantly high incidence of cyst formation in infancy than in childhood, adolescence or adulthood. Here we describe another typical case in a six-month-old male child.

CASE REPORT

A six-month-old male infant was admitted with complaint of large head. He was born after full term pregnancy without any complication. At the age of 4 months her mother observed the bulging of the anterior fontanelle and enlargement of the head which was gradually increasing. All his milestones were delayed. He also had occasional vomiting.

There was no history of trauma and fever.

His head circumference was 49 cm. There were dilated veins on the scalp. The anterior fontanelle was bulging out. Sun setting sign was present. There was an abnormal sound over the head. Systemic examination was within the normal limit. Neurologically he had left pupillary dilatation. There was no vision in the left eye. Fundus examination showed bilateral primary optic atrophy, more marked on the left side. There was no motor weakness.

Computed tomography (CT) scan demonstrated a large suprasellar tumor with multiple well defined low attenuating areas in it (Fig. 1). The tumor extended more towards the left side. The solid portion of the lesion took significant enhancement after intravenous contrast administration. There was also ventricular dilatation. Carotid angiogram was not performed. The possibilities of craniopharyngioma, glioma of optic chiasm and cystic meningioma were kept in the diagnosis.

Following biventriculo-peritoneal shunt, bifrontal free flap craniotomy was done. Peroperative ultrasonographic pictures were taken which showed multiple intratumoral cysts inside the tumor mass (Fig. 2-A, B). Cysts were tapped and found containing xanthochromic fluid with 2000 mg/dl of protein, 46 mg/dl of sugar and no cell and cholesterol crystals. The tumor was firm, vascular and engulfed the left optic nerve. It was adherent to the underlying basal dura mater.

There was no infiltration to the cerebral cortex. Under operating microscope, total resection of the tumor was performed. The postoperative phase was

Received September 19, 1991

Accepted December 18, 1991.

Department of Neurosurgery, King George's Medical College, Lucknow, India.

Address reprint requests to Dr. V Sharma, Department of Neurosurgery, King George's Medical College, Lucknow, 226 003, India.

uneventful. He was discharged after ten days of hospital stay in the same neurological status.

Histopathological examination of the tumor had characteristic findings suggestive of fibroblastic meningioma (Fig. 3).

DISCUSSION

Infantile meningiomas with cysts have been reported episodically. The review of the literature revealed that among 21 cases, including our own

case, twelve (57%) were associated with cyst formation (Table 1) while in adults this frequency was in the range of 1.2 to 8% in various series. Meningiomas are known to have female predominance in general, but males are commonly affected in infantile variety (9 : 3). Eighteen of 21 cases (75 %) were confined at convexity. In one case each it was found at the tentorium, inside the brain substance and in the suprasellar region (Taptas 1961; Satyanarayana 1975). The tumor was adhered to the dura mater in 6 cases, however the firm adherence was observed in 3 of them (Florin and

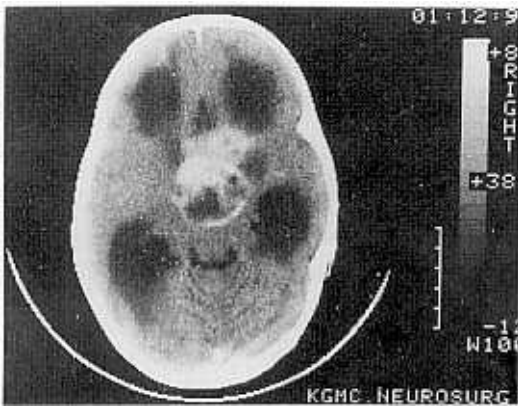


Fig. 1. CT scan head showing a suprasellar enhancing high attenuating lesion with multiple intratumoral cysts.

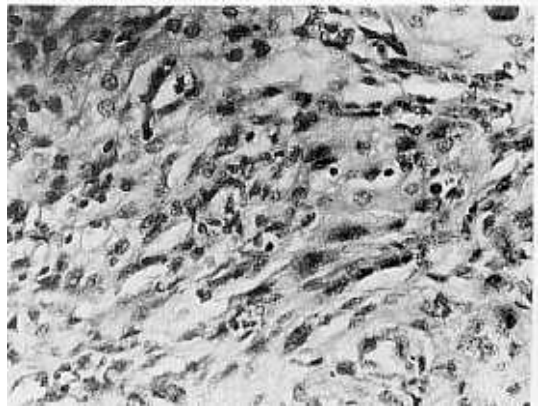


Fig. 3. Photomicrograph showing the tumor as fibroblastic meningioma (Hematoxylin and Eosin x 320).

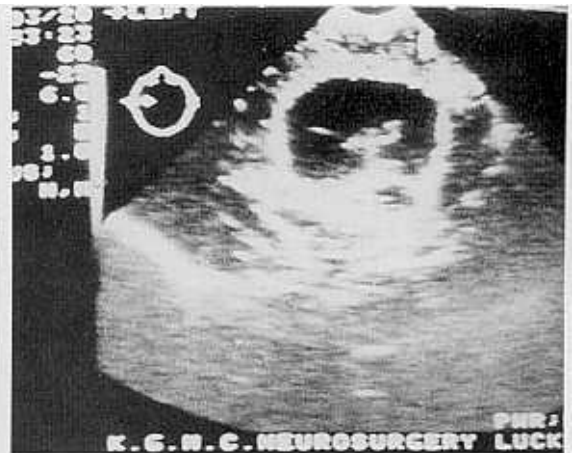
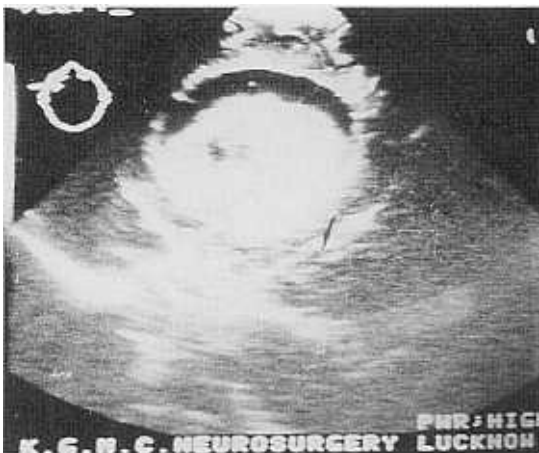
Fig. 2. Intraoperative ultrasonogram (A) anterior portion, (B) posterior portion showing well defined mass with multiple hypoechoic areas.

Table 1. Summary of cystic meningiomas in infancy

Case number	Author, year	Age, Sex	Location	Cyst size	Tumor Size	Pathology
1.	French, 1959	6 mo, F	FC	-	-	Sarcomatous
2.	Taptas, 1961	4 mo, M	TPC	-	5x3x1.5 cm	Fibroblastic
3.	Florin and Reid, 1961	at birth, M	TC	300 cc	3x3x5 cm	Angioblastic
4.	Mendiratta et al., 1967	6 mo, M	TC	-	golf ball	Meningothelial & fibroblastic
5.	Suematsu et al., 1974	5 mo, M	TPC	60 cc	5x5x7 cm	Fibroblastic
6.	Satyanarayana et al., 1975	6 mo, M	FP	Huge	3x2x1.5 cm	Fibroblastic
7.	Endo and Aihara, 1978	4 mo, F	Convexity	Small	Giant	Fibroblastic
8.	Numagachi et al., 1978	6 mo, M	FTC	large	5x7 cm	Fibroblastic
9.	Dong et al., 1980	6 mo, M	Convexity	-	-	Fibroblastic
10.	Amano et al., 1980	10 mo, M	TP	40 cc	6x5x1 cm	Fibroblastic
11.	Katayama et al., 1985	5 mo, F	FP	large	golf ball	Fibroblastic
12.	Sharma and Newton, 1991 (Present report)	6 mo, M	Suprasellar	100 cc	3x3x2 cm	Fibroblastic

Abbreviations: mo, month; F, female; M, male; PC, parietal convexity; TPC, temporoparietal convexity; FP, frontoparietal; FTC, frontotemporal convexity.

Reid 1961; Amano et al. 1980). It is an uncommon feature of convex meningioma of adulthood not to have dural attachment.

The cyst may lie inside or around the tumor. Nauta et al. (1979) classified the cysts into 4 types:

- (i). Type 1 An intratumoral cyst surrounded all around by macroscopic tumor.
- (ii). Type 2 A cyst still inside the tumor but part of its rim formed by microscopically visible tumor cells.
- (iii). Type 3 A peritumoral cyst within the adjacent brain rather than the tumor itself.
- (iv). Type 4 Loculated CSF in the subarachnoid space between the tumor and the brain neither inside the tumor nor in the brain.

Rengachari et al. (1979) broadly observed cysts of two kinds, intratumoral cysts and peritumoral cysts. Intratumoral cysts are extremely rare as they were detected in 3 out of 12 patients. The cyst wall may be composed of astroglial fibres, or collagen or fibroblastic tissue. In a fairly good number of cases, the cyst wall contained islands of neoplastic cells so Inoue et al. (1982) stressed that one should try to achieve complete resection of the cyst along with the nodule to prevent recurrence, although the total resection of the wall is not an easy task even under operating microscope.

Histopathological examination of the solid part revealed a fibroblastic type of meningioma in 10

out of 12 cases (84%), angioblastic (Florin and Reid 1961) and sarcomatous (French 1959) types in one each. Meningotheliomatous variety predominates in adulthood meningiomas.

Mechanism leading to cyst formation are still not well understood and many theories have been put forward. It is observed that no single theory explains all the aspects of peri or intratumoral cyst formation. Each process may cast a different radiological picture. The various possibilities in the formation of intratumoral cysts (Russell et al. 1980). ii). confluence of microcysts, iii). intratumoral hemorrhages, and less commonly iv). intratumoral metastases. According to Pinna et al. (1986), peritumoral cysts may be the final stage of peritumoral vasogenic edema with fluid collection around the tumor (Stevens et al. 1983). They may also result from loculation or dilatation of the subarachnoid space (Mendiratta et al. 1967; Sigel and Messina 1976).

Macrocephaly was the usual mode of presentation in 11 cases (92%). Other clinical symptoms were seizure in two and hemiparesis in one case. The increase in the circumference of the head was noted between 3 and 6 months after birth in 9 out of 12 cases (75%). There was only one case report when it was detected in a neonate soon after birth (Florin and Reid 1961). Amano et al. (1980) noted that congenital meningioma might have the potential of producing fluid to form a cyst. Whenever there is rapid increase in head size, it is most often

due to a cyst rather than a solid mural nodule.

CT scan offers the highest accuracy in the preoperative diagnosis though some cases may be diagnosed as cystic gliomas. In doubtful cases angiography, especially selective studies to see the enlarged or feeding vessels of the middle meningeal artery, proves beneficial. Final diagnosis rests upon operative and above all histological findings.

Thus we conclude that cysts in meningioma in the initial year of life are very uncommon that too if they are intratumoral. There is distinct difference between infancy and adulthood meningiomas. The authors case is exhibiting similar typical features but it had multiple cysts confined in the tumor itself.

REFERENCES

- Amano K, Miura N, Tajika Y et al.: Cystic meningioma in a 10-month-old infant: Case report. *J Neurosurg* 52: 829-833, 1980
- Dong H, Huang S, Huang C: Congenital meningioma. *Chir Med J (Engl)* 93: 159-163, 1980
- Endo S, Aihara H: Intracranial meningioma of the newborn: A case report. *No To Hattatsu* 10: 248-251, 1978
- Florin RE, Reid ND: Congenital angioblastic meningioma: Review of literature and report of a case. *Bull Los Angeles Neurol Soc* 26: 151-156, 1961
- French L: *Tumors-intracranial and cranial*. In Jackson JJ, Thompson RK, ed. *Pediatric neurosurgery*, Oxford, Blackwell Scientific, 1959, 224-350
- Herz DA, Shapiro K, Sulaman K: Intracranial meningiomas of infancy, childhood and adolescence, review of the literature and addition of 9 case reports. *Childs Brain* 7: 43-56, 1980
- Inoue M, Sakai S, Fukushima M et al.: Cystic meningioma associated with intratumoral hemorrhage in a child. *No Shinkei Geka* 10: 661-664, 1982
- Katayama Y, Tsubokawa T, Yoshida K: Cystic meningiomas in infancy. *Surg Neurol* 25: 43-48, 1986
- Mendiratta SS, Rosenblum JA, Strobos RJ: Congenital meningioma. *Neurology* 17: 914-918, 1967
- Nauta HJW, Tucker WS, Horsey WJ et al.: Xanthochromatic cysts associated with meningioma. *J Neurol Neurosurg Psychiatr* 42: 529-535, 1979
- Numaguchi Y, Hoffman JC, O'Brien MS et al.: Meningiomas in children and adolescence. *Neurol Med Chir (Tokyo)* 18: 119-127, 1978
- Pinna G, Beltramello A, Buffatti P et al.: Cystic meningiomas-An update. *Surg Neurol* 26: 441-452, 1986
- Rengachary S, Batnitsky S, Kepes JJ et al.: Cystic lesions associated with intracranial meningiomas. *Neurosurgery* 4: 107-114, 1979
- Russell EJ, George AE, Kricheff JJ et al.: Atypical computed tomographic features of intracranial meningiomas. Radiological-pathological correlation in a series of 131 consecutive cases. *Radiol* 135: 673-682, 1980
- Sano K, Wakai S, Ochiai C et al.: Characteristics of intracranial meningiomas in children. *Childs Brain* 8: 98-106, 1981
- Satyanarayana K, Chandy SM, Rao TS et al.: Congenital meningioma with subdural hygroma and porencephaly: A case report. *Neurol India* 23: 57-58, 1975
- Sigel RM, Messina AV: Computed Tomography: The anatomic basis of the zone of diminished density surrounding meningiomas. *Am J Roentgenol* 127: 139-141, 1976
- Stevens JM, Ruiz JS, Kendall BE: Observations on peritumoral edema in meningioma: Part I. Distribution, spread and resolution of vasogenic edema seen on computed tomography. *Neuroradiol* 25: 71-80, 1983
- Suematsu K, Tokuda S, Miyazaki Y: Intracranial meningioma in five-month-old infant: A case report and review of literature. *NoTo Shinkei* 26: 453-464, 1974
- Taptas JN: Intracranial meningioma in a four-month-old infant simulating subdural hematoma. *J Neurosurg* 18: 120-121, 1961