

## Effect of Sodium Hyaluronate on Prevention of Osteoarthritis

Nam Hyun Kim, Chang Dong Han,  
Hwan Mo Lee and Ick-Hwan Yang

*The changes in the surface of articular cartilage of femoral condyle from rabbits were evaluated after degenerative changes were made by the technique advocated by Hulth. The medial collateral and both cruciate ligaments were excised, and a medial menisectomy was done. Then the right knee joint was injected with 1ml of Na-hyaluronate gel every two weeks. The animals were sacrificed at two, four, six, eight, or sixteen weeks postoperatively. After sacrifice, the medial femoral condyle was excised and prepared for the light microscopic and scanning electron microscopic study. At eight to sixteen weeks, there were chondrocyte clones with clefts to the radial zone and increased loss of the height of articular cartilage on the control side; but, on the experimental side there was a significant delay and lessening of the arthritic response. The biocompatibility and the protective effect of joint degeneration of this device make this material a valuable adjuvant in the treatment of osteoarthritis and the traumatized joints.*

**Key Words :** Osteoarthritis, Prevention, Sodium hyaluronate

Interest in osteoarthritis is aroused by the increasing numbers of accidents in industry and traffic. Post-traumatic degenerative arthritis is a significant clinical problem. Moskowitz(1972) has summarized the entire range of techniques for obtaining experimental joint disease. One of these, developed by Hulth et al. (1970), is of particular interest in allowing study of degenerative joint disease because of its ability to produce severe osteoarthritis in rabbits.

On the other hand, the concept of a molecular, viscoelastic protective shield to restore joint homeostasis, to more evenly distribute forces across the joint surface, and to prevent direct contact of opposing solid articular cartilage in order to prevent or lessen the onset of the structural break down of

articular cartilage is very appealing.

Hyaluronic acid is one of the class of aminosugar-containing polysaccharides known as the glycosaminoglycans. Recently, a new family of chemically modified cross-linked hyaluronic acid molecules has been developed. The structural factors underlying the unique properties of hyaluronic acid are its high molecular weight and large molecular volume. The large molecular volume forces the overlap of individual hyaluronic acid molecular domains, resulting in extensive chain entanglement and chain-chain interaction.

The purpose of this study is to determine whether the prevention of the articular cartilage can be obtained by the injection of high molecular weight material into the joint space after initiation of degenerative joint disease using the method of Hulth et al. (1970) in rabbits.

### MATERIALS AND METHODS

Fifty New Zealand white adult rabbits with roentgenographically closed epiphyseal lines were used in this study. The rabbits had a weight range of 2.8-

Received January 29, 1991

Accepted March 29, 1991

Department of Orthopaedic Surgery, Yonsei University College of Medicine, Seoul, Korea

This study was supported by Research Grant(1990) of Asian Foundation

Address reprint requests to Dr. N.H. Kim, Department of Orthopaedic Surgery, Yonsei University College of Medicine, CPO Box 8044, Seoul, Korea, 120-752

3.8kg (mean 3.2kg). The rabbits were caged under identical conditions with a normal diet(Samyang Co.). Surgical procedures were conducted using aseptic techniques. Under intravenous nembutal anesthesia, the procedure was performed basically as outlined by Hulth et al. (1970). A medial parapatellar approach to the both knees was made displacing the patella laterally. The medial collateral ligament was excised; then the joint capsule was incised and excisions of the both cruciate ligaments and the medial meniscus were done so as not to damage the articular cartilage of the femur and the tibia.

After closure of the joint capsule, the right knee joint(experimental side) was injected with 1ml of Na-hyaluronate gel(Biochemistry Co., Japan) every two weeks; the left knee joint(control side) was not injected with anything. Animals were sacrificed with an overdose of intravenous nembutal at periods of two, four, six, eight, or sixteen weeks following surgery. Ten rabbits were sacrificed at each time period for the study.

### Histologic Techniques

Upon sacrifice, the distal part of the femur was immediately resected in toto and partially stripped of soft tissue. Eight condyles of femur in each group were fixed in 10% neutral formalin for at least three days. Decalcification was done with 5% formic acid for two weeks. Specimens were imbedded in paraffin, sectioned and stained with hematoxylin-eosin and alcian blue(pH 2.5).

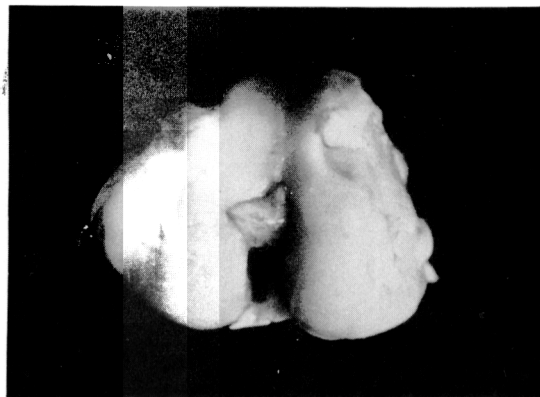
Two condyles of femur in each group were fixed in 25 glutaraldehyde in paraformaldehyde and 0.1M cacodylate solution, decalcified overnight in 4.13% EDTA, pH 7.4, and then fixed for an additional two hours in 1% sodium tetroxide. The samples were then rinsed in a buffer, dehydrated in a gradual ethanol series, then substituted by isoamyl acetate. Then the sample was dried with a critical point dryer(HCP-2, Hitachi, Japan), mounted on a metal stub, and coated with gold by 1B-3 ion coater (Eiko, Japan). After that we evaluated the specimens with a Hitachi S-450 scanning electron microscope.

## RESULTS

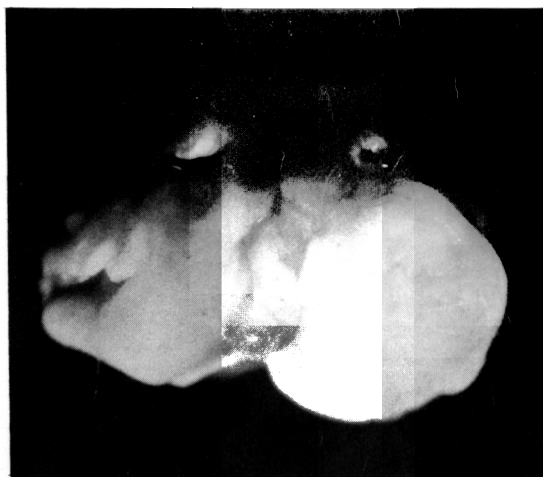### Gross findings

There was no definite difference in gross appearance between the two groups until six weeks after the operation. The articular cartilages in both

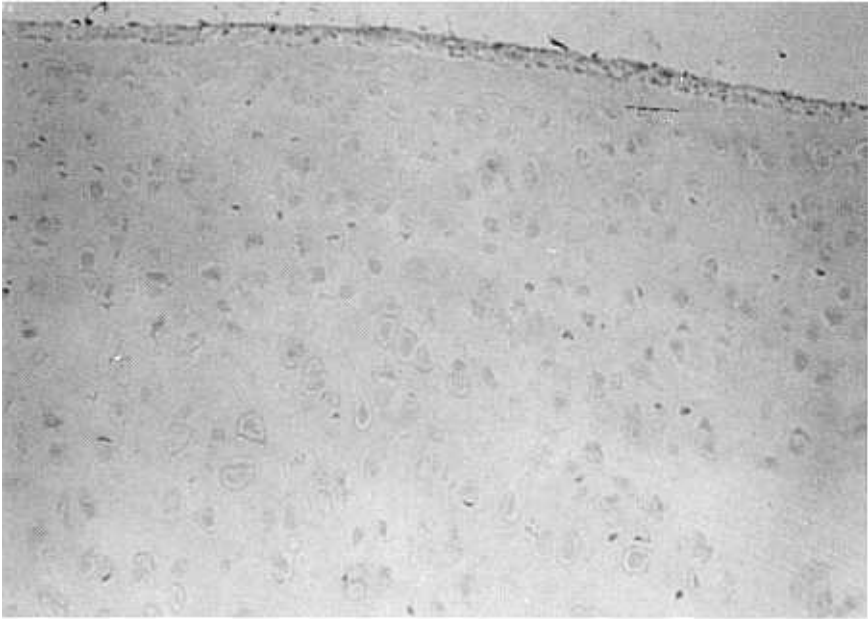
groups showed slight yellowish discoloration compared to normal hyaline cartilage. But there were no definite erosions or cracks in the surface of the cartilage. By eight weeks after the operation, the right side showed mid degenerative changes with yellowish discoloration, but the left side showed diffuse erosions and fibrous coverings around the margins of erosion; also, there were moderate osteophytes in the condyle. By sixteen weeks the differences were definite. In the experimental knee joint there were moderate erosions and decreased



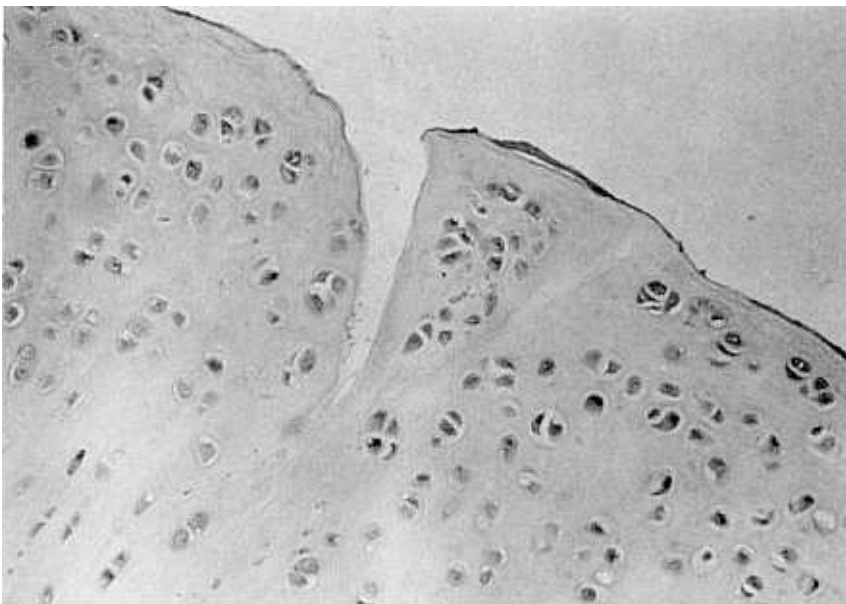
**Fig. 1-A.** Sixteen weeks after the operation in the experimental group. Mild changes in the color and a moderate degree of erosion were noted.



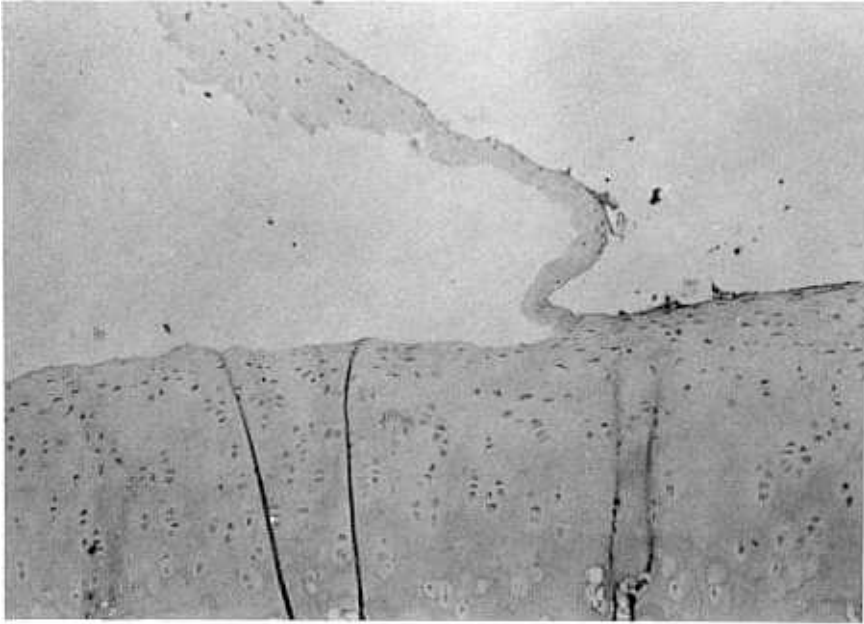
**Fig. 1-B.** Control side at sixteen weeks after the operation. Severe degenerative changes can be seen in the medial femoral condyle.



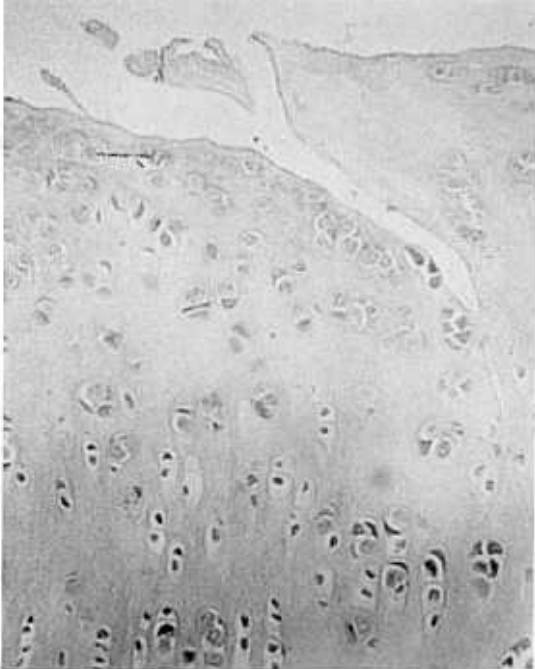
**Fig. 2.** Two weeks after the operation(control). Cell clusters in the superficial layer of the femoral knee joint cartilage are seen (H-E stain,  $\times 200$ ).



**Fig. 3.** Four weeks after the operation(control). Clefts to the transitional zone and moderate changes of degeneration are noted(H-E stain,  $\times 200$ ).



**Fig. 4.** Experimental side at six weeks after the operation. Flaking of the superficial layer and pyknosis of the chondrocytes are noted (H-E stain,  $\times 100$ ).



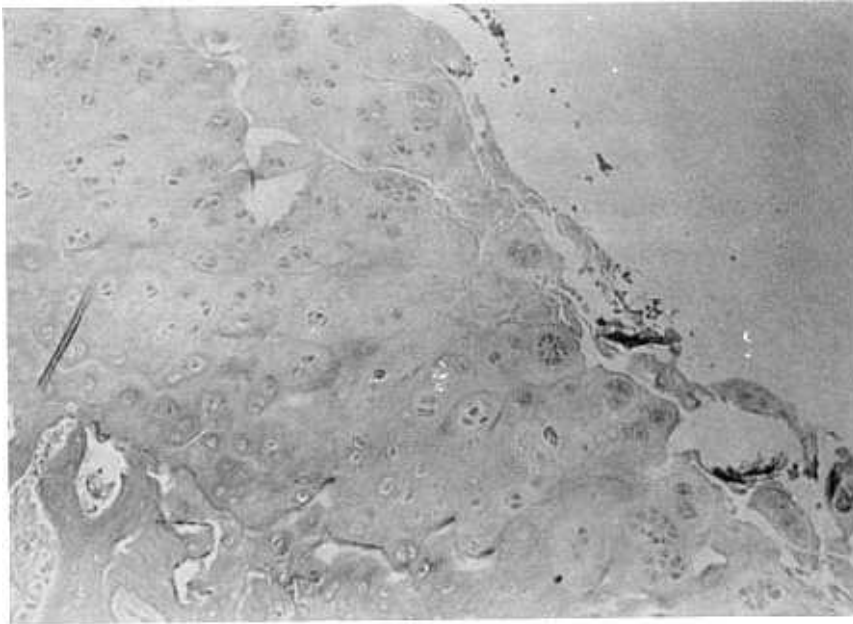
**Fig. 5-A.** Experimental side at eight weeks after the operation. There are mild cellular derangement and clefts to the transitional zone (H-E stain,  $\times 200$ ).

glistening, but in the control side the articular cartilage showed severe degenerative changes with loss of articular cartilage and exposure of subchondral bone with fibrous tissue(Fig. 1).


#### Microscopic Findings

A histologic evaluation was done according to the Mankin's grading (1970). In the left control knee joints, pathologic changes such as derangement of the cell arrangement and formation of cell clusters began to appear at two weeks after the operation. In the superficial layer of the cartilage of the medial femoral condyle in the right knee joints(Fig. 2), however, no pathologic changes were found at two weeks' observation. On the control side at four weeks after the operation, there were moderate changes of degenerative arthritis, hypercellularity of the tangential and transitional zone of articular cartilage, clefts to the transitional zone, chondrocyte clones, and increased synovial inflammation(Fig. 3) ; however, on the experimental side at four weeks' observation, there was only some pyknotic changes of the chondrocytes.

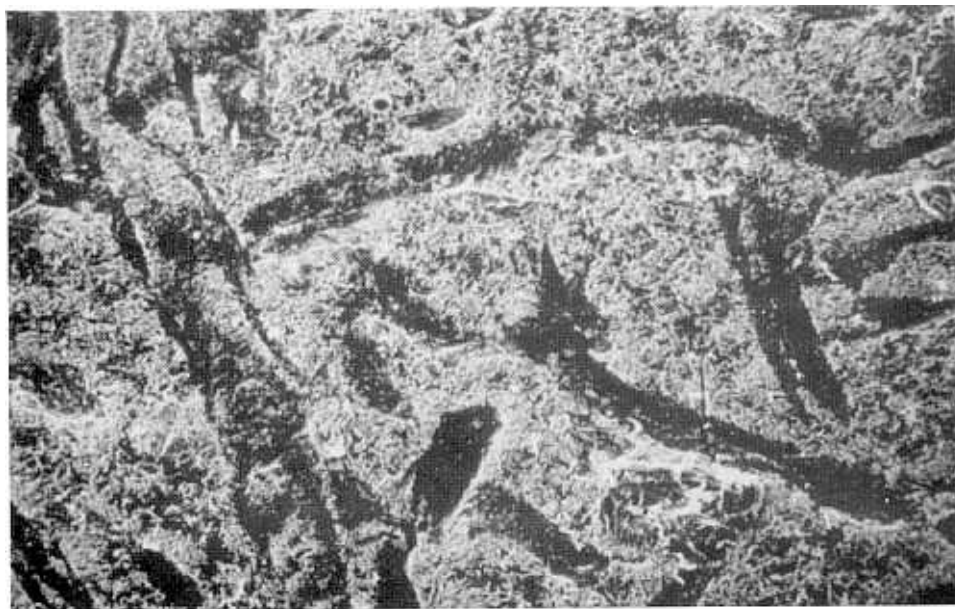At six weeks after the operation, there were chondrocyte clones with clefts to the mid-zone of articular cartilage and surface irregularities in the



**Fig. 5-B.** Control side at eight weeks after the operation. There are loss of height of articular cartilage, clefts to the radial zone, and loss of columnizaion of chondrocytes(H-E stain,  $\times 100$ ).



**Fig. 6-A.** Sixteen weeks after the operation in the right femoral condyle. Regular surface of the articular cartilage is observed in the scanning electron microscopic finding ( $\times 300$ ).



**Fig. 6-B.** Scanning electron microscopic finding of the left femoral condyle at sixteen weeks after the operation. Multiple deep clefts and more irregular surface of the articular cartilage are seen ( $\times 300$ ).

left knee joint chondrocyte and flaking of the superficial layer (Fig. 4). Eight weeks after the operation, more advanced degenerative changes were noted in the control side: i. e., loss of height of articular cartilage, clefts deep to the radial zone of articular cartilage, loss of columnization of cellular distribution, increased areas of hypocellularity, and cloning of chondrocytes. But, in the right side there were cracks to the transitional zone and mild derangement of the cellular arrangement (Fig. 5). At sixteen weeks' observation, there were no definite differences compared to the eight weeks' finding in the control and experimental groups. The proteoglycan content was evaluated according to the staining intensity of alcian blue stain (pH 2.5), and there were not any differences in the staining intensity between the left and right femoral condyle by the serial observation. So, on the experimental side there were a significant delay and lessening of the arthritic response.

#### Scanning Electron Microscopic Findings

Scanning electron microscopic observations of the surface of articular cartilage were performed at eight and sixteen weeks after the operation. There were no definite differences in the surface mor-

phology of articular cartilage between the eight weeks' and sixteen weeks' findings. In the left femoral condyle at sixteen weeks after the operation, there were multiple deep clefts and disarrangement of connective tissue fibers on the surface of articular cartilage; but, in the right side only shallow clefts were noted, and the surface of articular cartilage showed regular arrangements which were closer to the normal articular cartilage (Fig. 6).

#### DISCUSSION

With the increase of human life span and the increasing number of traffic accidents, degenerative osteoarthritis becomes a significant clinical problem whether it is primary or secondary. There have been many medical or surgical interventions for treatment of osteoarthritis, but the final outcomes were not as promising regardless of the treatment methods used (Soto-Hall 1945; Magnuson 1946; Kelikian 1949; Knodt 1964; Riggins et al. 1975). The prevention of osteoarthritis is important, and many experimental and clinical studies to prevent the degenerative changes of the articular cartilage have been reported (Rydell and Balazs 1971; Behren et al. 1975).

There are several animal models which mimic in accelerated fashion post-traumatic degenerative arthritis (Hall 1963 ; Hulth *et al.* 1970; Eng *and* Chrisman 1977; Ogata *et al.* 1977). One of the most extreme is the Hulth technique(1970) in which sectioning of the medial collateral ligament and both cruciate ligaments and medial meniscectomy combined to produce rapid and severe arthritis of the knee joint in rabbits.

In 1966 Balazs *et al.* found a 1-2  $\mu$  thick layer adherent to the articular cartilage surface that may contain hyaluronic acid. The idea that this layer contains hyaluronic acid was confirmed by enzymatic, electron microscope and chemical studies (Balazs 1968). Hyaluronic acid may be an important component of the cartilage surface. In normal joints the hyaluronic acid layer forms an elastic cushion between the joint surfaces, protects the cartilage from wearing and behaves as a shock absorber. Under dynamic conditions, hyaluronic acid solutions have a significant viscoelastic behavior (Rydell and Balazs 1971).

In 1972 Balazs *et al.* purified hyaluronic acid from the human umbilical cord and rooster combs and obtained it with a high molecular weight(100–300 $\times 10^4$ ), high viscosity, and a protein content of less than 1 per cent. It has also been reported that injection of hyaluronic acid into the knee joints of race horses with traumatic arthritis or osteoarthritis is beneficial(Rydell and Balazs 1971).

In the early stage of osteoarthritis, the articular cartilage becomes hypercellular and the rate of proteoglycan synthesis is increased (Mankin and Lippiello 1970 ; Mankin *et al.* 1971). On the other hand, hyaluronic acid is known to inhibit the biosynthesis of cartilage cells and proteoglycans (Toole *et al.* 1972 ; Toole 1973). The administration of hyaluronic acid may inhibit this hypercellularity and proteoglycan synthesis, thereby arresting the progression of osteoarthritis. This concept may explain why in this study, the intra-articular injection of hyaluronic acid proved effective in preventing destruction of articular cartilage.

Its rheologic properties include extremely high viscosity at low shear rates and low viscosity at increasing shear rates. The elasticity is very low when the material is exposed to low frequency stress and increases rapidly as the frequency increases, thus providing excellent shock absorption and protection against mechanical impact. These devices provide the same rheologic properties as normal human synovial fluid but at a much higher level ; in the form of gels, they show plasticity. This consideration

may provide a second possible mechanism for the prevention of osteoarthritis in this study.

The third possible explanation is that the injected Na-hyaluronate provides lubrication lines on the surface of articular cartilage, thereby preventing damage of the amorphous layer of the articular cartilage observed by Walker *et al.* (1969).

The amorphous material layer may act as a barrier to the invasion of various chondrotoxic enzymes and catabolites into the articular cartilage. And it may also block the efflux from the cartilage matrix of proteins and their metabolites into the joint cavity, thus preventing cartilage degeneration. But, we could not confirm either the lubrication line or amorphous layer of the articular cartilage in scanning electron microscope, because we had examined the surface of articular cartilage at eight or sixteen weeks after operation. The only observation confirmed by the scanning electron microscope was the differences in patterns of clefts and in the congruity of the articular cartilage in the low power field.

Namiki *et al.* (1982) observed the increase in density of mucin clot formation after the intra-articular injection of hyaluronic acid, suggesting that the exogenous hyaluronic acid stimulated fluid production by the synovial tissue and that this synovial fluid interacted with protein to attain normal synovial fluid properties. There have been several hypotheses about the mechanism of joint lubrication. It has been suggested that among the three kinds of lubrication, i. e. , synovial membrane-on-synovial membrane, synovial membrane-on-cartilage, and cartilage-on-cartilage, hyaluronic acid plays an important role in the first two kinds of mechanism(Radin *et al.* 1971 ; Swann *et al.* 1974). The early effects of prevention of osteoarthritis noted after the intra-articular injection of Na-hyaluronate may be ascribed to this enhanced lubrication mechanism, but the authors thought that the later effects observed in this study were due to the mechanical barrier of the load caused by weight bearing.

The proteoglycan content was evaluated by the staining intensity of alcian blue. Because proteoglycan molecules have an affinity for alcian blue, a decrease in proteoglycan content is noted by a decrease in staining intensity. We did not observe any differences in staining intensity between the two groups, suggesting that there were no significant changes in the content of proteoglycan.

In this study using a severe arthritis model with instability, there was a significant delay in the onset

of arthritic changes when the rabbit knee joint was injected with the Na-hyaluronate gel. Because of its biocompatibility, ease of application, and high protective effect on the articular cartilage, the authors thought that Na-hyaluronate gel would be a valuable adjuvant in the early treatments of primary osteoarthritis and of post-traumatic joints.

## REFERENCES

- Balazs EA : Viscoelastic properties of hyaluronic acid and biological lubrication. *Univ Mich Med Cent J* Dec : 255, 1968
- Balazs EA, Bloom GD, Swann DA : Fine structure and glycosaminoglycan content of the surface layer of articular cartilage. *Fed Proc* 25: 1813, 1966
- Balazs EA, Freeman MI, Klöti R, Meyer-Schwickerath G, Reganault F, Sweeny DB : Hyaluronic acid and replacement of vitreous and aqueous humor. *Mod Probl Ophthalmol* 10 : 3, 1972
- Behrens F, Shepard N, Mitchell N : Alteration of rabbit articular cartilage by intraarticular injection of glucocorticoid. *J Bone J Surg* 57A : 70, 1975
- Engh GA, Chrisman OD : Experimental arthritis in rabbit knee. *Clin Orthop* 125 : 221, 1977
- Hall MC : Cartilage change after experimental immobilization of the knee joint of the young rat. *J Bone J Surg* 45A : 36, 1963
- Hulth A, Lindberg L, Telhag H : Experimental osteoarthritis in rabbits. *Acta Orthop Scandinav* 41 : 522, 1970
- Kelikian H : Surgery in the treatment of chronic arthritis. *Surg Clin North Am* 29 : 87, 1949
- Knödt H : Osteoarthritis of the hip joint; Etiology and treatment by osteotomy. *J Bone J Surg* 46A : 1326, 1964
- Magnuson PB : Technique of debridement of the knee joint for arthritis. *Surg Clin North Am* 26 : 249, 1946
- Mankin HJ, Lippiello L : Biochemical and metabolic abnormalities in articular cartilage from osteo-arthritic human hips. *J Bone J Surg* 52A : 424, 1970
- Mankin HJ, Dorfman H, Lippiello L, Zarins A : Biochemical and metabolic abnormalities in articular cartilage from osteo-arthritic human hips. II. Correlation of morphology with biochemical and metabolic data. *J Bone J Surg* 53A : 523, 1971
- Moskowitz RW : Experimental models of degenerative joint disease. *Arth Rheum* 2 : 95, 1972
- Namiki O, Toyoshima H, Morisaki N : Therapeutic effect of intra-articular injection of high molecular weight hyaluronic acid on osteoarthritis of the knee. *Int J Clin Phar Thera Toxi* 20 : 501, 1982
- Ogata K, Whiteside LA, Lesker PA, Simmons DJ : The effect of varus stress on the moving rabbit knee joint. *Clin Orthop* 129 : 313, 1977
- Radin EL, Paul IL, Swann DA, Schottstadt ES : Lubrication of synovial membrane. *Ann Rheum Dis* 30 : 322, 1971
- Riggins RS, Kraus JF, Lipscomb PR : Osteoarthritis of the hip; A survey of treatment. *Clin Orthop* 106 : 56, 1975
- Rydell N, Balazs E : Effect of intra-articular injection of hyaluronic acid on the clinical symptoms of osteoarthritis and on granulation tissue formation. *Clin Orthop* 80 : 25, 1971
- Soto-Hall R : Traumatic degeneration of the articular cartilage of the patella. *J Bone J Surg* 27 : 426, 1945
- Swann DA, Radin EL, Nazimiec M, Weisser PA, Curran N, Lewinnek G : Role of hyaluronic acid in joint lubrication. *Ann Rheum Dis* 33 : 318, 1974
- Toole BP : Hyaluronate inhibition of chondrogenesis; Antagonism of thyroxine, growth hormone, and calcitonin. *Sci* 180 : 302, 1973
- Toole BP, Jackson G, Gross J : Hyaluronate in morphogenesis in vitro. *Proc Natl Acad Sci* 69 : 1384, 1972
- Walker PS, Sikorski J, Doeson D, Longfield MD, Wright V, Buckely T : Behavior of synovial fluid on surface of articular cartilage. A scanning electron microscope study. *Ann Rheum Dis* 28 : 1, 1969